



National Comprehensive
Cancer Network®

NCCN Clinical Practice Guidelines in Oncology (NCCN Guidelines®)

Vulvar Cancer

(Squamous Cell Carcinoma)

Version 3.2021 — April 26, 2021

NCCN.org

Continue



National
Comprehensive
Cancer
Network®

NCCN Guidelines Version 3.2021

Vulvar Cancer (Squamous Cell Carcinoma)

[NCCN Guidelines Index](#)
[Table of Contents](#)
[Discussion](#)

***Nadeem R. Abu-Rustum, MD Ω/Chair**
Memorial Sloan Kettering Cancer Center

***Catheryn M. Yashar, MD §/Vice Chair**
UC San Diego Moores Cancer Center

Kristin Bradley, MD §
University of Wisconsin
Carbone Cancer Center

Susana M. Campos, MD, MPH, MS †
Dana-Farber/Brigham and Women's
Cancer Center

Hye Sook Chon, MD Ω
Moffitt Cancer Center

Christina Chu, MD Ω
Fox Chase Cancer Center

Lani Clinton, MD, PhD ≠
Duke Cancer Institute

David Cohn, MD Ω
The Ohio State University
Comprehensive Cancer Center -
James Cancer Hospital and
Solove Research Institute

Marta Ann Crispens, MD Ω
Vanderbilt-Ingram Cancer Center

Shari Damast, MD §
Yale Cancer Center/
Smilow Cancer Hospital

Elisabeth Diver, MD Ω
Stanford Cancer Institute

Christine M. Fisher, MD, MPH §
University of Colorado Cancer Center

Peter Frederick, MD Ω
Roswell Park Cancer Institute

David K. Gaffney, MD, PhD §
Huntsman Cancer Institute
at the University of Utah

Robert Giuntoli II, MD Ω
Abramson Cancer Center at
the University of Pennsylvania

Ernest Han, MD, PhD Ω
City of Hope
National Medical Center

Warner K. Huh, MD Ω
O'Neal Comprehensive
Cancer Center at UAB

Jayanthi Lea, MD Ω
UT Southwestern Simmons
Comprehensive Cancer Center

Andrea Mariani, MD Ω
Mayo Clinic Cancer Center

David Mutch, MD Ω
Siteman Cancer Center at Barnes-
Jewish Hospital and Washington
University School of Medicine

Larissa Nekhlyudov, MD, MPH ‡
Dana-Farber/Brigham and Women's
Cancer Center

Steven W. Remmenga, MD Ω
Fred & Pamela Buffett Cancer Center

R. Kevin Reynolds, MD Ω
University of Michigan
Rogel Cancer Center

Ritu Salani, MD, MBA Ω
UCLA Jonsson Comprehensive Cancer Center

Rachel Sisodia, MD Ω
Massachusetts General Hospital
Cancer Center

Pamela Soliman, MD, MPH Ω
The University of Texas MD Anderson Cancer Center

Edward Tanner, MD Ω
Robert H. Lurie Comprehensive Cancer Center of
Northwestern University

Todd Tillmanns, MD Ω
St. Jude Children's Research Hospital/
The University of Tennessee Health Science Center

Stefanie Ueda, MD Ω
UCSF Helen Diller Family
Comprehensive Cancer Center

Renata Urban, MD Ω
Fred Hutchinson Cancer Research Center/
Seattle Cancer Care Alliance

Emily Wyse ¥
Patient Advocate

NCCN
Nicole McMillian, MS
Angela Motter, PhD

Ω Gynecologic oncology
‡ Internal medicine
† Medical oncology
≠ Pathology
¥ Patient advocacy
§ Radiotherapy/Radiation oncology
* Discussion Section Writing Committee

Continue

[NCCN Guidelines Panel Disclosures](#)



National
Comprehensive
Cancer
Network®

NCCN Guidelines Version 3.2021

Vulvar Cancer (Squamous Cell Carcinoma)

[NCCN Guidelines Index](#)
[Table of Contents](#)
[Discussion](#)

[NCCN Vulvar Cancer Panel Members](#) [Summary of the Guidelines Updates](#)

[Workup \(VULVA-1\)](#)

[Early Stage: T1, Smaller T2 \(VULVA-2\)](#)

[Adjuvant Therapy Based On Primary Tumor Risk Factors \(VULVA-3\)](#)

[Adjuvant Therapy Based On Nodal Status \(VULVA-4\)](#)

[Locally Advanced: Larger T2, T3 \(VULVA-5\)](#)

[Additional Treatment \(VULVA-6\)](#)

[Metastatic Disease Beyond Pelvis: Any T, Any N, M1 \(VULVA-7\)](#)

[Surveillance \(VULVA-8\)](#)

[Therapy for Recurrence Clinically Limited to the Vulva \(VULVA-9\)](#)

[Therapy for Clinical Nodal or Distant Recurrence \(VULVA-10\)](#)

[Principles of Pathology \(VULVA-A\)](#)

[Principles of Imaging \(VULVA-B\)](#)

[Principles of Surgery \(VULVA-C\)](#)

[Principles of Radiation Therapy \(VULVA-D\)](#)

[Systemic Therapy \(VULVA-E\)](#)

[Principles of Gynecologic Survivorship \(VULVA-F\)](#)

[Staging \(ST-1\)](#)

For vulvar melanoma see the [NCCN Guidelines for Cutaneous Melanoma](#)

Clinical Trials: NCCN believes that the best management for any patient with cancer is in a clinical trial. Participation in clinical trials is especially encouraged.

To find clinical trials online at NCCN Member Institutions, [click here: nccn.org/clinical_trials/member_institutions.aspx](#).

NCCN Categories of Evidence and Consensus: All recommendations are category 2A unless otherwise indicated.

See [NCCN Categories of Evidence and Consensus](#).

NCCN Categories of Preference: All recommendations are considered appropriate.

See [NCCN Categories of Preference](#).

The NCCN Guidelines® are a statement of evidence and consensus of the authors regarding their views of currently accepted approaches to treatment. Any clinician seeking to apply or consult the NCCN Guidelines is expected to use independent medical judgment in the context of individual clinical circumstances to determine any patient's care or treatment. The National Comprehensive Cancer Network® (NCCN®) makes no representations or warranties of any kind regarding their content, use or application and disclaims any responsibility for their application or use in any way. The NCCN Guidelines are copyrighted by National Comprehensive Cancer Network®. All rights reserved. The NCCN Guidelines and the illustrations herein may not be reproduced in any form without the express written permission of NCCN. ©2021.



NCCN Guidelines Version 3.2021

Vulvar Cancer (Squamous Cell Carcinoma)

Updates in Version 3.2021 of the NCCN Guidelines for Vulvar Cancer from Version 2.2021 include:

MS-1

- The Discussion has been updated to reflect the changes in the algorithm.

Updates in Version 2.2021 of the NCCN Guidelines for Vulvar Cancer from Version 1.2021 include:

VULVA-E Systemic Therapy

- Correction: Footnote "e" regarding nivolumab for second-line therapy changed from "For mismatch repair-deficient (dMMR) advanced or recurrent/metastatic vulvar cancer." to "For *HPV-related* advanced or recurrent/metastatic vulvar cancer."

Updates in Version 1.2021 of the NCCN Guidelines for Vulvar Cancer from Version 3.2020 include:

General

- Principles of Gynecologic Survivorship: This is a new section that discusses the physical and psychosocial effects of gynecologic cancers as well as clinical approaches to managing them. ([VULVA-F](#))

VULVA-1

- Workup; Eighth bullet revised: Consider *cervical HPV and cytology* testing.

VULVA-2

- Primary Treatment for T1a (≤1 mm invasion): Revised, *Simple* partial
- ~~superficial~~ vulvectomy.

VULVA-5

- Clinical Stage: New pathway added for *Unresectable nodes regardless of T stage*.

VULVA-A Principles of Pathology

- General Principles; First bullet revised: "... HPV-associated SCC frequently occurs in younger women, is frequently multifocal, is associated with classic VIN, *and* can be seen in association with additional sites of lower genital tract squamous neoplasia. ~~and is p16 positive and p53 negative by immunohistochemistry (IHC).~~ *Immunohistochemistry (IHC) shows strong, diffuse, block-like positive nuclear and cytoplasmic staining with p16 and wild-type p53 (heterogeneous staining pattern).* Non-HPV-associated SCC usually occurs in older women, is unifocal, and is associated with differentiated vulvar intraepithelial neoplasia (dVIN), ~~may be p53 positive, and is usually p16 negative or focally positive by IHC.~~ *IHC shows aberrant p53 staining (widespread, strong nuclear expression or complete absence/null expression) and patchy (negative) p16 staining. A meta-analysis...*"

VULVA-B Principles of Imaging

- Whole body PET/CT changed to *Neck/chest/abdomen/pelvis/groin* PET/CT.

VULVA-D Principles of Radiation Therapy

2 of 5

- New reference added: *Rishi A, Rollins M, Ahmed KA, et al. High-dose intensity-modulated chemoradiotherapy in vulvar squamous cell carcinoma: Outcome and toxicity. Gynecol Oncol 2020;156(2):349-356.*



NCCN Guidelines Version 3.2021

Vulvar Cancer (Squamous Cell Carcinoma)

VULVA-E Systemic Therapy

- **General:** The tables for Chemoradiation and Advanced or Recurrent/Metastatic Disease were reformatted.
- **Chemoradiation; Other Recommended Regimens:** Cisplatin/fluorouracil moved above Fluorouracil/mitomycin C on the list.
- **Chemotherapy for Advanced, Recurrent/Metastatic Disease**
 - ▶ A new section was added for *Biomarker-directed systemic therapy for second-line treatment*.
 - ▶ Biomarker-directed systemic therapy for second-line treatment.
 - ◊ Revised: Pembrolizumab (second-line therapy for *TMB-H*, PD-L1–positive, or MSI-high [MSI-H]/MMR deficient [dMMR] ~~or TMB-H~~ tumors)
 - ◊ *Nivolumab* was added as an option with corresponding footnote "e" *For mismatch repair-deficient (dMMR) advanced or recurrent/metastatic vulvar cancer*.
 - ◊ New references added:
 - Marabelle A, et al. Association of tumour mutational burden with outcomes in patients with advanced solid tumours treated with pembrolizumab: prospective biomarker analysis of the multicohort, open-label, phase 2 KEYNOTE-158 study. *Lancet Oncol*. 2020;21(10):1353-1365.
 - Marabelle A, Le DT, Ascierto PA, et al. Efficacy of pembrolizumab in patients with noncolorectal high microsatellite instability/mismatch repair-deficient cancer: results from the phase 2 KEYNOTE-158 study. *J Clin Oncol* 2020;38:1-10.
 - Naumann RW, Hollebecque A, Meyer T, et al. Safety and Efficacy of Nivolumab Monotherapy in Recurrent or Metastatic Cervical, Vaginal, or Vulvar Carcinoma: Results From the Phase I/II CheckMate 358 Trial. *J Clin Oncol* 2019;37:2825-2834.



NCCN Guidelines Version 3.2021

Vulvar Cancer (Squamous Cell Carcinoma)

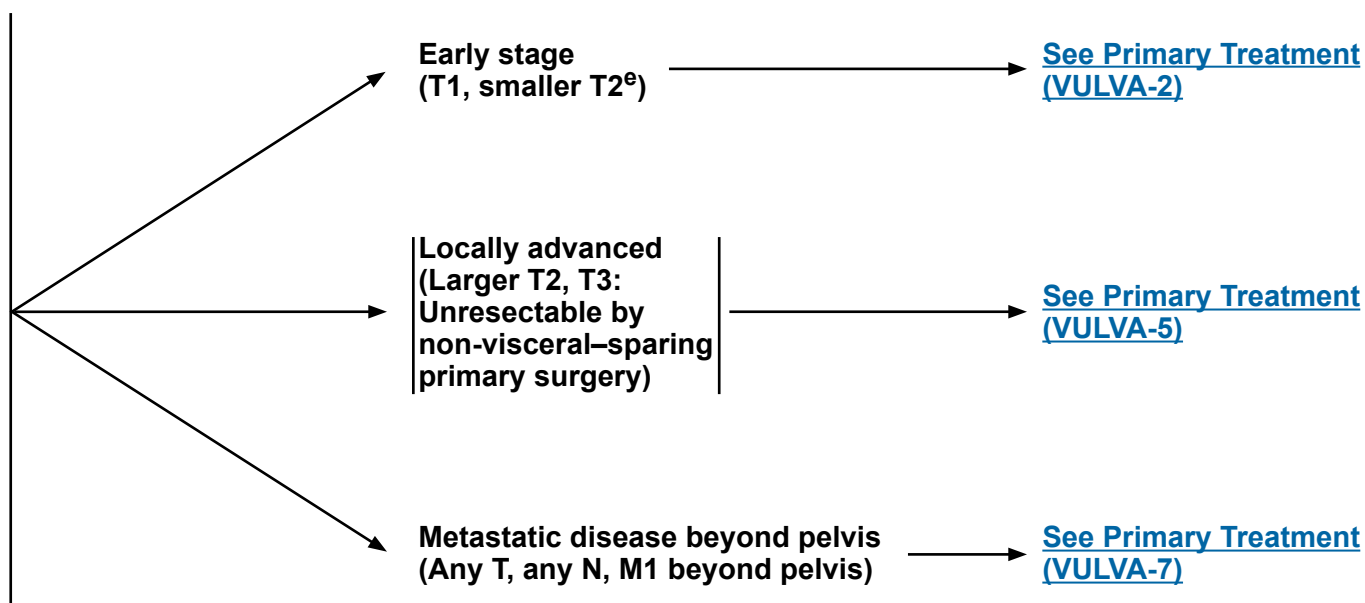
SQUAMOUS CELL CARCINOMA^a

WORKUP

- H&P
- CBC
- Biopsy, pathologic review^b
- LFT/renal function studies
- Imaging^c as needed for delineating extent of tumor or for treatment planning
- EUA cystoscopy or proctoscopy as indicated
- Smoking cessation and counseling intervention if indicated ([See NCCN Guidelines for Smoking Cessation](#))
- Consider cervical HPV and cytology testing
- Consider HIV testing^d
- For elderly patients with vulvar cancer, also see the [NCCN Guidelines for Older Adult Oncology](#)

CLINICAL STAGE^b

PRIMARY TREATMENT



^aHistologic high-grade squamous intraepithelial lesion (HSIL; formerly defined as carcinoma in situ [CIS] and incorporates vulvar intraepithelial neoplasia 2 and 3 [VIN2/3]) can be treated with wide local excision.

^b[See Principles of Pathology \(VULVA-A\).](#)

^c[See Principles of Imaging \(VULVA-B\).](#)

^dConsider HIV testing, especially in younger patients. Patients with vulvar cancer and HIV should be referred to an HIV specialist and should be treated for vulvar cancer as per these guidelines. Modifications to cancer treatment should not be made solely on the basis of HIV status.

^eSmaller T2 tumors: ≤4 cm.

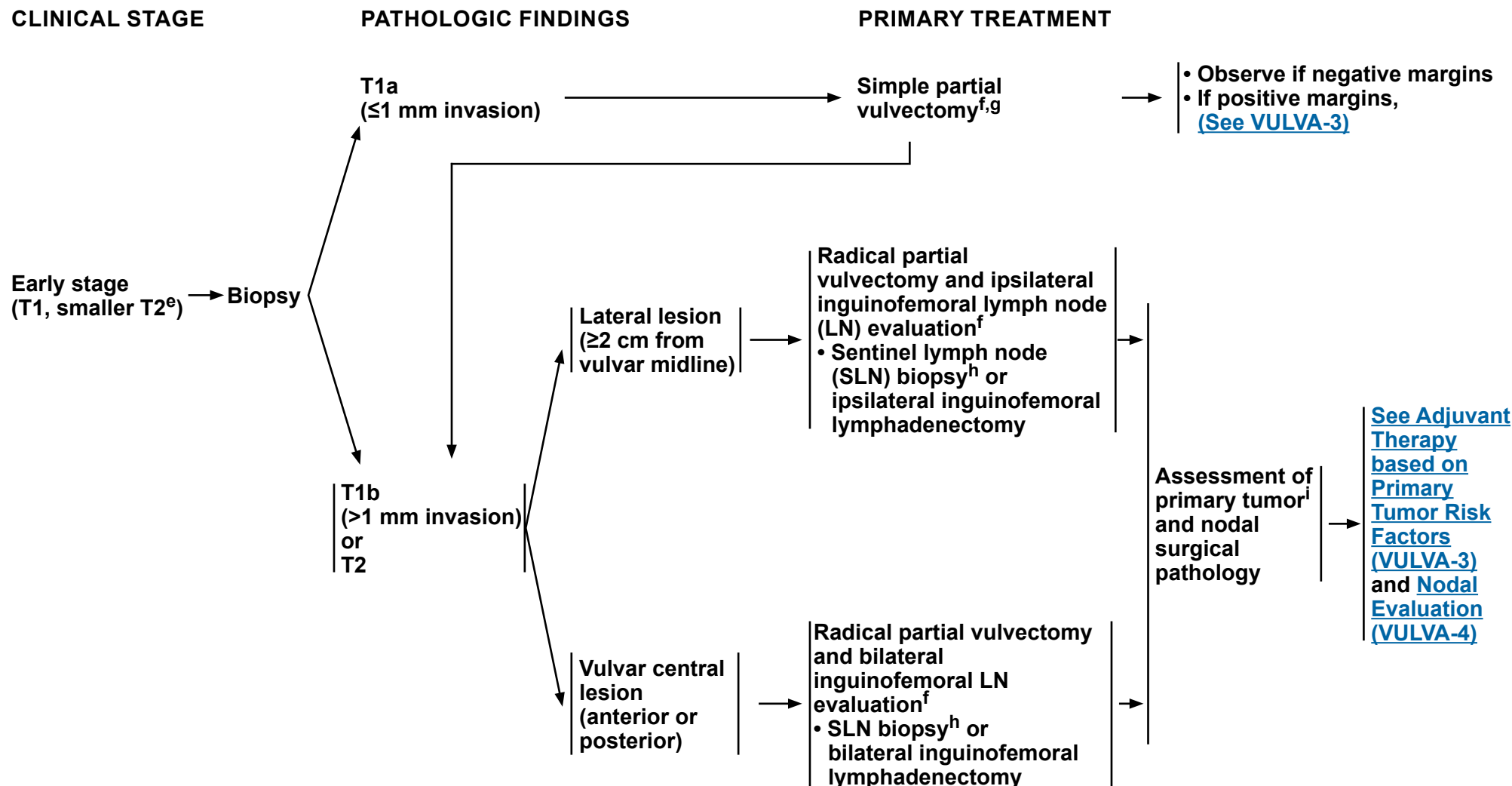
Note: All recommendations are category 2A unless otherwise indicated.

Clinical Trials: NCCN believes that the best management of any patient with cancer is in a clinical trial. Participation in clinical trials is especially encouraged.



NCCN Guidelines Version 3.2021

Vulvar Cancer (Squamous Cell Carcinoma)


^eSmaller T2 tumors: ≤4 cm.

^f[See Principles of Surgery \(VULVA-C\).](#)
^gIf partial superficial vulvectomy pathology reveals tumor in aggregate of ≥1 mm invasion, then additional surgery may be warranted.

^hInguinofemoral lymphadenectomy is required on side(s) where sentinel nodes are not detected.

ⁱ[See Principles of Surgery: Tumor Margin Status \(VULVA-C 1 of 5\).](#)
Note: All recommendations are category 2A unless otherwise indicated.

Clinical Trials: NCCN believes that the best management of any patient with cancer is in a clinical trial. Participation in clinical trials is especially encouraged.

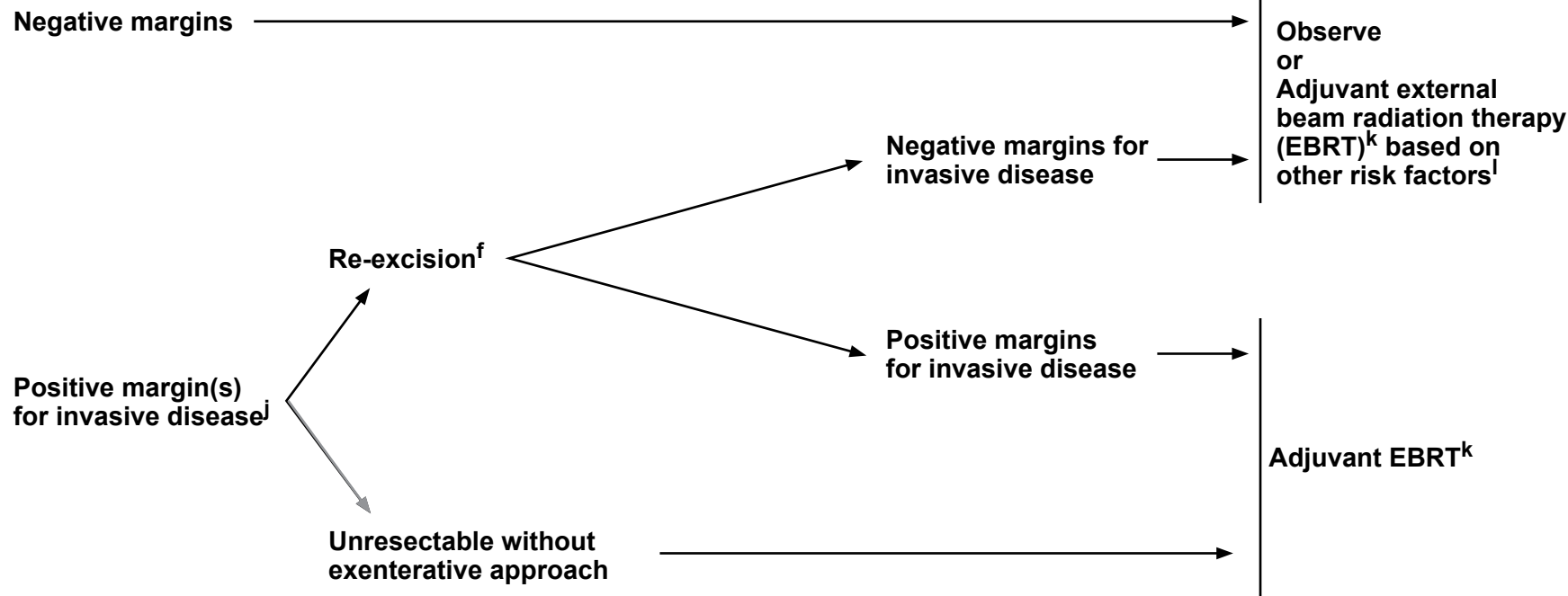


NCCN Guidelines Version 3.2021

Vulvar Cancer (Squamous Cell Carcinoma)

PRIMARY TUMOR RISK FACTORS

ADJUVANT THERAPY TO THE PRIMARY SITE



[See Surveillance \(VULVA-8\)](#)

^f[See Principles of Surgery \(VULVA-C\).](#)

^jThe management of positive margins for HSIL (noninvasive disease) should be individualized.

^k[See Principles of Radiation Therapy \(VULVA-D\).](#)

^lOther primary risk factors include: close tumor margins, lymphovascular invasion (LVSI), tumor size, depth of invasion, and pattern of invasion (spray or diffuse). Nodal involvement (as an indicator of lymphovascular space invasion) may also impact selection of adjuvant therapy to the primary site.

Note: All recommendations are category 2A unless otherwise indicated.

Clinical Trials: NCCN believes that the best management of any patient with cancer is in a clinical trial. Participation in clinical trials is especially encouraged.

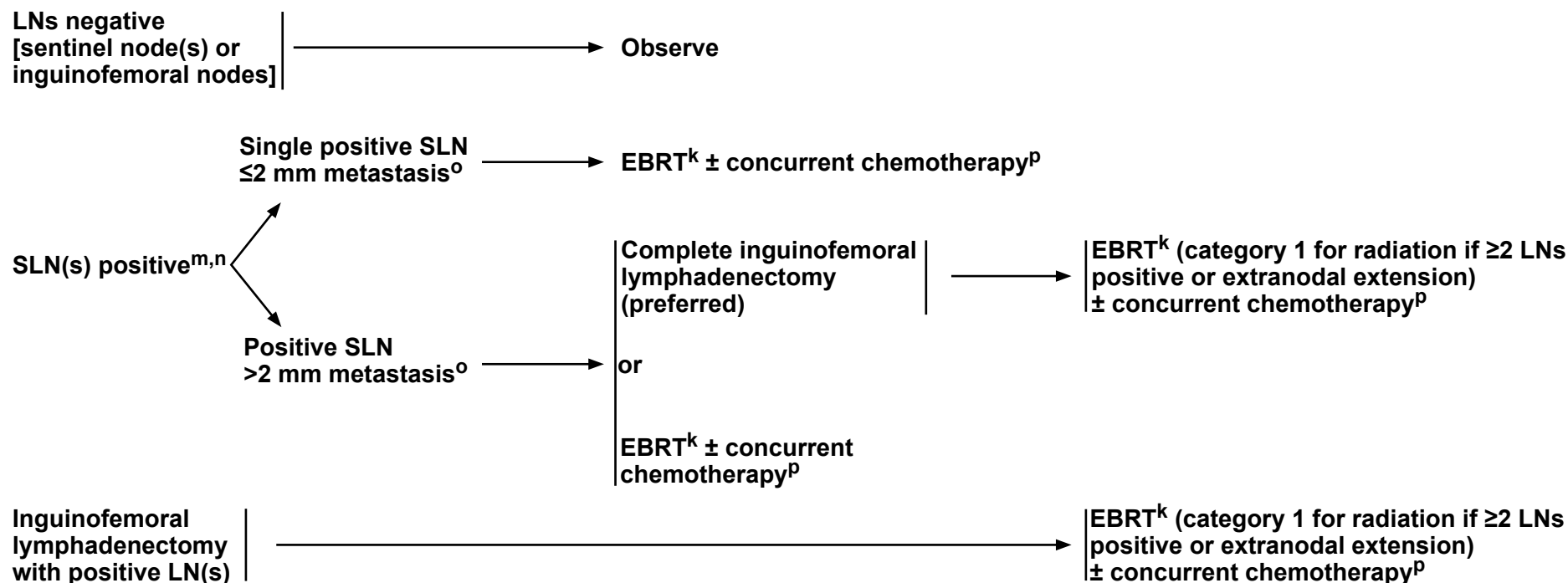


NCCN Guidelines Version 3.2021

Vulvar Cancer (Squamous Cell Carcinoma)

NODAL EVALUATION

ADJUVANT THERAPY TO THE NODES



^kSee [Principles of Radiation Therapy \(VULVA-D\)](#).

^mIf ipsilateral groin is positive, the contralateral groin should be evaluated surgically and/or treated with EBRT. In select cases of a single, small-volume, unilateral, positive inguinal node with a well-lateralized primary tumor diameter ≤2 cm and depth of invasion ≤5 mm and with a clinically negative contralateral groin examination, a contralateral inguinofemoral lymphadenectomy or radiation may be omitted. (Gonzalez Bosquet J, et al. Gynecol Oncol 2007;105:742-746.)

ⁿSee [Principles of Surgery: Inguinofemoral Sentinel Lymph Node Biopsy \(VULVA-C 4 of 5\)](#).

^oThe size of 2 mm is used to inform treatment selection/management and the 5-mm cutoff is used for staging. See [Principles of Pathology \(VULVA-A\)](#).

^pSee [Systemic Therapy \(VULVA-E\)](#).

[See Surveillance \(VULVA-8\)](#)

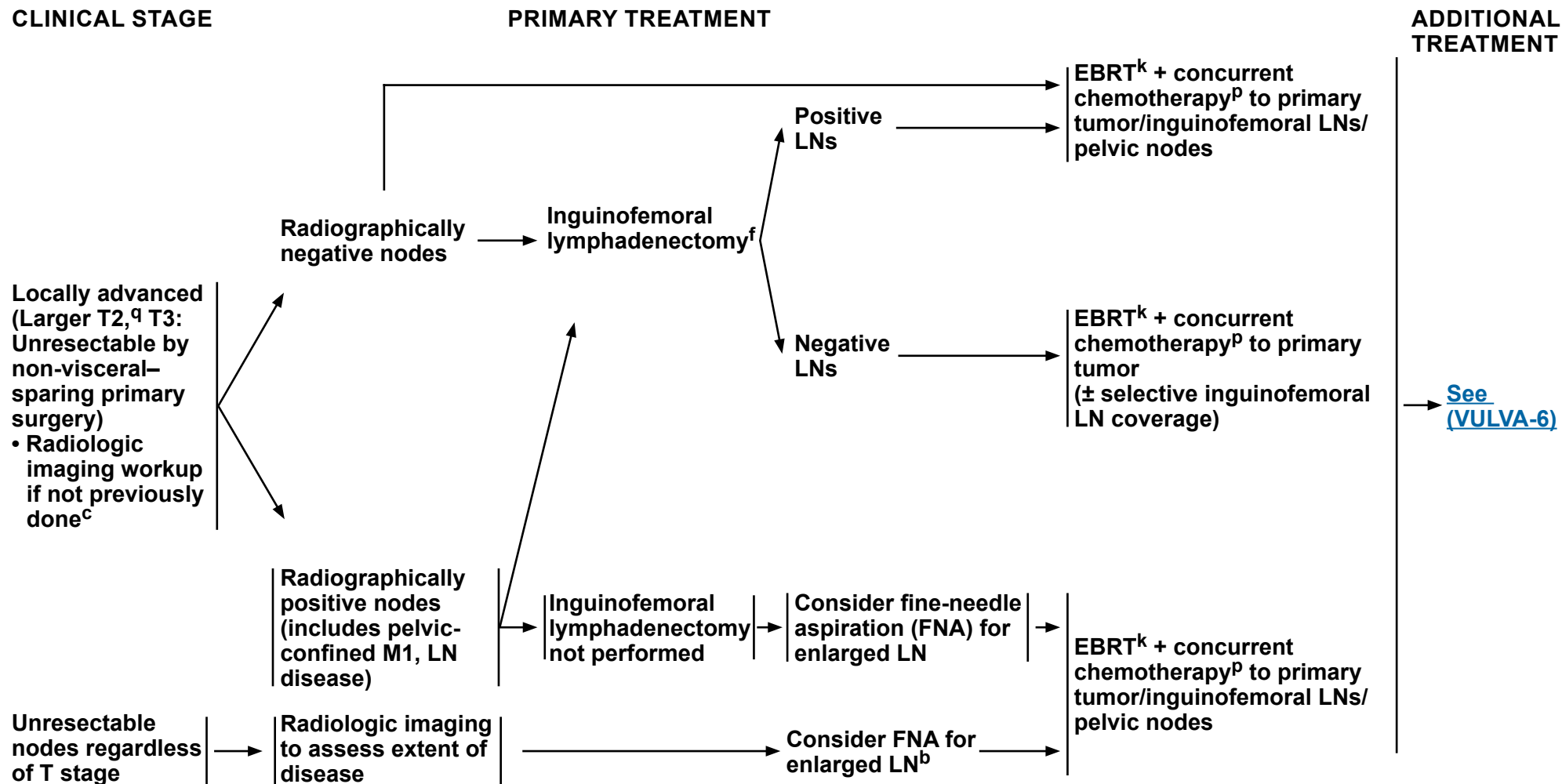
Note: All recommendations are category 2A unless otherwise indicated.

Clinical Trials: NCCN believes that the best management of any patient with cancer is in a clinical trial. Participation in clinical trials is especially encouraged.



NCCN Guidelines Version 3.2021

Vulvar Cancer (Squamous Cell Carcinoma)

^bSee Principles of Pathology (VULVA-A).^cSee Principles of Imaging (VULVA-B).^fSee Principles of Surgery (VULVA-C).^kSee Principles of Radiation Therapy (VULVA-D).^pSee Systemic Therapy (VULVA-E).^qLarger T2 tumors: >4 cm and/or involvement of the urethra, vagina, or anus.

Note: All recommendations are category 2A unless otherwise indicated.

Clinical Trials: NCCN believes that the best management of any patient with cancer is in a clinical trial. Participation in clinical trials is especially encouraged.

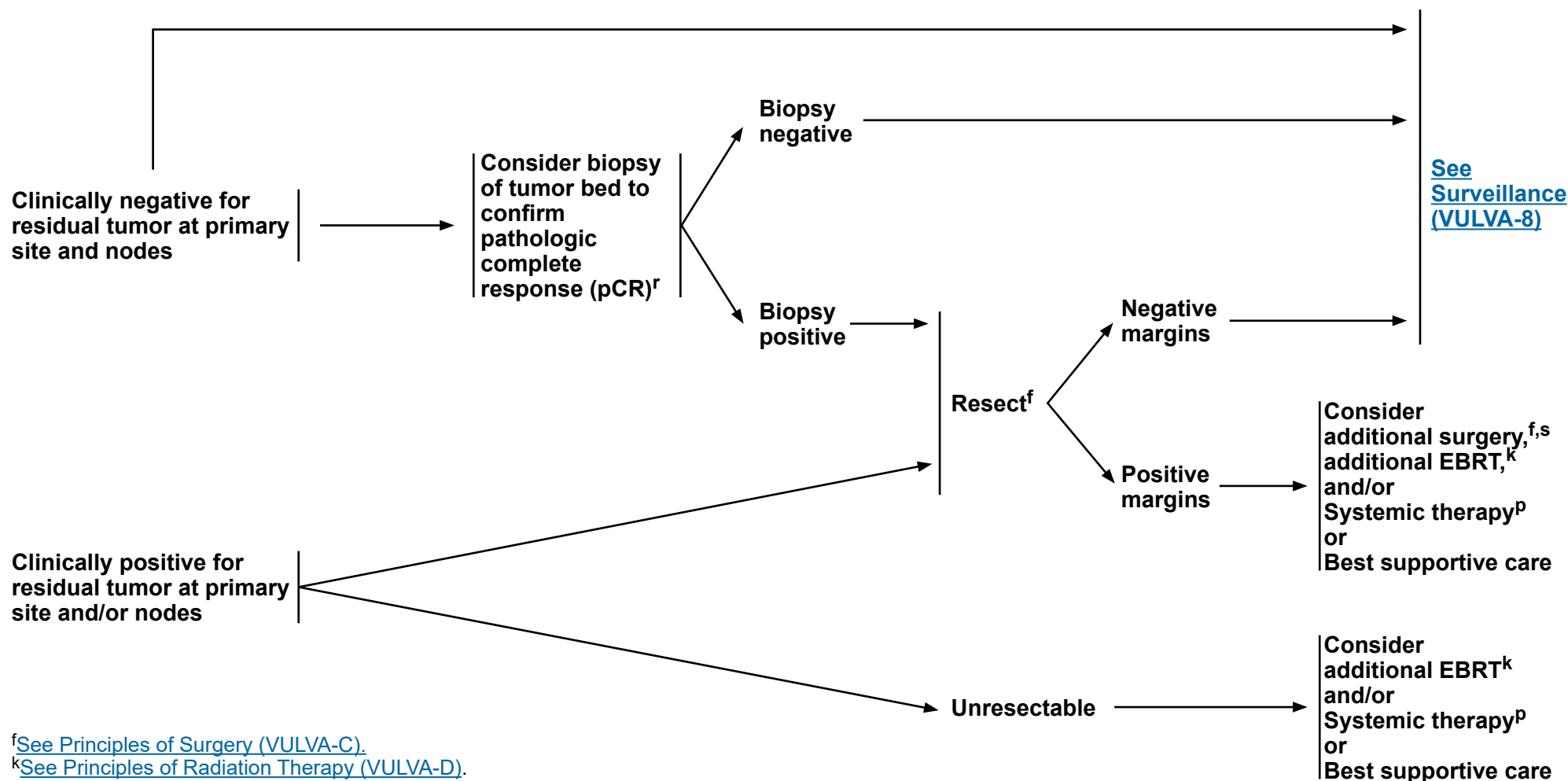


NCCN Guidelines Version 3.2021

Vulvar Cancer (Squamous Cell Carcinoma)

EVALUATION OF RESPONSE TO EBRT + CONCURRENT CHEMOTHERAPY

ADDITIONAL TREATMENT



^fSee Principles of Surgery (VULVA-C).

^kSee Principles of Radiation Therapy (VULVA-D).

^pSee Systemic Therapy (VULVA-E).

^rNo sooner than 3 months from completion of treatment.

^sConsider pelvic exenteration for select cases with a central recurrence.

Note: All recommendations are category 2A unless otherwise indicated.

Clinical Trials: NCCN believes that the best management of any patient with cancer is in a clinical trial. Participation in clinical trials is especially encouraged.



NCCN Guidelines Version 3.2021

Vulvar Cancer (Squamous Cell Carcinoma)

CLINICAL STAGE

PRIMARY TREATMENT

**Metastatic disease
beyond pelvis
(any T, any N, M1
beyond pelvis)**



**EBRT^{k,t} for locoregional control/symptom palliation
and/or
Systemic therapy^p
or
Best supportive care ([See NCCN Guidelines for Palliative Care](#))**

^k[See Principles of Radiation Therapy \(VULVA-D\).](#)

^p[See Systemic Therapy \(VULVA-E\).](#)

^tCan consider ablative therapy for 1–5 metastatic lesions if the primary has been controlled. (Palma DA, et al. Lancet 2019;393:2051-2058.)

Note: All recommendations are category 2A unless otherwise indicated.

Clinical Trials: NCCN believes that the best management of any patient with cancer is in a clinical trial. Participation in clinical trials is especially encouraged.



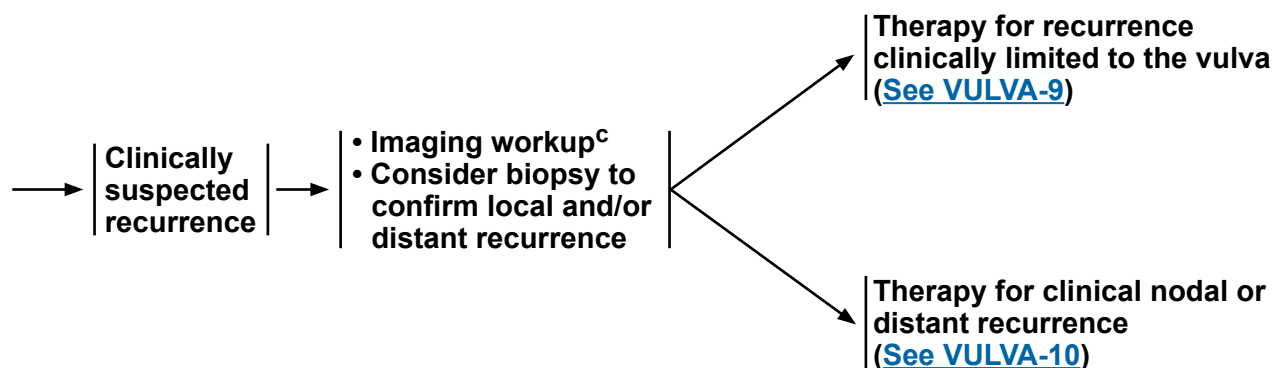
NCCN Guidelines Version 3.2021

Vulvar Cancer (Squamous Cell Carcinoma)

SURVEILLANCE

- Interval H&P every 3–6 mo for 2 y, every 6–12 mo for 3–5 y, then annually based on patient's risk of disease recurrence
- Cervical/vaginal cytology screening^u as indicated for the detection of lower genital tract neoplasia (may include HPV testing)
- Imaging as indicated based on symptoms or examination findings suspicious for recurrence^c
- Laboratory assessment (CBC, blood urea nitrogen [BUN], creatinine) as indicated based on symptoms or examination findings suspicious for recurrence
- Patient education regarding symptoms of potential recurrence and vulvar dystrophy, periodic self-examinations, lifestyle, obesity, exercise, sexual health (including vaginal dilator use and lubricants/moisturizers), smoking cessation, nutrition counseling, and potential long-term and late effects of treatment^v (Also [See NCCN Guidelines for Survivorship](#) and [NCCN Guidelines for Smoking Cessation](#))

WORKUP



^c[See Principles of Imaging \(VULVA-B\).](#)

^uRegular cytology can be considered for detection of lower genital tract dysplasia, although its value in detection of recurrent genital tract cancer is limited.

^v[See Principles of Gynecologic Survivorship \(VULVA-F\).](#)

Note: All recommendations are category 2A unless otherwise indicated.

Clinical Trials: NCCN believes that the best management of any patient with cancer is in a clinical trial. Participation in clinical trials is especially encouraged.

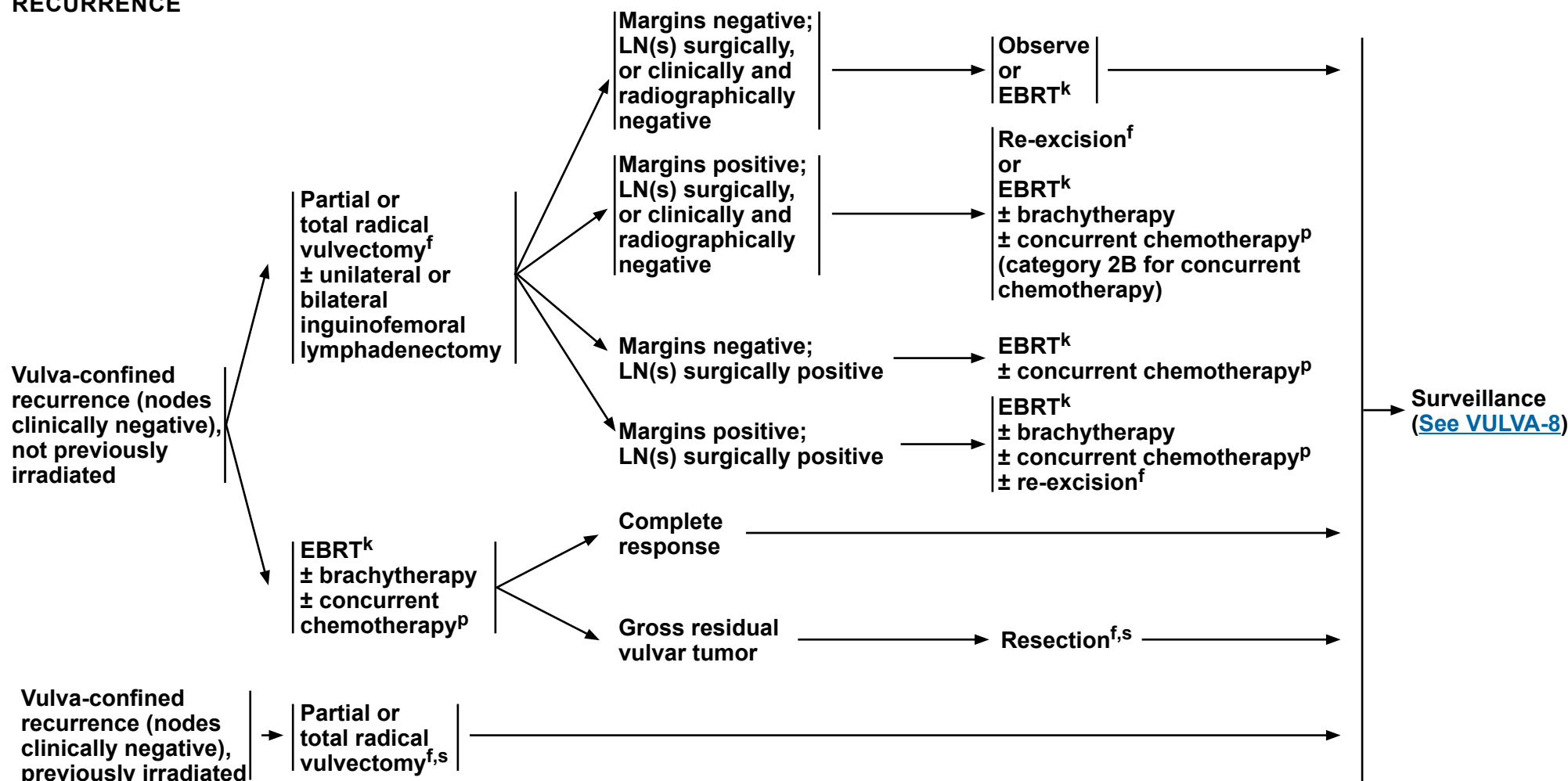


NCCN Guidelines Version 3.2021

Vulvar Cancer (Squamous Cell Carcinoma)

SITE OF RECURRENCE

THERAPY FOR RECURRENCE


^fSee Principles of Surgery (VULVA-C).

^kSee Principles of Radiation Therapy (VULVA-D).

^pSee Systemic Therapy (VULVA-E).

^sConsider pelvic exenteration for select cases with a central recurrence.

Note: All recommendations are category 2A unless otherwise indicated.

Clinical Trials: NCCN believes that the best management of any patient with cancer is in a clinical trial. Participation in clinical trials is especially encouraged.

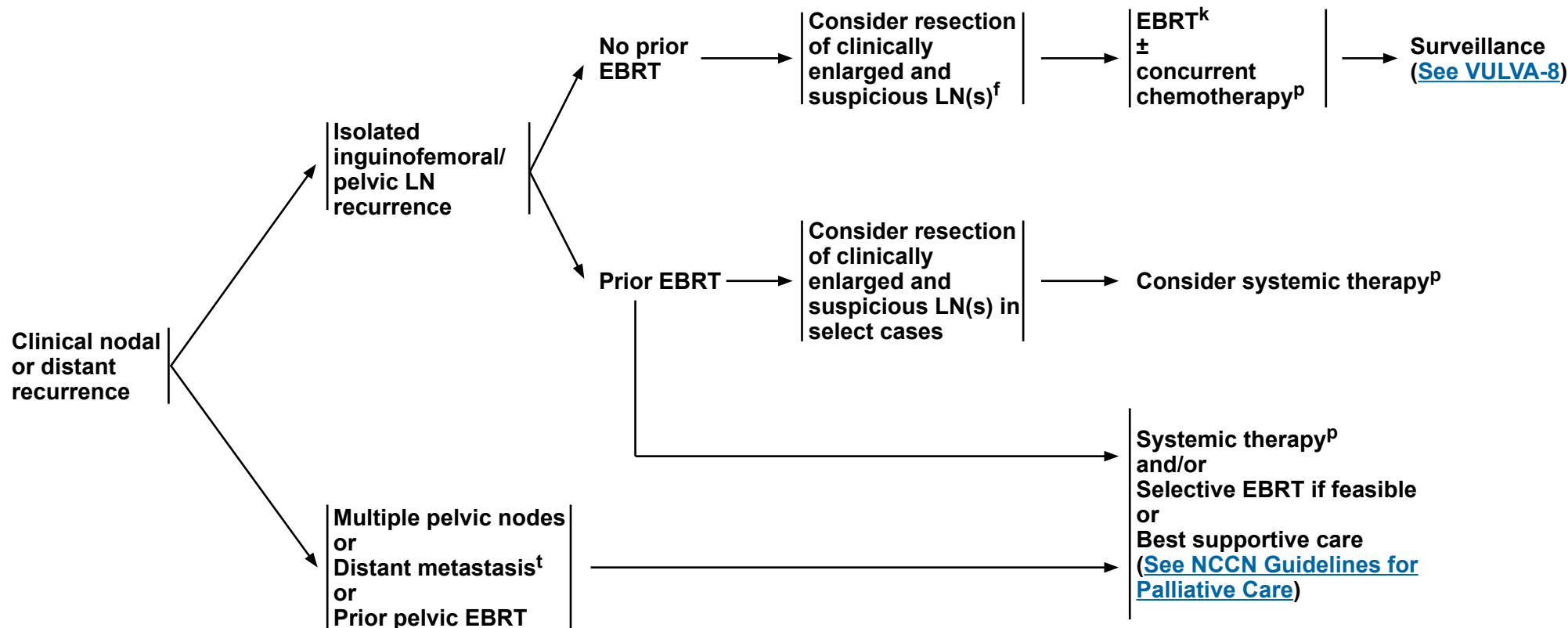


NCCN Guidelines Version 3.2021

Vulvar Cancer (Squamous Cell Carcinoma)

SITE OF RECURRENCE

THERAPY FOR RECURRENCE



^fSee Principles of Surgery (VULVA-C).

^kSee Principles of Radiation Therapy (VULVA-D).

^pSee Systemic Therapy (VULVA-E).

^tCan consider ablative therapy for 1–5 metastatic lesions if the primary has been controlled. (Palma DA, et al. Lancet 2019;393:2051-2058.)

Note: All recommendations are category 2A unless otherwise indicated.

Clinical Trials: NCCN believes that the best management of any patient with cancer is in a clinical trial. Participation in clinical trials is especially encouraged.



NCCN Guidelines Version 3.2021

Vulvar Cancer (Squamous Cell Carcinoma)

PRINCIPLES OF PATHOLOGY¹⁻⁴

Procedure: Vulvectomy

General Principles

- Histologic grading of squamous cell carcinoma (SCC) is not well-defined and can be subjective. Two pathways of vulvar intraepithelial neoplasia (VIN) and SCC have been identified in the vulva: HPV-associated and non-HPV-associated. Non-HPV-associated VIN and SCC are identified in the setting of chronic vulvar inflammatory disorders such as lichen sclerosus. HPV-associated SCC frequently occurs in younger women, is frequently multifocal, is associated with classic VIN, and can be seen in association with additional sites of lower genital tract squamous neoplasia. Immunohistochemistry (IHC) shows strong, diffuse, block-like positive nuclear and cytoplasmic staining with p16 and wild-type p53 (heterogeneous staining pattern). Non-HPV-associated SCC usually occurs in older women, is unifocal, and is associated with differentiated vulvar intraepithelial neoplasia (dVIN). IHC shows aberrant p53 staining (widespread, strong nuclear expression or complete absence/null expression) and patchy (negative) p16 staining. A meta-analysis showed that HPV-associated SCC had a better prognosis than non-HPV-associated SCC. Correlation of clinicopathologic findings can aid in identifying the tumor pathway and may provide prognostic information.
- Pathologists often have a challenging time assessing the presence and depth of invasion in vulvar SCC. Depth of invasion is measured in millimeters from the epithelial-stromal junction of the adjacent, most superficial dermal papilla to the deepest point of invasion⁵ ([See Figure 1](#)). Alternative ways to measure the depth of invasion have recently been proposed.⁶

Pathologic Assessment for Squamous Cell Carcinoma

- Vulva
 - ▶ Procedure type (total or partial vulvectomy)
 - ▶ Depth of surgical procedure (superficial or skinning, simple, or radical)
 - ▶ Tumor site
 - ▶ Tumor size, include greatest dimension and additional two dimensions
 - ▶ Number of tumor foci
 - ▶ Histologic type
 - ▶ Histologic grade
 - ▶ Depth of invasion (in mm)
 - ▶ Surgical resection margin status
 - ▶ Lymphovascular space invasion
- Other tissue/organ involvement (eg, vagina, urethra, anus, bladder mucosa, rectal mucosa, pelvic bone)
- LNs (when resected)^a
 - ▶ SLNs should undergo ultrastaging for detection of low-volume metastasis^b
 - ▶ Number of LNs with:^c
 - ◊ Metastasis 5 mm or greater
 - ◊ Metastasis 5 mm or less
 - ◊ Isolated tumor cells (≤0.2 mm)
- Consider mismatch repair (MMR)/microsatellite instability (MSI), PD-L1, and/or *NTRK* gene fusion testing for patients with recurrent, progressive, or metastatic disease
- Consider TMB testing through a validated and/or FDA-approved assay⁷

^aIn situations where SLN metastases are <2 mm, the size of greatest metastasis should be reported. ([See VULVA-4](#)).

^bUltrastaging commonly entails thin serial sectioning of the gross SLN and review of multiple H&E-stained sections with or without cytokeratin immunohistochemistry for all blocks of SLNs. There is not a standard protocol for LN ultrastaging.

^cReport on the number of LNs with metastases of the following sizes: <2 mm; 2–5 mm; and >5 mm. The 2-mm threshold is used to inform treatment selection and 5-mm threshold is used to inform staging.

Note: All recommendations are category 2A unless otherwise indicated.

Clinical Trials: NCCN believes that the best management of any patient with cancer is in a clinical trial. Participation in clinical trials is especially encouraged.

[Continued](#)
[References](#)

VULVA-A
1 OF 3

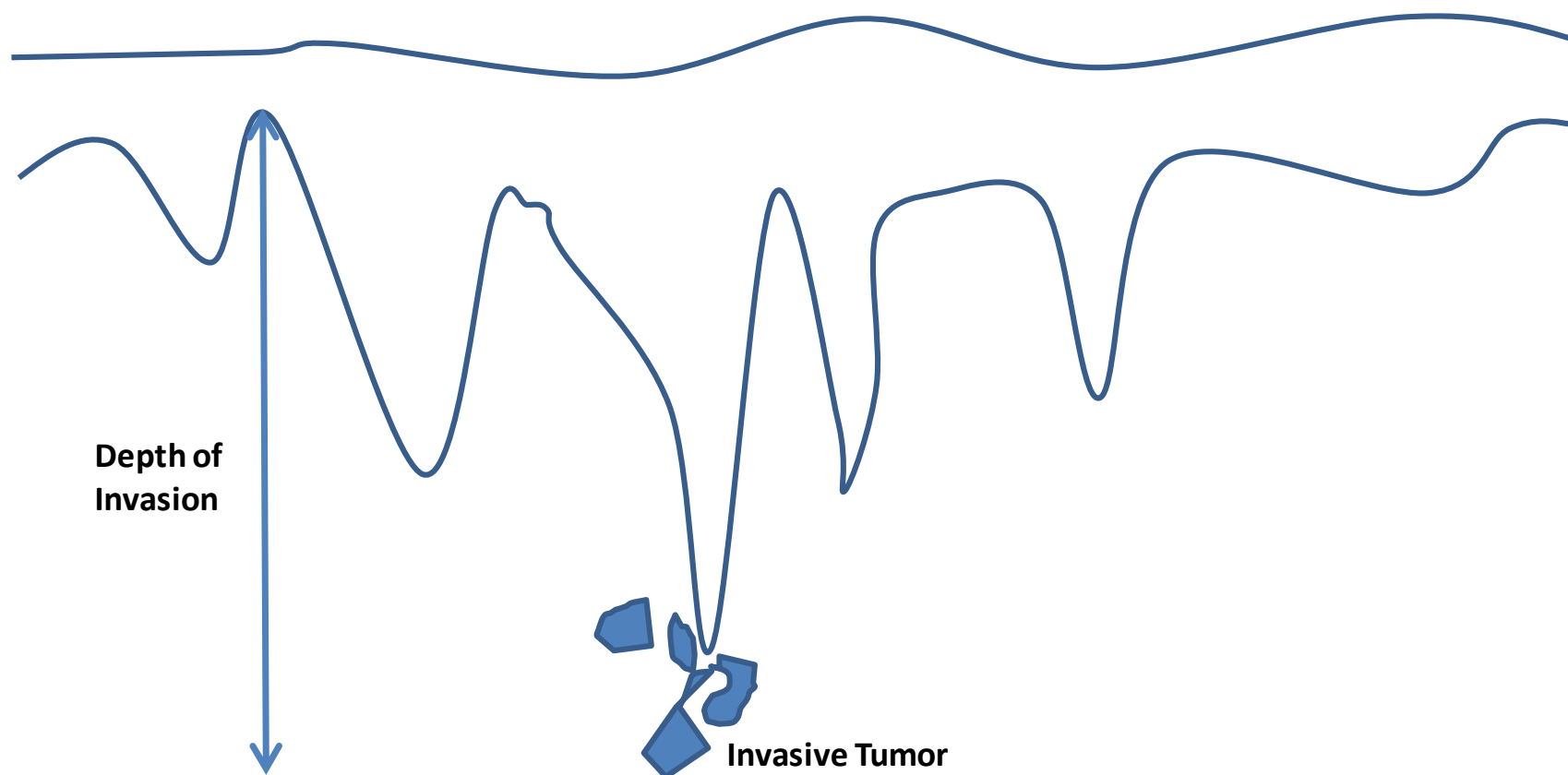


NCCN Guidelines Version 3.2021

Vulvar Cancer (Squamous Cell Carcinoma)

PRINCIPLES OF PATHOLOGY

Figure 1: Depth of Invasion



The depth of stromal invasion is currently defined as the measurement (in millimeters of the tumor from the epithelial-stromal junction of the adjacent most superficial dermal papilla to the deepest point of invasion).

Note: All recommendations are category 2A unless otherwise indicated.

Clinical Trials: NCCN believes that the best management of any patient with cancer is in a clinical trial. Participation in clinical trials is especially encouraged.

[References](#)

VULVA-A
2 OF 3



NCCN Guidelines Version 3.2021

Vulvar Cancer (Squamous Cell Carcinoma)

PRINCIPLES OF PATHOLOGY REFERENCES

- ¹Movahedi-Lankarani S, Krishnamurti U, Bell D, et al. Protocol for the Examination of Specimens from Patients with Primary Carcinoma of the Vulva. College of American Pathologists 2018.
- ²Del Pino M, Rodriguez-Carunchio L, Ordi J. Pathways of vulvar intraepithelial neoplasia and squamous cell carcinoma. Histopathology 2013;62:161-175.
- ³Durman RJ, Carcangui ML, Herrington CS, et al. WHO Classification of Tumours of Female Reproductive Organs, Chapter 9. Tumors of the Vulva, pages 232-235, IARC: Lyon 2014.
- ⁴Zhang J, Zhang Y, Zhang Z. Prevalence of human papillomavirus and its prognostic value in vulvar cancer: A systematic review and meta-analysis. PLoS One 2018;13:e0204162.
- ⁵Pecorelli S. Revised FIGO staging of the vulva, cervix, and endometrium. Int J Gynaecol Obstet 2009;105:103-104.
- ⁶van den Einden LC, Massuger LF, Jonkman JK, et al. An alternative way to measure the depth of invasion of vulvar squamous cell carcinoma in relation to prognosis. Mod Pathol 2015;28:295-302.
- ⁷Merino DM, McShane LM, Fabrizio D, et al. Establishing guidelines to harmonize tumor mutational burden (TMB): in silico assessment of variation in TMB quantification across diagnostic platforms: phase I of the Friends of Cancer Research TMB Harmonization Project. J Immunother Cancer 2020;8:e000147. doi:10.1136/jitc-2019-000147.

Note: All recommendations are category 2A unless otherwise indicated.

Clinical Trials: NCCN believes that the best management of any patient with cancer is in a clinical trial. Participation in clinical trials is especially encouraged.



NCCN Guidelines Version 3.2021

Vulvar Cancer (Squamous Cell Carcinoma)

PRINCIPLES OF IMAGING^{a,1-5}

Initial Workup

- Consider chest imaging with plain radiography (chest x-ray). If an abnormality is seen, then chest CT without contrast may be performed.
- Consider pelvic MRI to aid in surgical and/or radiation treatment planning.^b
- Consider neck/chest/abdomen/pelvis/groin PET/CT or chest/abdomen/pelvic CT for T2 or larger tumors or if metastasis is suspected.^b
- Other initial imaging should be based on symptomatology and clinical concern for metastatic disease.^b

Follow-up/Surveillance

- CT chest/abdomen/pelvis or neck/chest/abdomen/pelvis/groin PET/CT if recurrence/metastasis is suspected.^c
- Consider PET/CT to assess treatment response if primary treatment was with definitive intent.
- Other imaging should be based on symptomatology and clinical concern for recurrent/metastatic disease.^c

Imaging for Suspected or Documented Recurrence

- Consider neck/chest/abdomen/pelvis/groin PET/CT if not previously performed during surveillance.
- Consider pelvic MRI to aid in further treatment planning.

Footnotes

^aMRI and CT are performed with contrast throughout the guidelines unless contraindicated. Contrast is not required for screening chest CT.

^bIndications may include abnormal physical exam findings; bulky vulvar tumor (≥ 4 cm or close to critical structures); vaginal, urethral, or anal involvement; delay in presentation or treatment; and pelvic, abdominal, or pulmonary symptoms.

^cIndications may include abnormal physical exam findings such as palpable new mass or adenopathy, or new pelvic, abdominal, or pulmonary symptoms.

References

¹Salani R, Khanna N, Frimer M, et al. An update on post-treatment surveillance and diagnosis of recurrence in women with gynecologic malignancies: Society of Gynecologic Oncology (SGO) recommendations. *Gynecol Oncol* 2017;146:3-10.

²Kataoka MY, Sala E, Baldwin P, et al. The accuracy of magnetic resonance imaging in staging of vulvar cancer: a retrospective multi-centre study. *Gynecol Oncol* 2010;117:82-87.

³Robertson NL, Hricak H, Sonoda Y, et al. The impact of FDG-PET/CT in the management of patients with vulvar and vaginal cancer. *Gynecol Oncol* 2016;140:420-424.

⁴Elit L, Reade CJ. Recommendations for follow-up care for gynecologic cancer survivors. *Obstet Gynecol* 2015;126:1207-1214.

⁵Viswanathan C, Kirschner K, Truong M, et al. Multimodality imaging of vulvar cancer: staging, therapeutic response, and complications. *AJR AM J Roentgenol* 2013; 200:1387-1400.

Note: All recommendations are category 2A unless otherwise indicated.

Clinical Trials: NCCN believes that the best management of any patient with cancer is in a clinical trial. Participation in clinical trials is especially encouraged.



NCCN Guidelines Version 3.2021

Vulvar Cancer (Squamous Cell Carcinoma)

PRINCIPLES OF SURGERY: TUMOR MARGIN STATUS

- Studies suggest a high overall incidence of local recurrence (or new primary lesions) in vulvar carcinoma.¹ Tumor margin of resection has been postulated as a significant prognostic factor for recurrence in SCC of the vulva; however, presence of dVIN and lichen sclerosus may also play a significant role in recurrence or development of new primary carcinomas.^{2,3,4,5}
- Efforts should be made to obtain adequate gross surgical margins (at least 1 cm) at primary surgery. Recent studies have questioned the traditional (8-mm) pathologic free margin and suggested that a smaller margin may be acceptable, particularly to preserve sensitive areas on the vulva and maintain sexual function.^{6,7,8}
- The definition of a pathologic close margin has also varied from 1–8 mm for formalin-fixed tissue.^{9,10} In the setting of a close margin for invasive cancer at primary resection, observation with regular close follow-up is reasonable. Re-excision should be considered in cases with positive margin for cancer.^{9,11} Adjuvant local radiation therapy (RT) is another alternative.¹² The risk-benefit ratio and morbidity of these approaches must be considered and individualized in each patient. The survival advantage of re-excision and adjuvant vulvar radiation remains to be determined.¹⁰
- Positive margins that involve the urethra, anus, or vagina may not be resectable without incurring significant potential morbidity and adverse impact on patient quality of life.
- Other factors including nodal status should be considered in the decision whether to perform subsequent surgery. Re-excision of close or positive vulvar tumor margins may not be beneficial in patients with metastases to the inguinal nodes that require treatment with EBRT ± chemotherapy after surgery.

Note: All recommendations are category 2A unless otherwise indicated.

Clinical Trials: NCCN believes that the best management of any patient with cancer is in a clinical trial. Participation in clinical trials is especially encouraged.



NCCN Guidelines Version 3.2021

Vulvar Cancer (Squamous Cell Carcinoma)

PRINCIPLES OF SURGERY: SURGICAL STAGING

- Vulvar cancer is staged using the American Joint Committee on Cancer (AJCC) and the International Federation of Gynecology and Obstetrics (FIGO) staging systems ([Table ST-1](#)).^{13,14}
- Staging involves complete surgical resection of the primary vulvar tumor(s) with at least 1-cm clinical gross margins and either a unilateral or bilateral inguofemoral lymphadenectomy or an SLN biopsy in select patients. Inguofemoral lymphadenectomy removes the LNs along the inguinal ligament, within the proximal femoral triangle, and deep to the cribriform fascia.
- LN status is the most important determinant of survival.¹⁵
- Historically, en bloc resection of the vulvar tumor and complete bilateral inguofemoral lymphadenectomy (resection of superficial inguinal and deep femoral nodes) were performed, but this approach was associated with significant morbidity.¹⁶
- The current standard involves resection of the vulvar tumor and LNs through separate incisions.¹⁶
- The choice of vulvar tumor resection technique depends on the size and extent of the primary lesion and may include partial or total vulvectomy, and the depth of resection may be superficial/skinning, simple, or radical.¹⁷
- The depth of the resection for radical vulvectomy is to the urogenital diaphragm, or median perineal fascia or periosteum of pubic bone.¹⁸
- There are no prospective trials comparing the resection techniques above. Retrospective data suggest there is no difference in recurrence outcome between radical partial vulvectomy compared with radical total vulvectomy.
- For a unifocal primary vulvar tumor that is <4 cm diameter, located 2 cm or more from the vulvar midline and in the setting of clinically negative inguofemoral LNs, a unilateral inguofemoral lymphadenectomy or SLN biopsy is appropriate ([See Principles of Surgery: Inguofemoral Sentinel Lymph Node Biopsy VULVA-C 4 of 5](#)).¹⁹
- For a primary vulvar tumor located within 2 cm from or crossing the vulvar midline, a bilateral inguofemoral lymphadenectomy¹⁹ or SLN biopsy is recommended.
- Inguofemoral lymphadenectomy or SLN biopsy can be omitted in patients with stage IA primary disease with clinically negative groins due to a <1% risk of lymphatic metastases.¹⁹

Note: All recommendations are category 2A unless otherwise indicated.

Clinical Trials: NCCN believes that the best management of any patient with cancer is in a clinical trial. Participation in clinical trials is especially encouraged.

[Continued](#)
[References](#)

VULVA-C
2 OF 5



NCCN Guidelines Version 3.2021

Vulvar Cancer (Squamous Cell Carcinoma)

PRINCIPLES OF SURGERY: SURGICAL STAGING

- For patients with stage IB–II disease, inguofemoral lymphadenectomy is recommended due to a risk of >8% of lymphatic metastases.¹⁹
- A negative unilateral inguofemoral lymphadenectomy is associated with a <3% risk of contralateral metastases.²⁰
- In the setting of positive LN disease after unilateral inguofemoral lymphadenectomy, contralateral inguofemoral lymphadenectomy¹⁵ or radiation of the contralateral groin is recommended. Any nodes that are grossly enlarged or suspicious for metastases during the unilateral inguofemoral lymphadenectomy should be evaluated by frozen section pathology intraoperatively in order to tailor the extent and bilaterality of the lymphadenectomy.
- Those with locally advanced disease may benefit from neoadjuvant radiation with concurrent platinum-based radiosensitizing chemotherapy. If a complete response is not achieved, surgical resection of the residual disease is recommended in patients with resectable disease who are appropriate surgical candidates.¹⁹
- The management of bulky inguofemoral LNs in the setting of an unresectable or T3 primary vulvar lesion is unclear. It is reasonable to consider either: 1) primary cytoreductive surgery of the bulky LNs followed by platinum-based chemosensitizing radiation to the bilateral groins and primary vulvar tumor; or 2) platinum-based chemosensitizing radiation to the bilateral groins and primary vulvar tumor alone.²¹

Note: All recommendations are category 2A unless otherwise indicated.

Clinical Trials: NCCN believes that the best management of any patient with cancer is in a clinical trial. Participation in clinical trials is especially encouraged.



NCCN Guidelines Version 3.2021

Vulvar Cancer (Squamous Cell Carcinoma)

PRINCIPLES OF SURGERY: INGUINOFEMORAL SENTINEL LYMPH NODE BIOPSY

- Unilateral or bilateral inguinofemoral lymphadenectomy is associated with a high rate of postoperative morbidity; 20%–40% of patients are at risk of wound complications and 30%–70% of patients are at risk for lymphedema.^{22,23}
- Increasing evidence suggests that the use of SLN biopsy of the inguinofemoral LN basin is an alternative standard-of-care approach to lymphadenectomy in select women with SCC of the vulva.^{24,25}
- SLN biopsy results in decreased postoperative morbidity without compromising detection of LN metastases.^{24,26}
- Prospective, cooperative group trials have evaluated the SLN technique and demonstrate feasibility, safety, validity, and a low risk of groin recurrences with this surgical approach in vulvar cancer.^{24,25}
- Candidates for SLN biopsy include patients with negative clinical groin examination and/or imaging, and a primary unifocal vulvar tumor size of <4 cm.^{25,27,28}
- If SLN biopsy is considered, it should be performed by an experienced high-volume SLN surgeon, as high-volume surgeons exhibit improved SLN detection rates.^{25,27}
- Increased sensitivity of SLN detection is observed when both radiocolloid and blue dye are used.^{24,25,26} The radiocolloid most commonly injected into the vulvar tumors is technetium-99m sulfur colloid. It is most commonly injected 2–4 hours prior to the vulvectomy and lymphadenectomy procedure. A preoperative lymphoscintigraphy may be performed to aid in anatomically locating the sentinel node. The blue dye most commonly used is Isosulfan Blue 1%. Approximately 4 cc of dye is injected peritumorally using a four-point injection technique at 2, 5, 7, and 10 o'clock. The blue dye is injected in 4 quadrants intradermally around the leading edges of the tumor.
- It is recommended that the SLN procedure is performed prior to the excision of the vulvar tumor, so as not to disrupt the lymphatic network between the primary vulvar tumor and the inguinofemoral LN basin. Additionally, the injected blue dye will only transiently localize (ie, for 30–60 minutes) in the first group of nodes that correspond to the primary vulvar tumors.
- Use of a gamma probe to detect the injected radiocolloid within the inguinofemoral region is recommended prior to making the groin incision in order to tailor the location and size of the incision.
- A side-specific complete inguinofemoral lymphadenectomy is recommended if an ipsilateral SLN is not detected.
- Completion inguinofemoral lymphadenectomy is the preferred approach in the presence of metastases >2 mm in diameter in the SLNs.
- If ipsilateral SLN is positive, the contralateral groin should be evaluated surgically and/or treated with EBRT.
- Selective frozen section of sentinel node may guide the intraoperative decision regarding need for completion unilateral or bilateral inguinofemoral lymphadenectomy.

Note: All recommendations are category 2A unless otherwise indicated.

Clinical Trials: NCCN believes that the best management of any patient with cancer is in a clinical trial. Participation in clinical trials is especially encouraged.

References

VULVA-C
4 OF 5



NCCN Guidelines Version 3.2021

Vulvar Cancer (Squamous Cell Carcinoma)

PRINCIPLES OF SURGERY REFERENCES

- ¹Rouzier R, Haddad B, Plantier F, et al. Local relapse in patients treated for squamous cell vulvar carcinoma: incidence and prognostic value. *Obstet Gynecol* 2002;100:1159-1167.
- ²Te Grootenhuis NC, Pouwer AW, de Bock GH, et al. Margin status revisited in vulvar squamous cell carcinoma. *Gynecol Oncol* 2019;154:266-275.
- ³Pleunis N, Leermakers MEJ, van der Wurff AA, et al. Surgical margins in squamous cell carcinoma, different for the vulva? *Eur J Surg Oncol* 2018;44:1555-1561.
- ⁴Heaps JM, Fu YS, Montz FJ, et al. Surgical-pathologic variables predictive of local recurrence in squamous cell carcinoma of the vulva. *Gynecol Oncol* 1990;38:309-314.
- ⁵De Hullu JA, Hollema H, Lolkema S, et al. Vuvur carcinoma. The price of less radical surgery. *Cancer* 2002;95:2331-2338.
- ⁶Woelber L, Griebel L, Eulenburg C, et al. Role of tumour-free margin distance for loco-regional control in vulvar cancer: a subset analysis of the Arbeitsgemeinschaft Gynäkologische Onkologie CaRE-1 multicenter study. *Eur J Cancer* 2016;69:180-188.
- ⁷Woelber L, Choschzick M, Eulenburg C, et al. Prognostic value of pathological resection margin distance in squamous cell cancer of the vulva. *Ann Surg Oncol* 2011;18:3811-3818.
- ⁸Groenen SMA, Timmers PJ, Burger CW. Recurrence rate in vulvar carcinoma in relation to pathological margin distance. *Int J Gynecol Cancer* 2010;20:869-873.
- ⁹Ioffe YJ, Erickson BK, Foster KE, et al. Low yield of residual vulvar carcinoma and dysplasia upon re-excision for close or positive margins. *Gynecol Oncol* 2013;129:528-532.
- ¹⁰Bedell SM, Hedberg C, Griffin A, et al. Role of adjuvant radiation or re-excision for early stage vulvar squamous cell carcinoma with positive or close surgical margins. *Gynecol Oncol* 2019;154:276-279.
- ¹¹Arvas M, Kahramanoglu I, Bese T, et al. The role of pathological margin distance and prognostic factors after primary surgery in squamous cell carcinoma of the vulva. *Int J Gynecol Cancer* 2018;28:623-631.
- ¹²Faul CM, Mirmow D, Huang Q, et al. Adjuvant radiation for vulvar carcinoma: improved local control. *Ing J Radiat Oncol Biol Phys* 1997;38:381-389.
- ¹³Pecorelli S. Revised FIGO staging of the vulva, cervix, and endometrium. *Int J Gynaecol Obstet* 2009;105:103-104.
- ¹⁴Vulva: In American Joint Committee on Cancer Staging Manual, 7th, Edge SB, Byrd DR, Compton CC, et al Eds. Springer, New York 2010. p. 379.
- ¹⁵Burger MP, Hollema H, Emanuels AG, et al. The importance of groin node status to survival of T1 and T2 vulvar carcinoma patients. *Gynecol Oncol* 1995;57:327-334.
- ¹⁶DiSaia P, Creasman WT, Rich WM. An alternate approach to early cancer of the vulva. *Am J Obstet Gynecol* 1979;133:825-832.
- ¹⁷Micheletti L, Haefner H, Zalewski K, et al. The International Society for the study of vulvovaginal disease surgical oncological procedure definitions committee "surgical terminology for vulvar treatment." *J Low Genit Tract Dis* 2020;24:62-68.
- ¹⁸De Hullu JA, Hollema H, Lolkema S, et al. Vulvar carcinoma. The price of less radical surgery. *Cancer* 2002;95:2331-2338.
- ¹⁹Stehman FB, Look KY. Carcinoma of the vulva. *Obstet Gynecol* 2006;107:719-733.
- ²⁰Gonzalez-Bosquet J, Magrina JF, Magtibay PM, et al. Patterns of inguinal groin node metastases in squamous cell carcinoma of the vulva. *Gynecol Oncol* 2007;105:742-746.
- ²¹Moore DH, Ali S, Koh WJ, et al. A phase II trial of radiation therapy and weekly cisplatin chemotherapy for the treatment of locally advanced squamous cell carcinoma of the vulva: a gynecologic oncology group study. *Gynecol Oncol* 2012;124:529-533.
- ²²DiSaia PJ, Creasman WT, Rich WM. An alternate approach to early cancer of the vulva. *Am J Obstet Gynecol* 1979;133:825-832.
- ²³Carlson JW, Kauderer J, Hutson A, et al. GOG 244, the lymphedema and gynecologic cancer (LEG) study: Incidence and risk factors in newly diagnosed patients. *Gynecol Oncol* 2018;149:6-7.
- ²⁴Van der Zee AG, Oonk MH, De Hullu JA, et al. Sentinel lymph node dissection is safe in the treatment of early-stage vulvar carcinoma. *J Clin Oncol* 2008;26:884-889.
- ²⁵Levenback CF, Ali S, Coleman R, et al. Lymphatic mapping and sentinel lymph node biopsy in women with squamous cell carcinoma of the vulva: a gynecologic oncology group study. *J Clin Oncol* 2012;30:3786-3791.
- ²⁶Oonk MH, van Hemel BM, Hollema H, et al. Size of sentinel-node metastasis and chances of non-sentinel-node involvement and survival in early stage vulvar cancer: results from GROINSS-V, a multicentre observational study. *Lancet Oncol* 2010;11:646-652.
- ²⁷Covens A, Vella ET, Kennedy EB, et al. Sentinel lymph node biopsy in vulvar cancer: Systematic review, meta-analysis and guideline recommendations. *Gynecol Oncol* 2015;137:351-361.
- ²⁸Te Grootenhuis NC, van der Zee AG, van Doorn HC, et al. Sentinel nodes in vulvar cancer: Long-term follow-up of the GROningen International Study on Sentinel nodes in Vulvar cancer (GROINSS-V) I. *Gynecol Oncol* 2016 Jan;140:8-14.

Note: All recommendations are category 2A unless otherwise indicated.

Clinical Trials: NCCN believes that the best management of any patient with cancer is in a clinical trial. Participation in clinical trials is especially encouraged.



NCCN Guidelines Version 3.2021

Vulvar Cancer (Squamous Cell Carcinoma)

PRINCIPLES OF RADIATION THERAPY

General Principles

- RT is often used in the management of patients with vulvar cancer as adjuvant therapy following initial surgery, as part of primary therapy in locally advanced disease, or for secondary therapy/palliation in recurrent/metastatic disease.
- Radiation technique and doses are important to maximize tumor control while limiting adjacent normal tissue toxicity.
- Tumor-directed RT refers to RT directed at sites of known or suspected tumor involvement. In general, tumor-directed EBRT is directed to the vulva and/or inguinofemoral, external, and internal iliac nodal regions. Brachytherapy can sometimes be used as a boost to anatomically amenable primary tumors. Careful attention should be taken to ensure adequate tumor coverage by combining clinical examination, imaging findings, and appropriate nodal volumes at risk to define the target volume. For example, invasion into the anus above the pectinate line would necessitate coverage of the perirectal nodes.^{1,2}
- Ensure coverage of gross tumor burden with margin. In highly selected cases where only a superficial vulvar target is to be treated, an enface electron beam may be used.
- Utilization of imaging studies are an important part of the treatment planning process. The use of CT-based treatment planning and conformal blocking is considered the standard of care for EBRT.
- Historically, a widely disparate range of approaches has been described. In an attempt to better standardize RT use and techniques, a recent international survey, with consequent recommendations, has been reported.³
- Acute effects during RT (eg, diarrhea, bladder irritation, fatigue, mucocutaneous reaction) are expected to some degree in most patients, and can be further accentuated by concurrent chemotherapy. These toxicities should be aggressively managed (eg, local skin care, symptomatic medications), and treatment breaks should be avoided or minimized. Many patients may develop an overgrowth of *Candida albicans*; treatment with oral and local antifungal agents will markedly reduce skin reaction. If a bacterial infection develops, prompt recognition and appropriate treatment is essential. These acute effects generally resolve several weeks after completion of radiation.
- Postoperative adjuvant treatment should be initiated as soon as adequate healing is achieved, preferably within 6–8 weeks.

Note: All recommendations are category 2A unless otherwise indicated.

Clinical Trials: NCCN believes that the best management of any patient with cancer is in a clinical trial. Participation in clinical trials is especially encouraged.

[Continued](#)
[References](#)

VULVA-D
1 OF 5



NCCN Guidelines Version 3.2021

Vulvar Cancer (Squamous Cell Carcinoma)

PRINCIPLES OF RADIATION THERAPY

Treatment Information – 3D Conformal/Anterior-Posterior (AP/PA) Fields

• Target Volumes

- ▶ The target is best defined by both physical examination and CT-based treatment planning; contouring of the target structures is recommended. When an AP/PA technique is primarily used, often wide AP and narrower PA fields are used with electrons supplementing the dose to the inguinal region if the depth of the inguinal nodes allows for electron coverage. More conformal techniques such as three- or four-field approaches may allow for greater sparing of bowel and/or bladder, depending on tumor extent and patient anatomy. CT or MRI planning, with possible image fusion technology, should be used to assure adequate dosing and coverage with contouring of the primary, and the inguinofemoral and iliac nodes. Radio-opaque markers should be placed on key landmarks at the time of simulation to assist in definition of the primary target volume.
- ▶ The superior field border should be no lower than the bottom of the sacroiliac joints or higher than the L4/L5 junction unless pelvic nodes are involved. If pelvic nodes are involved, the upper border can be raised to at least 2 cm above the most cephalad-positive node. The superior border should extend as a horizontal line to cover the inguinofemoral nodes at the level of the anterior-inferior iliac spine. The lateral border will be a vertical line drawn from the anterior-inferior iliac spine. To adequately cover the inguinal nodes, the inferior-lateral inguinal nodal border should be parallel to the inguinal crease and inferior enough to encompass the inguinofemoral nodal bed to the intertrochanteric line of the femur or 1.5–2 cm distal to the saphenofemoral junction. The inferior vulvar border will be lower and should be at least 2 cm below the most distal part of the vulva. Care should be taken to spare the femoral heads and necks.
- ▶ In both the locally advanced and postoperative settings, especially when there is ≥ 1 LN clinically suspicious or pathologically positive, the bilateral inguinal and pelvic lymphatic regions are typically included in the radiotherapy clinical target volume (CTV). Selective coverage of the primary may be appropriate. While classic indications for treating the primary site include close/positive margin, lymphovascular space invasion (LVSI), and >5 -mm depth of invasion, groin involvement may also be considered a relative indication to include the primary site. While it may be tempting to add a midline block in the postoperative setting to avoid radiation toxicity to sensitive central structures, use of a midline block in stage III–IV vulvar cancer has been associated with a high rate of central recurrence; thus, such practice is usually discouraged. Conversely, there may be clinical situations in which it is desirable to cover the primary site only and avoid the nodes.

Note: All recommendations are category 2A unless otherwise indicated.

Clinical Trials: NCCN believes that the best management of any patient with cancer is in a clinical trial. Participation in clinical trials is especially encouraged.

[Continued](#)
[References](#)

VULVA-D
2 OF 5



NCCN Guidelines Version 3.2021

Vulvar Cancer (Squamous Cell Carcinoma)

PRINCIPLES OF RADIATION THERAPY

Treatment Information – Intensity-Modulated Radiation Therapy (IMRT)⁴

- The vulvar and nodal targets should be contoured on the planning CT. Any gross vulvar disease should be contoured as a gross tumor volume (GTV) and include any visible and/or palpable extension. The vulvar CTV target is defined as the GTV or tumor bed plus the adjacent skin, mucosa, and subcutaneous tissue of the vulva excluding bony tissue. A wire placed clinically to define the vulvar skin borders and the GTV during CT simulation is essential. In addition, a marker on the anus, urethra, clitoris, and the wiring of any scars will aid in planning.
- To ensure adequate distal margin on the vulvar target volume, a “false structure” or bolus should be placed over the vulva for treatment planning purposes. Doses to the target areas should be confirmed using thermoluminescent dosimeter (TLD) at first treatment.
- Symmetrical geometric expansions on the vessels should NOT be used for the inguinofemoral nodes. The inguinofemoral nodal CTV will extend laterally from the inguinofemoral vessels to the medial border of the sartorius and rectus femoris muscles, posteriorly to the anterior vastus medialis muscle, and medially to the pectineus muscle or 2.5–3 cm medially from the vessels. Anteriorly, the volume should extend to the anterior border of the sartorius muscle (the most anterior muscle on the lateral inguinofemoral border). The caudal extent of the inguinofemoral nodal basin is the top of the lesser trochanter of the femur.²
- The pelvic nodal CTV is the vasculature of the bilateral external iliac, obturator, and internal iliac nodal regions with a minimum of 7 mm of symmetrical expansion excluding bone and muscle.
- The groin CTV volume will not extend outside the skin and should be trimmed by 3 mm in the absence of skin involvement (with skin involvement, the CTV should extend to the skin with bolus material applied during treatment). Planning target volume (PTV) expansion is then 7–10 mm.
- Image-guided IMRT is an essential component of treatment (to account for vulva edema or marked tumor regression).
- Planning should be taken with care to respect normal tissue tolerances such as rectum, bladder, small bowel, and femoral head and neck.⁵

General Treatment Information

- Bolus should be used to ensure adequate dosing to superficial target volume both at the primary site and when LNs are just below the skin surface.
- TLD, optically stimulated luminescence dosimeter (OSLD), or electronic dosimetry to skin may be used for dose verification.

Note: All recommendations are category 2A unless otherwise indicated.

Clinical Trials: NCCN believes that the best management of any patient with cancer is in a clinical trial. Participation in clinical trials is especially encouraged.

[Continued](#)
[References](#)

VULVA-D
3 OF 5



NCCN Guidelines Version 3.2021

Vulvar Cancer (Squamous Cell Carcinoma)

PRINCIPLES OF RADIATION THERAPY

Dosing Prescription Regimen

- The target tissues should be treated once daily, 5 days per week. Breaks from treatment should be minimized. Adequate dosing is crucial and can be accomplished with either 3D conformal approaches or IMRT as long as care is given to assure adequate dosing and coverage of tissues at risk for tumor involvement.^{1,6}
- Doses range from 45–50.4 Gy in 25–28 fractions (1.8 Gy fractions) for adjuvant therapy to 59.4–64.8 Gy in 33–36 total fractions (1.8 Gy fractions) for unresectable disease. In select cases, bulky/persistent primary disease or large nodes that are unresectable may be boosted to 70 Gy.
- Suggested dosing to areas of risk:
 - Gross primary vulva disease = 60–70 Gy
 - Primary surgical bed (post op, negative margins) = 45–50 Gy
 - Primary surgical bed (post op close or positive margins) = 54–60 Gy
 - Clinically and/or radiographically uninvolved inguinofemoral LNs = 45–50 Gy
 - Inguinofemoral LNs (positive, no extracapsular extension [ECE] or gross residual disease) = 50–55 Gy
 - Inguinofemoral LNs (ECE) = 54–64 Gy
 - LNs (gross residual or unresectable disease) = 60–70 Gy

Note: All recommendations are category 2A unless otherwise indicated.

Clinical Trials: NCCN believes that the best management of any patient with cancer is in a clinical trial. Participation in clinical trials is especially encouraged.

References

VULVA-D
4 OF 5



NCCN Guidelines Version 3.2021

Vulvar Cancer (Squamous Cell Carcinoma)

PRINCIPLES OF RADIATION THERAPY REFERENCES

- ¹Beriwal S, Shukla G, Shinde A, et al. Preoperative intensity modulated radiation therapy and chemotherapy for locally advanced vulvar carcinoma: analysis of pattern of relapse. *Int J Radiat Oncol Biol Phys* 2013;85:1269-1274.
- ²Kim CH, Olson AC, Kim H, Beriwal S. Contouring inguinal and femoral nodes; how much margin is needed around the vessels? *Pract Radiat Oncol* 2012;2:274-278.
- ³Gaffney DK, King B, Viswanathan AN, et al. Consensus recommendations for radiation therapy contouring and treatment of vulvar carcinoma. *Int J Radiat Oncol Biol Phys* 2016;95:1191-1200.
- ⁴Rishi A, Rollins M, Ahmed KA, et al. High-dose intensity-modulated chemoradiotherapy in vulvar squamous cell carcinoma: Outcome and toxicity. *Gynecol Oncol* 2020;156(2):349-356.
- ⁵Kachnic LA, Winter K, Myerson RJ, et al. RTOG 0529: a phase 2 evaluation of dose-painted intensity modulated radiation therapy in combination with 5-fluorouracil and mitomycin-C for the reduction of acute morbidity in carcinoma of the anal canal. *Int J Radiat Oncol Biol Phys* 2013;86:27-33.
- ⁶Moore DH, Ali S, Koh WJ, et al. A phase II trial of radiation therapy and weekly cisplatin chemotherapy for the treatment of locally-advanced squamous cell carcinoma of the vulva: a gynecologic oncology group study. *Gynecol Oncol* 2012;124:529-533.

Note: All recommendations are category 2A unless otherwise indicated.

Clinical Trials: NCCN believes that the best management of any patient with cancer is in a clinical trial. Participation in clinical trials is especially encouraged.



NCCN Guidelines Version 3.2021

Vulvar Cancer (Squamous Cell Carcinoma)

SYSTEMIC THERAPY¹

Chemoradiation		
Preferred Regimens	Other Recommended Regimens	Useful In Certain Circumstances
• Cisplatin	• Cisplatin/fluorouracil • Fluorouracil/mitomycin C ²	N/A

Advanced or Recurrent/Metastatic Disease			
	Preferred Regimens	Other Recommended Regimens	Useful In Certain Circumstances
Systemic therapies	• Cisplatin • Carboplatin • Cisplatin/paclitaxel • Carboplatin/paclitaxel • Cisplatin/paclitaxel/bevacizumab ^a	• Paclitaxel • Cisplatin/vinorelbine • Erlotinib (category 2B) ³ • Cisplatin/gemcitabine (category 2B) • Carboplatin/paclitaxel/bevacizumab (category 2B) ^a	N/A
Biomarker-directed systemic therapy for second-line treatment	N/A	N/A	• Pembrolizumab ^b (second-line therapy for TMB-H, ^{c,4} PD-L1–positive, ^d or MSI-high [MSI-H]/MMR deficient [dMMR] tumors ⁵) • Nivolumab ^{e,6} • Larotrectinib or entrectinib for <i>NTRK</i> gene fusion-positive tumors (category 2B)

Footnotes

^aAn FDA-approved biosimilar is an appropriate substitute for bevacizumab.

^bSee [NCCN Guidelines for Management of Immunotherapy-Related Toxicities](#).

^cFor the treatment of patients with unresectable or metastatic tumor mutational burden-high (TMB-H) [≥10 mutations/megabase (mut/Mb)] tumors, as determined by an FDA-approved test, that have progressed following prior treatment and who have no satisfactory alternative treatment options.

^dRecommended for disease progression on or after chemotherapy in patients whose tumors express PD-L1 (CPS ≥1) as determined by an FDA-approved test.

^eFor HPV-related advanced or recurrent/metastatic vulvar cancer.

Note: All recommendations are category 2A unless otherwise indicated.

Clinical Trials: NCCN believes that the best management of any patient with cancer is in a clinical trial. Participation in clinical trials is especially encouraged.

References

VULVA-E
1 OF 2



NCCN Guidelines Version 3.2021

Vulvar Cancer (Squamous Cell Carcinoma)

SYSTEMIC THERAPY REFERENCES

- ¹Reade CJ, Eiriksson LR, Mackay H. Systemic chemotherapy in squamous cell carcinoma of the vulva: current status and future directions. *Gynecol Oncol* 2014;132:780-789.
- ²Anal cancer literature supports the use of mitomycin-based regimens based on high-quality evidence. Chin JY, Hong TS, Ryan DP. Mitomycin in anal cancer: still the standard of care. *J Clin Oncol* 2012;30:4297-4301.
- ³Horowitz NS, Olawaiye AB, Borger DR, et al. Phase II trial of erlotinib in women with squamous cell carcinoma of the vulva. *Gynecol Oncol* 2012;127:141-146.
- ⁴Marabelle A, et al. Association of tumour mutational burden with outcomes in patients with advanced solid tumours treated with pembrolizumab: prospective biomarker analysis of the multicohort, open-label, phase 2 KEYNOTE-158 study. *Lancet Oncol*. 2020;21(10):1353-1365.
- ⁵Marabelle A, Le DT, Ascierto PA, et al. Efficacy of pembrolizumab in patients with noncolorectal high microsatellite instability/mismatch repair-deficient cancer: results from the phase 2 KEYNOTE-158 study. *J Clin Oncol* 2020;38:1-10.
- ⁶Naumann RW, Hollebecque A, Meyer T, et al. Safety and Efficacy of Nivolumab Monotherapy in Recurrent or Metastatic Cervical, Vaginal, or Vulvar Carcinoma: Results From the Phase I/II CheckMate 358 Trial. *J Clin Oncol* 2019;37:2825-2834.

Note: All recommendations are category 2A unless otherwise indicated.

Clinical Trials: NCCN believes that the best management of any patient with cancer is in a clinical trial. Participation in clinical trials is especially encouraged.



NCCN Guidelines Version 3.2021

Vulvar Cancer (Squamous Cell Carcinoma)

PRINCIPLES OF GYNECOLOGIC SURVIVORSHIP

Physical Effects

- Gynecologic cancer treatment typically involves surgery, chemotherapy, hormone therapy, radiation therapy, and/or immunotherapy. These treatments cause acute, short-term, and long-term toxicities.
- Surgical approaches may be extensive and pose risks such as adhesion formation, which may cause pain and may contribute to small bowel obstruction, urinary or gastrointestinal complications (eg, incontinence, diarrhea), pelvic floor dysfunction (manifested by a variety of urinary, bowel, and/or sexual effects), and lymphedema.
- Chemotherapy agents vary, though commonly used regimens may pose a significant risk of neurotoxicity, cardiac toxicity, development of hematologic cancers, and cognitive dysfunction.
- Long-term estrogen deprivation may cause symptoms such as hot flashes, vaginal dryness, and bone loss.
- Radiation therapy may cause long-term complications (eg, fibrosis, vulvovaginal atrophy) and may predispose patients to secondary cancers of the subcutaneous tissue, and/or underlying organs that are proximal to the radiation field.
- Immunotherapy use is emerging, and to date, long-term effects of these treatments are unknown.

Psychosocial Effects

- Psychosocial effects after cancer may include psychological (eg, depression, anxiety, fear of recurrence, altered body image), financial (eg, return to work, insurance concerns), and interpersonal (eg, relationships, sexuality, intimacy) effects.

Clinical Approach

- All gynecologic cancer survivors should receive regular general medical care that focuses on chronic disease management, monitoring of cardiovascular risk factors, recommended vaccinations, and encouraging adoption of a healthy lifestyle.
- In order to assess the late and long-term effects of gynecologic cancers, clinicians should comprehensively document the patient's history, conduct a thorough physical examination, and conduct necessary imaging and/or laboratory testing. All women, whether sexually active or not, should be asked about genitourinary symptoms, including vulvovaginal dryness. Referral to appropriate specialty providers (eg, physical therapy, pelvic floor therapy, sexual therapy, psychotherapy) is recommended. As most treatments for gynecologic cancers will cause sexual dysfunction, early menopause, and infertility, special attention to the resultant medical and psychosocial implications is needed.
- Post-radiation use of vaginal dilators and moisturizers is recommended.
- Communication and coordination with all clinicians involved in the care of survivors, including primary care clinicians, is critical. Providing cancer survivors with a summary of their treatment and recommendations for follow-up is recommended.

Additional Guidance

- [See NCCN Guidelines for Distress Management](#)
- [See NCCN Guidelines for Smoking Cessation](#)
- [See NCCN Guidelines for Survivorship](#)

Note: All recommendations are category 2A unless otherwise indicated.

Clinical Trials: NCCN believes that the best management of any patient with cancer is in a clinical trial. Participation in clinical trials is especially encouraged.



NCCN Guidelines Version 3.2021

Vulvar Cancer (Squamous Cell Carcinoma)

Staging-Vulvar Cancer

Table 1. AJCC Tumor-Node-Metastases (TNM) and International Federation of Gynecology and Obstetrics (FIGO) Surgical Staging Systems for Carcinoma of the Vulva

T	FIGO Stage	Primary Tumor
TX		Primary tumor cannot be assessed
T0		No evidence of primary tumor
T1	I	Tumor confined to the vulva and/or perineum. Multifocal lesions should be designated as such. The largest lesion or the lesion with the greatest depth of invasion will be the target lesion identified to address the highest pT stage. Depth of invasion is defined as the measurement of the tumor from the epithelial–stromal junction of the adjacent most superficial dermal papilla to the deepest point of invasion.
T1a	IA	Lesions 2 cm or less, confined to the vulva and/or perineum, and with stromal invasion of 1.0 mm or less
T1b	IB	Lesions more than 2 cm, or any size with stromal invasion of more than 1.0 mm, confined to the vulva and/or perineum
T2	II	Tumor of any size with extension to adjacent perineal structures (lower/distal third of the urethra, lower/distal third of the vagina, anal involvement)
T3	IVA	Tumor of any size with extension to any of the following—upper/proximal two thirds of the urethra, upper/proximal two thirds of the vagina, bladder mucosa, or rectal mucosa—or fixed to pelvic bone

[Continued](#)

Used with permission of the American College of Surgeons, Chicago, Illinois. The original source for this information is the AJCC Cancer Staging Manual, Eighth Edition (2017) published by Springer International Publishing.

Reprinted from: Pecorelli S. Revised FIGO staging for carcinoma of the vulva, cervix and endometrium. FIGO Committee on Gynecologic Oncology. Int J Gynaecol Obstet 2009;105:103-104. Copyright 2009, with permission from International Federation of Gynecology and Obstetrics.



NCCN Guidelines Version 3.2021

Vulvar Cancer (Squamous Cell Carcinoma)

Staging-Vulvar Cancer

Table 1 continued

N	FIGO Stage	Regional Lymph Nodes	M	FIGO Stage	Distant Metastasis
NX		Regional lymph nodes cannot be assessed	M0		No distant metastasis (no pathological M0; use clinical M to complete stage group)
N0		No regional lymph node metastasis	M1	IVB	Distant metastasis (including pelvic lymph node metastasis)
N0(i+)		Isolated tumor cells in regional lymph node(s) no greater than 0.2 mm			
N1	III	Regional lymph node metastasis with one or two lymph node metastases each less than 5 mm, or one lymph node metastasis greater than or equal to 5 mm			
N1a*	IIIA	One or two lymph node metastases each less than 5 mm			
N1b	IIIA	One lymph node metastasis greater than or equal to 5 mm			
N2		Regional lymph node metastasis with three or more lymph node metastases each less than 5 mm, or two or more lymph node metastases greater than or equal to 5 mm, or lymph node(s) with extranodal extension			
N2a*	IIIB	Three or more lymph node metastases each less than 5 mm			
N2b	IIIB	Two or more lymph node metastases greater than or equal to 5 mm			
N2c	IIIC	Lymph node(s) with extranodal extension			
N3	IVA	Fixed or ulcerated regional lymph node metastasis			

*Includes micrometastasis, N1mi and N2mi.

Note: The site, size, and laterality of lymph node metastases should be recorded.

G Histologic Grade

GX Grade cannot be assessed

G1 Well differentiated

G2 Moderately differentiated

G3 Poorly differentiated

[Continued](#)

Used with permission of the American College of Surgeons, Chicago, Illinois. The original source for this information is the AJCC Cancer Staging Manual, Eighth Edition (2017) published by Springer International Publishing.

Reprinted from: Pecorelli S. Revised FIGO staging for carcinoma of the vulva, cervix and endometrium. FIGO Committee on Gynecologic Oncology. Int J Gynaecol Obstet 2009;105:103-104. Copyright 2009, with permission from International Federation of Gynecology and Obstetrics.



NCCN Guidelines Version 3.2021

Vulvar Cancer (Squamous Cell Carcinoma)

Staging-Vulvar Cancer

Table 2. AJCC Prognostic Stage Groups

	T	N	M
Stage I	T1	N0	M0
Stage IA	T1a	N0	M0
Stage IB	T1b	N0	M0
Stage II	T2	N0	M0
Stage III	T1-T2	N1-N2c	M0
Stage IIIA	T1-T2	N1	M0
Stage IIIB	T1-T2	N2a,N2b	M0
Stage IIIC	T1-T2	N2c	M0
Stage IV	T1-T3	N3	M0
Stage IVA	T1-T2	N3	M0
Stage IVA	T3	Any N	M0
Stage IVB	Any T	Any N	M1

Used with permission of the American College of Surgeons, Chicago, Illinois. The original source for this information is the AJCC Cancer Staging Manual, Eighth Edition (2017) published by Springer International Publishing.

Reprinted from: Pecorelli S. Revised FIGO staging for carcinoma of the vulva, cervix and endometrium. FIGO Committee on Gynecologic Oncology. Int J Gynaecol Obstet 2009;105:103-104. Copyright 2009, with permission from International Federation of Gynecology and Obstetrics.



NCCN Guidelines Version 3.2021

Vulvar Cancer (Squamous Cell Carcinoma)

NCCN Categories of Evidence and Consensus

Category 1	Based upon high-level evidence, there is uniform NCCN consensus that the intervention is appropriate.
Category 2A	Based upon lower-level evidence, there is uniform NCCN consensus that the intervention is appropriate.
Category 2B	Based upon lower-level evidence, there is NCCN consensus that the intervention is appropriate.
Category 3	Based upon any level of evidence, there is major NCCN disagreement that the intervention is appropriate.

All recommendations are category 2A unless otherwise indicated.

NCCN Categories of Preference

Preferred intervention	Interventions that are based on superior efficacy, safety, and evidence; and, when appropriate, affordability.
Other recommended intervention	Other interventions that may be somewhat less efficacious, more toxic, or based on less mature data; or significantly less affordable for similar outcomes.
Useful in certain circumstances	Other interventions that may be used for selected patient populations (defined with recommendation).

All recommendations are considered appropriate.



NCCN Guidelines Version 3.2021

Vulvar Cancer (Squamous Cell Carcinoma)

Discussion

This discussion corresponds to the NCCN Guidelines for Vulvar Cancer. Last updated: April 26, 2021.

Table of Contents

Overview	MS-2	Adjuvant Therapy	MS-10
Literature Search Criteria and Guidelines Update Methodology.....	MS-2	Adjuvant RT and Chemoradiation.....	MS-10
Diagnosis and Workup	MS-3	Panel Recommendations.....	MS-11
Prognostic Factors	MS-4	Surveillance.....	MS-12
Surgical Staging.....	MS-4	Treatment for Recurrent Disease	MS-13
Pathologic Evaluation.....	MS-4	Panel Recommendations.....	MS-13
Primary Tumor Resection.....	MS-5	Vulva-Confined Recurrence.....	MS-13
Lymph Node Evaluation	MS-5	Clinical Nodal or Distant Recurrence	MS-14
Panel Recommendations	MS-7	Systemic Therapy for Recurrent/Metastatic Disease	MS-14
Primary Treatment.....	MS-7	Gynecologic Survivorship	MS-16
Early-Stage Disease	MS-7	References	MS-17
Panel Recommendations	MS-8		
Locally Advanced Disease	MS-8		
Chemoradiation.....	MS-8		
Panel Recommendations	MS-9		
Metastasis Beyond the Pelvis	MS-10		
Panel Recommendations	MS-10		



NCCN Guidelines Version 3.2021

Vulvar Cancer (Squamous Cell Carcinoma)

Overview

In 2021, an estimated 6120 women will be diagnosed with vulvar cancer, and 1550 are expected to die from the disease.¹ Vulvar cancer accounts for 4% of gynecologic malignancies and median age of diagnosis is 68 years. Based on data from the SEER database, 5-year survival rates range from 86% for localized disease (stages I/II), to 53% for regional or locally advanced disease (stages III/IVA), and finally to 19% for patients with stage IVB (which includes patients with pelvic nodal disease).² Studies of the SEER database and the National Cancer Database (NCDB) have shown that treatment approaches/modalities vary considerably with sociodemographic factors such as race/ethnicity, age, and non-private insurance, particularly for individuals with advanced disease.^{3,4}

Ninety percent of vulvar cancers are of squamous cell carcinoma (SCC) histology.⁵ Risk factors for the development of vulvar neoplasia include increasing age, infection with human papillomavirus (HPV), cigarette smoking, inflammatory conditions affecting the vulva, and immunodeficiency. Most vulvar neoplasias are diagnosed at early stages.⁶ Rarer histologies exist and include melanoma, extramammary Paget's disease, Bartholin gland adenocarcinoma, verrucous carcinoma, basal cell carcinoma, and sarcoma.⁷

The International Society for the Study of Vulvovaginal Disease (ISVVD) has revised the terminology used to characterize vulvar lesions in recent years. In 2004, vulvar intraepithelial neoplasia (VIN) terminology was refined to include two types of lesions, usual-type VIN and differentiated VIN.⁸ Usual-type VIN was linked to persistent infection with carcinogenic strains of HPV, while differentiated VIN was commonly associated with vulvar dermatologic conditions such as lichen sclerosus. In 2015, the ISVVD updated the description to three classes of vulvar lesions: 1) low-grade squamous intraepithelial lesion (LSIL) due to flat condyloma or HPV

effect; 2) high-grade squamous intraepithelial lesions (HSIL, formerly considered usual-type VIN); and 3) differentiated VIN.⁹

Estimates of the percentage of vulvar cancers attributable to HPV infection range from conservative estimates of 30% to up to 69%, with a recent meta-analysis reporting an HPV prevalence of 39.7%.¹⁰⁻¹³ However, HPV infection is detected in 80% to 90% of HSIL. Historically, VIN has been diagnosed in younger women (median age 45–50 years) while vulvar cancers have been diagnosed in older women (median age 65–70 years).^{14,15} Because a large majority of HPV-related vulvar cancers are associated with HPV-16 and HPV-18 strains, vaccination with currently available HPV vaccines may reduce the burden of HPV-related vulvar cancers in the future.^{10,14}

By definition, the NCCN Guidelines cannot incorporate all possible clinical variations and are not intended to replace good clinical judgment or individualization of treatments. “Many exceptions to the rule” were discussed among the members of the Panel during the process of developing these guidelines. Recommendations in the NCCN Guidelines are category 2A unless otherwise noted.

Literature Search Criteria and Guidelines Update Methodology

Prior to the update of this version of the NCCN Guidelines® for Vulvar Cancer an electronic search of the PubMed database was performed to obtain key literature in vulvar cancer published since the previous Guidelines update, using the following search terms: vulvar cancer or carcinoma of the vulva. The PubMed database was chosen as it remains the most widely used resource for medical literature and indexes peer-reviewed biomedical literature.

The search results were narrowed by selecting studies in humans published in English. Results were confined to the following article types:



NCCN Guidelines Version 3.2021

Vulvar Cancer (Squamous Cell Carcinoma)

Clinical Trial, Phase II; Clinical Trial, Phase III; Clinical Trial, Phase IV; Guideline; Randomized Controlled Trial; Meta-Analysis; Systematic Reviews; and Validation Studies.

The data from key PubMed articles as well as articles from additional sources deemed as relevant to these guidelines as discussed by the Panel during the Guidelines update have been included in this version of the Discussion section. Recommendations for which high-level evidence is lacking are based on the Panel's review of lower-level evidence and expert opinion.

The complete details of the Development and Update of the NCCN Guidelines are available at www.NCCN.org.

Diagnosis and Workup

Currently, these guidelines focus on the diagnosis, evaluation, and treatment of vulvar SCC. At this time, the guidelines do not address the evaluation and management of rare, non-SCC histologies. For the purposes of this discussion, vulvar SCC will be generally referred to as “vulvar cancer.”

These guidelines utilize the FIGO (International Federation of Gynecology and Obstetrics) and American Joint Committee on Cancer (AJCC) TNM staging systems, which closely align for the staging of vulvar cancer. The FIGO system was updated in 2009;^{16,17} the 8th edition of the AJCC Cancer Staging Manual was released in 2017.¹⁸ In the updated FIGO system, major changes include the combination of former elements of stage I, II, and III; redefinition of stage III to include only those with positive inguinofemoral (IF) nodes (with subclassification based on the number/size of involved nodes); and shifting away from the previous focus on bilateral lymph node involvement. Patients with positive pelvic nodes, even without distant visceral metastasis, are considered stage IVB.¹⁶ The impact of this revised classification system has been examined.¹⁹⁻²¹

The presentation of vulvar cancer can be widely varied. The majority of vulvar cancers are located in the labia majora. Other possible sites include the labia minora, clitoris, mons pubis, or perineum. In patients with HPV-negative tumors, vulvar cancer often presents as a single mass or ulcer on the labia majora or minora. In HPV-positive tumors, multifocal lesions and concurrent cervical neoplasia are more common.^{14,15,22} Although many cases may be asymptomatic, pruritus and pain/irritation are common symptoms; vulvar bleeding or discharge may also occur. A majority of patients present with early-stage localized disease.²

Diagnosis is made through biopsy of all suspicious areas followed by pathologic review. The College of American Pathologists (CAP) protocol for vulvar carcinoma is a useful guide

(<https://cap.objects.frb.io/protocols/cp-femaleproductive-vulva-18protocol-4100.pdf>). This CAP protocol was revised in August 2018 and reflects recent updates in the AJCC/FIGO staging.

Workup includes history and physical examination, complete blood count (CBC), and liver and renal function tests. In addition to vulva examination, evaluation of the vagina and cervix (including cytologic smears) should be emphasized due to the multifocal nature of squamous cell intraepithelial neoplasia. CT, PET/CT, and MRI may be used to delineate the extent of tumor and/or for treatment planning.²³⁻²⁶ Examination-under-anesthesia (EUA) cystoscopy or proctoscopy should be considered as indicated. Appropriate patients should receive smoking cessation counseling, cervical HPV testing, and cytology testing. Consider HIV testing, especially in younger patients. Those with vulvar cancer and HIV should be referred to an HIV specialist; modifications to the recommended cancer treatments in these Guidelines should not be modified solely on the basis of HIV status. For elderly patients with vulvar cancer, also see the *NCCN Guidelines for Older Adult Oncology*.



NCCN Guidelines Version 3.2021

Vulvar Cancer (Squamous Cell Carcinoma)

Prognostic Factors

Historically, en bloc vulvectomy with wide margins was combined with complete IF lymphadenectomy to treat vulvar SCC. While effective in promoting survival, this approach was associated with serious short- and long-term morbidity (eg, wound complications, lymphedema, decreased sexual function, adverse impacts on body image). The emergence of data on important prognostic factors in vulvar cancer informed the evolution of surgical staging and primary treatment.²² Based on a retrospective review of 586 patients enrolled in Gynecologic Oncology Group (GOG) trials through 1984, independent predictors of survival included the presence and number of involved lymph nodes and primary tumor size.²⁷ Lymph node metastasis is considered the most important prognostic factor and determinant of treatment in vulvar cancer,^{28,29} and extracapsular extension has been linked to poorer prognosis.³⁰⁻³³ Factors that may be predictive of recurrence and/or survival include depth of invasion, pathologic margin distance, tumor thickness, and presence of lymphovascular space invasion (LVSI).^{14,27,34-39} However, these findings are primarily derived from retrospective analyses. A recent systematic review of the collective data on prognostic factors for local recurrence in vulvar cancer concluded that the weight of each individual prognostic variable remained equivocal when compared to one another.⁴⁰

Prognostic data have guided the shift towards more conservative primary tumor resection and regional lymph node management for early-stage disease.⁴¹ The preferred surgical approach evolved towards vulvar-sparing techniques with separate incisions for lymphadenectomy in patients who were clinically node negative.^{22,42} Current surgical approaches involve tailored primary tumor resection and lymph node evaluation based on individual patient characteristics.^{43,44} Data suggest that survival is not negatively impacted by less radical surgical approaches for early-stage cancers.⁴⁴

Surgical Staging

The AJCC and FIGO systems stage vulvar cancer according to extent of primary tumor (T), lymph node status (N), and distant metastasis (M). Clinical staging alone provides inadequate evaluation of lymph node involvement. Because lymph node metastasis is a key prognostic factor in vulvar cancer survival,^{28,44} these systems use a hybrid surgical and clinical/pathologic approach for more accurate evaluation of nodal status. Complete staging using the existing system requires primary tumor resection and full IF lymphadenectomy. However, common practice has increasingly included the use of sentinel lymph node (SLN) biopsy in lieu of complete lymphadenectomy, as well as diagnostic imaging to determine extent of disease.^{45,46}

Pathologic Evaluation

Surgicopathologic factors may be used to guide the extent of surgical staging and treatment decisions. Findings from pathologic assessment of the surgical specimen should be carefully documented, including procedure type (ie, partial or total vulvectomy) and depth of procedure (ie, superficial or skinning, simple, or radical). Important elements of primary tumor evaluation include tumor site; size (in multiple dimensions); number of tumor foci; histologic type and grade; depth of stromal invasion; surgical margin status; and the presence of LVSI. When resected, the number of lymph nodes with isolated tumor cells, micrometastases, and macrometastases should be recorded. If SLN mapping is performed, SLNs should undergo ultrastaging for detection of low-volume metastasis. Other important factors include tumor involvement of tissues/organs such as the vagina, urethra, anus, bladder mucosa, rectal mucosa, and pelvic bone. Mismatch repair (MMR), microsatellite instability (MSI), programmed death-ligand 1 (PD-L1), neurotrophic tyrosine receptor kinase (*NTRK*) gene fusion, and tumor mutational burden (TMB) testing may also be considered for treatment planning purposes in patients with recurrent, progressive, or metastatic disease.



NCCN Guidelines Version 3.2021

Vulvar Cancer (Squamous Cell Carcinoma)

Primary Tumor Resection

Depending on the size and extent of the primary tumor, simple partial/total vulvectomy or radical partial/total vulvectomy may be required. No prospective data are available to compare outcomes between these resection techniques; however, retrospective data suggest no difference in recurrence and/or survival.⁴⁷⁻⁴⁹ Both surgical approaches involve resection of approximately a 1- to 2-cm radial margin of grossly normal tissue and to the deep fascia or a minimum of a 1-cm deep margin.

Vulvar cancer is associated with significant risk of local recurrence, and data demonstrate tumor margin status to be a significant prognostic factor.^{34,37,50} A recent review identified 4-year recurrence-free rates of 82%, 63%, and 37% for patients with negative, close, and positive margins, respectively ($P = .005$). The highest risk of recurrence was associated with margins ≤ 5 mm.⁵¹ The goal of primary tumor resection is complete removal with negative pathologic margins. The definition of a negative margin continues to evolve and more recent data confirm the importance of a negative margin, but put less emphasis on the actual distance (in mm) of the margin. In the setting of close or positive tumor margins, re-resection to obtain negative margins or adjuvant local radiation therapy (RT) are options.^{34,52} In a recent study, tumor-free margins of at least 2 mm were associated with lower local recurrence risk.³⁸

The risk-benefit ratio and morbidity of each approach must be weighed and individualized for each patient. Evidence supports improved recurrence rates and survival with re-resection or adjuvant external beam RT (EBRT) to the primary site.⁵³ However, for close or positive margins involving the urethra, anus, or vagina, re-resection may incur significant morbidity and negatively impact patient quality of life. Re-resection may also be inappropriate for patients with close or positive margins who have

inguinal node involvement requiring adjuvant treatment with EBRT \pm concurrent chemotherapy.

Lymph Node Evaluation

Because lymph node status is the most important determinant of survival in vulvar cancer, careful evaluation and determination of nodal status is paramount. Lymph node resection is performed through a separate incision from the primary tumor and may entail ipsilateral or bilateral IF lymphadenectomy, or SLN biopsy in select cases. IF lymphadenectomy involves removal of superficial inguinal and deep femoral lymph nodes. Further emphasizing the importance of adequate IF lymph node (IFLN) evaluation and treatment at initial presentation, it has been widely reported that subsequent groin relapses are rarely amenable to successful secondary treatment.

Lymphadenectomy in patients with clinically negative groin nodes is informed by the size and location of the primary tumor. Because the risk of lymph node metastasis is less than 1% in patients with stage IA disease,⁴³ lymphadenectomy or SLN evaluation can be omitted in patients with stage IA (T1A and N0 tumors) primary disease with clinically negative groins. However, IF lymphadenectomy is recommended for patients with stage IB/II disease because the risk of nodal metastasis is estimated at greater than 8% for stage IB and even higher for stage II tumors.⁴³ For primary vulvar tumors less than 4 cm in diameter, located at least 2 cm from the vulvar midline, with clinically negative IFLNs, ipsilateral IF lymphadenectomy or SLN biopsy are appropriate.^{54,55} However, bilateral lymph node evaluation (IF lymphadenectomy or SLN biopsy, if indicated) is recommended for patients with primary tumors that are within 2 cm of, or crossing, the vulvar midline.⁵⁵ Lymphadenectomy for stage III/IV disease is individualized, and integrated with combined modality approaches.



NCCN Guidelines Version 3.2021

Vulvar Cancer (Squamous Cell Carcinoma)

SLN Biopsy

Reported rates of postoperative morbidity with unilateral or bilateral IF lymphadenectomy are high. An estimated 20% to 40% of patients have wound complications and 30% to 70% of patients experience lymphedema.^{56,57} Studies have begun to investigate whether complete IF lymphadenectomy could be safely avoided in patients who are determined to have a negative SLN. Several prospective multicenter trials have evaluated the feasibility, safety, validity, and risk of groin recurrences with SLN biopsy in early vulvar cancer.

The safety and accuracy of SLN assessment was examined in a multicenter observational study (GROINSS-VI) of 403 women with primary vulvar tumors less than 4 cm. IF lymphadenectomy was omitted if SLN(s) were negative on ultrastaging. With a median follow-up period of 35 months (24-month minimum), groin recurrences were detected among 6 of 259 patients (2.3%) with a unifocal primary tumor and negative SLN. The 3-year survival rate was 97%, leading to the conclusion that a negative SLN in this patient population provided sufficient management of the groin(s). Short- and long-term morbidity was reduced if the SLN only was removed compared with SLN removal followed by full groin lymphadenectomy.⁵⁸

In GOG 173, 452 women (with vulva-confined primary tumors 2–6 cm, at least 1-mm invasion, and clinically node negative) underwent SLN mapping and biopsy followed by IF lymphadenectomy. SLNs were identified in 418 women, and 132 women were node positive (including 11 false-negative nodes). SLN biopsy had a sensitivity of 91.7%, negative predictive value of 96.3%, and false-negative predictive value of 3.7% overall (2% for primary tumors <4 cm).⁵⁹

A subgroup analysis of the AGO-CaaRE-1 study compared outcomes of patients with tumors less than 4 cm who underwent radical groin lymphadenectomy or sentinel node lymphadenectomy with negative

findings for LN/SLN metastasis (n = 556). The radical groin lymphadenectomy cohort had larger tumor diameter (20 mm vs. 13 mm; $P < .001$) and greater depth of invasion (4.0 mm vs. 3.0 mm; $P = .002$), but isolated groin recurrence rates did not differ between the groups.

Multivariate analysis controlling for tumor characteristics such as diameter, depth of invasion, grade, and LVSI revealed no statistical differences in progression-free survival (PFS) and OS between the radical and sentinel node lymphadenectomy cohorts.⁶⁰

A recent systematic review and meta-analysis of the cumulative data on SLN biopsy revealed a per-groin detection rate of 87% when using dual tracers, and a false-negative rate of 6.4%. When comparing IF lymphadenectomy, superficial IF lymphadenectomy, and SLN biopsy, recurrences rates were 1.4%, 6.6%, and 3.4% in patients deemed node-negative by the surgical groin approach used, respectively.⁶¹

The GROINSS-VI observational study also evaluated patients with positive SLNs. Within the 135 of 403 patients who had positive SLNs (33%), investigators examined the relationship between size of SLN metastasis and risk of non-sentinel node disease among 115 patients who underwent IF lymphadenectomy following detection of positive sentinel nodes. Risk of non-SLN involvement increased steadily with the size of SLN metastasis, beginning at 4.2% with detection of isolated tumor cells and increasing to 62.5% with SLN metastases greater than 10 mm, suggesting no disease threshold below which further treatment of an SLN-positive groin could be safely omitted. Disease-specific survival (DSS) was worse among those with SLN metastases greater than 2 mm versus less than or equal to 2 mm (69.5% vs. 94.4%, $P = .001$).⁶² Patients undergoing SLN biopsy reported less treatment-related morbidity compared with those undergoing IF lymphadenectomy.⁶³

Long-term follow-up of the GROINSS-VI cohort compared outcomes of SLN-positive patients who underwent completion IF lymphadenectomy



NCCN Guidelines Version 3.2021

Vulvar Cancer (Squamous Cell Carcinoma)

with those of SLN-negative patients (no IF lymphadenectomy). At a median follow-up of 105 months, the data revealed a 5- and 10-year local vulvar recurrence rate of 24.6% and 36.4% for SLN-negative patients, and 33.2% and 46.4% for patients with a positive SLN ($P = .03$). Isolated groin recurrence rate was 2.5% for SLN-negative patients and 8.0% for SLN-positive patients at 5 years, despite more radical treatment in the latter group. DSS at 10 years was 91% in the SLN-negative group and 65% in the SLN-positive group ($P < .0001$), again attesting to the prognostic significance of groin nodal involvement.⁶⁴

The ongoing GROINSS-VII/GOG 270 study (NCT01500512) is comparing radiotherapy of the groin with groin node lymphadenectomy among patients with SLN metastases.

Panel Recommendations

For appropriate individuals, the Panel considers SLN mapping and biopsy of the IFLN basin a reasonable alternative approach to decrease postoperative morbidity while maintaining a low of groin recurrences with this surgical approach in vulvar cancer.^{58,59,62}

Candidates for SLN biopsy should have clinically/radiologically negative groin nodes, unifocal primary tumor less than 4 cm, and no history of previous vulvar surgery.^{61,62} Mapping and biopsy should be performed by a high-volume SLN surgeon using dual tracers (ie, radiocolloid and dye) to ensure the best detection rates.^{59,61} The Panel recommends complete IF lymphadenectomy if no ipsilateral SLN is detected. If the ipsilateral SLN is positive, completion lymphadenectomy or treatment of the affected groin is warranted. The contralateral groin should be evaluated surgically and/or treated with EBRT. In select cases of a single, small volume, unilateral, positive inguinal node with a well-lateralized primary tumor diameter less than or equal to 2 cm and depth of invasion less than or equal to 5 mm and with a clinically negative contralateral groin examination, a contralateral groin lymphadenectomy or radiation may be omitted.⁶⁵

Primary Treatment

For the purposes of primary treatment, these guidelines provide treatment recommendations by clinical stage, separating patients into those with early-stage (stage I; smaller stage II tumors), locally advanced (larger stage II tumors; stage III/IVA/IVB with pelvic-confined disease), and distant metastatic disease (extrapelvic stage IVB). Patients with early-stage disease include those with T1 or smaller T2 primary tumors; smaller T2 primary tumors are classified as less than or equal to 4 cm with no/minimal involvement of the urethra, vagina, or anus. Patients with locally advanced disease include those with larger T2 (greater than 4 cm and/or involvement of the urethra, vagina, or anus) or T3 primary tumors for whom visceral-sparing primary surgery is not indicated. Patients with distant metastatic disease may fall within any “T” or “N” classification.

Early-Stage Disease

After careful clinical evaluation and staging, the standard primary treatment of early-stage vulvar SCC is conservative, individualized tumor excision with IFLN evaluation.^{42,48,66-69} Clinicians should strive for primary tumor resection with oncologically appropriate margins of 1 to 2 cm if feasible.^{34,37,50,52} See *Primary Tumor Resection* and *Lymph Node Evaluation* in this discussion. Although there are no prospective data comparing radical local incision to radical vulvectomy, existing data from retrospective analyses do not demonstrate a difference in recurrence or survival outcomes.^{48,49}

Surgical dissection and RT have been evaluated for treatment of the groin in early-stage disease. Limited data suggest that primary groin radiation results in less morbidity than surgical dissection.⁷⁰ However, surgical treatment of the groin (followed by tailored adjuvant RT if LN-positive) has been associated with lower groin recurrence rates and remains the preferred approach.⁷¹ Primary radiation may have some benefit for those unable to undergo surgery.^{72,73}



NCCN Guidelines Version 3.2021

Vulvar Cancer (Squamous Cell Carcinoma)

Panel Recommendations

For T1 tumors with less than or equal to 1 mm depth of invasion (pT1a), the Panel recommends simple partial vulvectomy; IFLN evaluation is not required due to the low risk of lymph node metastasis in these patients.^{43,67,74-77} Patients should be observed following resection. If surgical pathology reveals greater than 1-mm invasion, additional surgery may be indicated.

In treatment for patients with T1b (>1-mm invasion) or smaller T2 tumors, primary treatment is dictated by tumor location. Patients with lateralized lesions located greater than or equal to 2 cm from the vulvar midline should undergo radical partial vulvectomy accompanied by ipsilateral IF lymph node evaluation.^{54,55,74} IF node evaluation can be performed through SLN biopsy or ipsilateral IF lymphadenectomy; the latter should be performed if no SLN(s) is/are detected. Adjuvant therapy is informed by primary tumor risk factors and nodal surgical pathology. Patients with anterior or posterior central vulvar lesions should undergo radical partial vulvectomy accompanied by bilateral IF node evaluation consisting of SLN biopsy or bilateral IF lymphadenectomy.^{48,55,74} IF lymphadenectomy is required on side(s) for which sentinel nodes are not detected. Adjuvant therapy is informed by primary tumor risk factors and nodal surgical pathology.

Locally Advanced Disease

Historically, locally advanced vulvar cancers were treated primarily with radical surgeries such as en bloc radical vulvectomy with bilateral IF lymphadenectomy or pelvic exenteration. These surgeries resulted in some cures, but also led to significant postoperative complications, loss of function, and reduced quality of life.^{22,78-80} Additionally, complete resection of locally advanced disease may be complicated by tumor fixed to vital organs or vessels, rendering the disease unresectable.⁸¹ A shift to multimodality treatment was explored to improve organ preservation and

reduce surgical treatment morbidity.⁸² Preoperative RT was shown in some earlier studies to result in tumor debulking and reduce the extent of surgery required for locally advanced disease.^{81,83-86} Subsequently, borrowing on experience from advanced cervical and anal cancers, chemotherapy typically has been added as a “radiosensitizer” when radiation is delivered in patients with advanced disease.

Chemoradiation

Research directly comparing treatment approaches for locally advanced vulvar cancers is limited. Data from small patient cohorts have shown a generally high response rate to chemoradiation among most patients with stage III/IVA disease, as well as the feasibility of resection for residual disease following chemoradiation. Following chemoradiation, at least partial tumor responses were noted among a wide majority of the patients in these cohorts,⁸⁷⁻⁹¹ with several studies revealing complete tumor responses among more than 60% of the cohort.⁹²⁻⁹⁶

Primary chemoradiation may confer a survival benefit over primary RT in vulvar cancer. Overall survival (OS) after primary chemoradiation was superior to OS following primary RT in a series of 54 patients with locally advanced disease.⁹⁷ A similar survival benefit was recently reported in a study using NCDB data from patients who were not candidates for surgery, comparing cohorts who received primary chemoradiation (n = 999) or primary RT (n = 353). The chemoradiation cohort was younger with more advanced FIGO staging. Chemoradiation was associated with significantly higher 5-year OS than primary RT (49.9% vs. 27.4%, $P < 0.001$) and multivariate analysis revealed a reduced hazard of death (hazard ratio [HR], 0.76; 95% CI, 0.63–0.91; $P = .003$).⁹⁸

In the GOG 101 study, preoperative chemoradiation was examined in 73 patients with stage III/IV disease.⁸⁹ The study investigated whether chemoradiation allowed for less radical surgery in patients with T3 tumors and avoidance of pelvic exenteration in patients with T4 tumors. Only 3%



NCCN Guidelines Version 3.2021

Vulvar Cancer (Squamous Cell Carcinoma)

of patients (2/71) had residual unresectable disease following chemoradiation, and preservation of urinary and/or gastrointestinal continence was possible in 96% of patients (68/71).

Two prospective studies from the GOG more closely examined the benefits of surgery after chemoradiation for patients with locally advanced disease. GOG 101 examined 46 patients with vulvar SCC and N2/N3 nodal involvement.⁹⁹ Subsequent surgery was performed on 38 patients with resectable disease after chemoradiation with cisplatin/5-fluorouracil (5-FU). Local control of nodal disease was achieved in 36/37 patients and for the primary tumor in 29/38 patients. More recently, the GOG 205 study examined the feasibility of surgery after chemoradiation with cisplatin in 58 patients with T3/T4 tumors that were initially unresectable by radical vulvectomy.¹⁰⁰ Complete clinical response was noted in 64% of patients (37/58), with pathologic complete response (pCR) in 78% (29/34) of patients undergoing surgical biopsy. Of the total population, approximately 50% achieved pCR after chemoradiation therapy. The high pCR rates have led many to believe that surgery can be avoided in patients with locally advanced tumors who achieve clinical complete responses.

An analysis of NCDB data (2004–2012) compared outcomes of 2046 women with locally advanced vulvar cancer that received primary radiation (RT or chemoradiation), or preoperative radiation (RT or chemoradiation) followed by surgery. Patients who underwent surgery after RT/chemoradiation had longer OS than patients who underwent primary RT/chemoradiation without subsequent resection (57.1% vs. 41.7% at 3 years, respectively; $P < .001$). However, multivariate analysis revealed a radiation dose-dependent effect, and survival was not significantly worse if the dose exceeded 55 Gy. With sufficient RT dose and concurrent chemotherapy, the primary RT cohort had comparable survival to the group who underwent lower-dose preoperative RT/chemoradiation followed by surgery.¹⁰¹

A 2011 Cochrane database review of the existing randomized controlled trial data on 141 women with locally advanced vulvar SCC revealed no difference in OS when comparing primary surgery to primary or neoadjuvant chemoradiation.¹⁰² However, the data did not allow for broad conclusions to be drawn regarding treatment-related quality of life and adverse events. An earlier Cochrane database review of five non-randomized trials suggested that patients with unresectable primary disease and those requiring exenteration may benefit from neoadjuvant chemoradiation if disease was rendered resectable or requiring less radical surgery.¹⁰³

The combination regimen used for radiosensitization was most commonly cisplatin/fluorouracil,^{89,90,92,94,95} but also included fluorouracil/mitomycin C^{288,91,96} or single-agent therapy.^{93,100} The selection of radiosensitizing chemotherapy is often based on extrapolation of findings from cervical, anal, or head and neck cancer.

Panel Recommendations

Patients with larger T2 (>4 cm and/or involvement of the urethra, vagina, or anus) or T3 tumors should undergo radiologic imaging (if not previously performed) to examine potential nodal involvement. The Panel recommends that all patients with locally advanced disease receive EBRT with concurrent chemotherapy. IF lymphadenectomy may be used to assess nodal metastasis and inform RT treatment planning.

If IF lymphadenectomy is not performed, or if positive IFLNs are found during the procedure, EBRT coverage should include the primary tumor, groin, and pelvic nodes. If no positive nodes are detected following IF lymphadenectomy, EBRT with concurrent chemotherapy should be provided with RT coverage of the primary tumor, with or without selective coverage of IF lymph nodes.



NCCN Guidelines Version 3.2021

Vulvar Cancer (Squamous Cell Carcinoma)

Patients with radiographically positive nodes (including those with pelvis-confined metastases) should be evaluated for IF lymphadenectomy. If IF lymphadenectomy is not performed, fine-needle aspiration (FNA) of enlarged lymph nodes can be considered. Patients should receive EBRT and concurrent chemotherapy; EBRT coverage should include the primary tumor, IF nodes, and pelvic nodes. Selective IFLN RT coverage can be considered if lymphadenectomy reveals no positive lymph nodes.

Agents recommended by the Panel for chemoradiation include cisplatin (preferred), fluorouracil/cisplatin, or fluorouracil/mitomycin- $C^{2,104,105}$

Metastasis Beyond the Pelvis

Data on systemic treatments for vulvar SCC with distant metastasis are extremely limited.¹⁰⁶⁻¹⁰⁸ Treatment regimens are often extrapolated from agents that are active against advanced cervical cancer. See the section on *Systemic Therapy for Recurrent/Metastatic Disease* in this discussion for information about specific regimens.

Panel Recommendations

Primary treatment options for extra-pelvic metastatic disease include EBRT for control of locoregional disease and symptom palliation, and/or systemic therapy. Best supportive care is also an alternative in this setting. Preferred regimens recommended by the Panel for treating advanced or recurrent/metastatic disease include single-agent cisplatin and carboplatin, cisplatin/paclitaxel, carboplatin/paclitaxel, and cisplatin/paclitaxel/bevacizumab. Other recommended regimens include single-agent paclitaxel or erlotinib (category 2B for erlotinib), cisplatin/vinorelbine, cisplatin/gemcitabine (category 2B), and carboplatin/paclitaxel/bevacizumab (category 2B).

Adjuvant Therapy

Due to the rarity of vulvar cancer, especially advanced disease, prospective randomized trials on adjuvant therapy are extremely limited. Much of the common adjuvant treatment approaches have been drawn from studies describing heterogenous, often-individualized treatment approaches, or extrapolated from effective adjuvant therapies for cervical and anal cancers.

Adjuvant RT and Chemoradiation

Although it is commonly accepted that lymph node involvement is a critical prognostic factor in vulvar SCC, the optimal patient selection criteria and adjuvant therapy regimens to address nodal disease continue to be determined.¹⁰⁹ As previously emphasized, it is crucial to prevent metachronous groin relapses, as these often prove refractory to secondary management and are often ultimately fatal.

Early randomized trial data on adjuvant RT were published from GOG 37, which enrolled 114 patients with IF node-positive vulvar cancer after radical vulvectomy and bilateral IF lymphadenectomy.^{110,111} Patients were randomized to receive pelvic lymphadenectomy or adjuvant RT to the groin/pelvis. Two- and 6-year survival were superior in the adjuvant RT group, but the most significant survival benefits were observed among patients with greater than or equal to 2 positive IF nodes or those with fixed ulcerative IF nodes. Long-term follow-up (median = 74 months) revealed higher rates of disease-related death for the group receiving pelvic node resection compared with pelvic/groin RT (51% vs. 29%; HR, 0.49; $P = .015$).¹¹¹

A recent study using SEER-Medicare-linked data examined outcomes for 444 elderly patients (aged ≥ 66 years; median age 78) with node-positive vulvar cancer who underwent adjuvant RT. Compared to surgery alone, better disease outcomes were associated with adjuvant RT when the



NCCN Guidelines Version 3.2021

Vulvar Cancer (Squamous Cell Carcinoma)

following metrics were met: completion of at least 20 fractions, treatment duration of less than 8 weeks, and less than 1 week of intra-treatment break. However, only half of the cohort that received RT met these treatment benchmarks.¹¹²

There are conflicting data on the benefit of adjuvant RT in patients with a single positive lymph node. Some studies in patients with a single positive lymph node have reported no benefit of adjuvant RT in this setting.^{113,114} However, examination of SEER data from 208 patients with stage III, single node-positive vulvar SCC revealed significant improvements in 5-year DSS with the addition of adjuvant RT compared with those receiving no RT.¹¹⁵ The survival benefit was more pronounced among patients who underwent less extensive lymphadenectomy (≤ 12 nodes excised).

In a case series of 157 patients, disease-free survival (DFS) at 2 years was 88% in node-negative patients, but 60%, 43%, and 29% in patients with 1, 2, and greater than 2 positive nodes. The number of involved nodes negatively impacted prognosis in patients receiving no adjuvant RT, but among patients receiving adjuvant RT to the groin/pelvis, the number of metastatic nodes did not harm prognosis.¹¹⁶

The large, multicenter, retrospective AGO-CaRE-1 study reported significant survival benefits in node-positive patients receiving adjuvant RT or chemoradiation (3-year PFS of 39.6% vs. 25.9%, $P = .004$; 3-year OS of 57.7% vs. 51.4%, $P = .17$).¹¹⁴ RT coverage most commonly included the groin and pelvis \pm coverage of the vulva, with a smaller subset receiving coverage to the groin \pm vulvar coverage. Again, the benefits of adjuvant RT were most clear for patients with greater than or equal to 2 positive lymph nodes.

Recent examination of data from the NCDB supported the addition of chemotherapy to RT in the adjuvant setting. Among 1797 patients with node-positive vulvar cancer, 26.3% received adjuvant chemotherapy in

addition to RT after primary surgery. Adjuvant chemotherapy increased survival time and reduced mortality risk (44 months vs. 29.7 months; HR, 0.62; 95% CI, 0.48–0.79; $P < .001$).¹¹⁷ Based on SEER data, outcomes of adjuvant RT were examined in 519 patients aged 66 years and older who received primary surgery for node-positive vulvar cancer. Adjuvant RT was associated with improved OS over surgery alone in this cohort of older women (HR, 0.71; 95% CI, 0.57–0.88; $P = .002$) along with a trend towards improved cause-specific survival (CSS) (HR, 0.79; 95% CI, 0.59–1.05; $P = .11$).¹¹⁸ Parameters for delivery of RT were important among this cohort; 3-year OS and CSS were significantly improved in patients who received greater than or equal to 20 fractions (3-year OS: 34% vs. 26%, $P = .008$; 3-year CSS: 48% vs. 37%, $P = .03$).

Research has also examined the role of adjuvant RT to the primary tumor site. Studies have indicated that isolated primary site recurrences may be addressed effectively by subsequent surgery, or that late recurrences may actually represent secondary tumors. The benefit of adjuvant RT to the vulva in patients with close/positive surgical margins has also been investigated.¹¹⁹ Among patients with close/positive surgical margins at the primary site, 5-year OS was significantly improved by the addition of adjuvant RT to the primary site (67.6% vs. 29%; HR, 0.36; $P = .038$). Patients receiving adjuvant RT for close/positive margins had a similar 5-year OS to those with negative margins. A retrospective study examined the association of RT dose with vulvar recurrence, revealing lower risk of recurrence in patients receiving doses of greater than or equal to 56 Gy compared with those receiving less than or equal to 50.4 Gy.⁵¹

Panel Recommendations

For patients with early-stage disease (T1) and a depth of invasion less than or equal to 1 mm (pT1a), observation is appropriate following primary surgery if negative margins are present and the patient does not have any primary risk factors. Risk factors that may require adjuvant EBRT to the



NCCN Guidelines Version 3.2021

Vulvar Cancer (Squamous Cell Carcinoma)

primary site are close tumor margins, LVSI, tumor size, depth of invasion, and pattern of invasion (spray or diffuse). Those with positive margins should undergo re-excision, or if unresectable, adjuvant EBRT. After re-excision, the Panel recommends that patients with negative margins undergo observation or risk-factor-dependent EBRT; those with continued positive margins after re-excision should all undergo EBRT.¹¹⁹

For patients with T1b and T2 disease, surgical evaluation of the groin is indicated in addition to primary site surgery. Nodal status is an important determinant of adjuvant therapy recommendations. For patients with a negative SLN or negative IFLNs, observation can be considered.^{58,120-123} Adjuvant therapy is warranted if the SLN or IFLNs contain metastases. Adjuvant therapy for patients with SLN involvement includes: 1) RT ± concurrent chemotherapy; or 2) completion IF lymphadenectomy followed by EBRT ± concurrent chemotherapy. Adjuvant therapy for patients who have positive IFLNs detected during IF lymphadenectomy includes EBRT (category 1) ± concurrent chemotherapy. Chemoradiation is strongly recommended for patients with two or more positive IFLNs or a single IFLN with greater than 2-mm metastasis.^{110,114}

For patients with locally advanced disease, adjuvant therapy decisions should be made based on clinical evaluation of treatment response after EBRT with concurrent chemotherapy (potentially preceded by IF lymphadenectomy). These guidelines provide adjuvant therapy recommendations based on whether patients are clinically negative or positive for residual tumor at the primary site and in the groin. Patients with no clinical evidence of residual tumor after EBRT with concurrent chemotherapy should undergo surveillance. Biopsy of the tumor bed can also be considered to confirm pCR. Patients with residual tumor should be considered for resection. In the case of positive margins on resection, providers should consider additional surgery, additional EBRT, and/or

systemic therapy, or best supportive care. For unresectable residual disease, providers should consider additional EBRT and/or systemic therapy, or best supportive care.

Surveillance

Most recurrences of vulvar cancer occur within the first one to two years, although recurrences beyond 5 years have been observed in a significant subset of patients.^{124,125} Accordingly, long-term follow-up is indicated. Definitive data on an optimal surveillance strategy are lacking.¹²⁶ However, the Panel concurs with the updated Society of Gynecologic Oncology (SGO) recommendations for post-treatment surveillance.¹²⁷

The recommended surveillance is based on the patient's risk for recurrence and personal preferences. History and physical examination are recommended every 3 to 6 months for 2 years, every 6 to 12 months for another 3 to 5 years, and then annually (see *Surveillance* in the NCCN Guidelines for Vulvar Cancer). Patients with high-risk disease can be assessed more frequently (eg, every 3 months for the first 2 years) than patients with low-risk disease (eg, every 6 months).

Annual cervical/vaginal cytology tests, which may include HPV testing, can be considered as indicated for detection of lower genital tract dysplasia, although its value in detecting recurrent cancers is limited and the likelihood of detecting asymptomatic recurrence is low. Imaging (ie, chest/abdomen/pelvis CT, neck/chest/abdomen/pelvis/groin PET/CT, pelvic MRI) and laboratory testing (ie, CBC, blood urea nitrogen [BUN], creatinine) are recommended as indicated by suspicious examination findings or symptoms of recurrence.

Patient education regarding symptoms suggestive of recurrence or vulvar dystrophy is recommended, as well as periodic self-examination. Patients should also be counseled on healthy lifestyle, obesity, nutrition, exercise, and sexual health (including vaginal dilator use and



NCCN Guidelines Version 3.2021

Vulvar Cancer (Squamous Cell Carcinoma)

lubricants/moisturizers). For information on these and other issues related to survivorship (ie, pain/neuropathy, fear of recurrence, and depression), see the *Gynecologic Survivorship* section at the end of this document and the NCCN Guidelines for Survivorship. Smoking cessation and abstinence should be encouraged; see the NCCN Guidelines for Smoking Cessation (www.NCCN.org).

If persistent or recurrent disease is suspected, patients should be evaluated using additional imaging studies and biopsy as outlined in the next section.

Treatment for Recurrent Disease

A multicenter case series evaluated the rate and patterns of recurrence among 502 patients, 187 (37%) of who developed a recurrent vulvar SCC. Just over half of recurrences were vulvar (53.4%), followed by inguinal (18.7%), multi-site (14.2%), distant (7.9%), and pelvic (5.7%). Survival rates at 5 years were 60% for vulvar recurrence, 27% for inguinal/pelvic, 15% for distant sites, and 14% for multiple sites.²⁹ While localized vulvar recurrences can be successfully addressed with subsequent surgery, some studies have suggested higher risk of cancer-related death.

Given the rarity of primary vulvar cancer, data for treating recurrences are even scarcer and no clear standard of care exists.¹²⁸ Treatment approach and patient outcomes depend on the site and extent of recurrent disease.^{128,129} Isolated local recurrences can often be treated successfully with radical local excision,^{29,125,130} and RT ± chemotherapy provided some degree of DFS in several studies.^{85,86} A retrospective review of patients with locoregional recurrences were managed with chemoradiation, neoadjuvant chemotherapy, or RT alone. Five-year DFS and OS were around 20%; however, those with single-site recurrence and lesions less than or equal to 3 cm who received RT dose at or above 64.8 Gy remained disease-free at 5 years.¹³¹ Conversely, another series noted

decline in survival with the presence of nodal metastases, tumors greater than 3 cm, or high-grade lesions.¹³² For central/large recurrences, pelvic exenteration has been shown to prolong survival when performed on carefully selected patients.^{78,79,133} Regardless of treatment approach, prognosis for nodal recurrences was very poor.^{125,130,132,134,135}

Panel Recommendations

If recurrence is suspected, the Panel recommends workup for metastatic disease with imaging studies to include chest/abdominal/pelvis CT or neck/chest/abdomen/pelvis/groin PET/CT. Biopsy can be considered to confirm local and/or distant metastasis. Treatment recommendations for recurrent disease are outlined according to site of recurrence and previous therapies received.

Vulva-Confined Recurrence

If recurrence is clinically limited to the vulva with clinically negative nodes, and the patient did not receive prior RT, the Panel recommends surgical and RT treatment pathways. Surgical recommendations include partial or total radical vulvectomy ± unilateral or bilateral IF lymphadenectomy. Pelvic exenteration can be considered for select cases with a central recurrence. Additional therapy is indicated by margin status and nodal status. Observation or EBRT is appropriate for negative margins and nodes. In patients with positive margins but no evidence of nodal involvement, options include re-excision or EBRT ± brachytherapy and/or concurrent chemotherapy (category 2B for chemotherapy). EBRT ± concurrent chemotherapy is recommended for patients with negative surgical margins but surgically positive IFLNs. In patients with both positive margins and surgically positive IFLNs, the Panel recommends EBRT ± brachytherapy, concurrent chemotherapy, and/or re-excision as needed/appropriate.



NCCN Guidelines Version 3.2021

Vulvar Cancer (Squamous Cell Carcinoma)

Nonsurgical therapy for recurrence includes EBRT ± brachytherapy and/or concurrent chemotherapy. Resection can be considered for patients with gross residual tumor. When feasible, partial or total radical vulvectomy is also indicated for patients with vulva-confined recurrence who were previously irradiated. After treatment for recurrence, patients should undergo surveillance.

Clinical Nodal or Distant Recurrence

For patients with multiple pelvic nodes, distant metastasis, or prior pelvic EBRT, the Panel recommends systemic therapy and/or selective EBRT (if feasible) or palliative/best supportive care. Resection followed by systemic therapy can be considered for select cases of isolated IF/pelvic recurrence that were previously irradiated.

If recurrence is limited to IF/pelvic LNs and no prior RT was given, then consider resection of clinically enlarged and suspicious nodes followed by EBRT ± concurrent chemotherapy. For unresectable nodes, EBRT ± concurrent chemotherapy is appropriate. All patients should undergo surveillance following treatment for recurrence.

Systemic Therapy for Recurrent/Metastatic Disease

No standard systemic therapy regimens exist for treating advanced or recurrent/metastatic disease. Several reports provide anecdotal evidence for various regimens, at times extrapolating from regimens with known activity in advanced cervical and anal cancers and other SCCs. See the review articles by Reade et al and Mahner et al for an overview of systemic therapies that have been utilized to treat vulvar SCC.^{104,128} Preferred regimens recommended by the Panel for treating advanced, recurrent/metastatic disease include single-agent cisplatin and carboplatin, cisplatin/paclitaxel, carboplatin/paclitaxel, and cisplatin/paclitaxel/bevacizumab. Other recommended regimens include single-agent paclitaxel or erlotinib (category 2B for erlotinib),

cisplatin/vinorelbine, cisplatin/gemcitabine (category 2B), or carboplatin/paclitaxel/bevacizumab (category 2B).

Cisplatin (preferred) is a commonly employed radiosensitizing agent in locally advanced vulvar cancer, and is recommended for single-agent or combination chemotherapy for treatment of metastatic disease.^{81,136} Cisplatin/paclitaxel and cisplatin/paclitaxel/bevacizumab are also preferred regimens based on extrapolation of randomized phase III trial data in advanced or recurrent/metastatic cervical cancer.^{137,138}

Carboplatin is an alternative platinum agent active in metastatic cervical cancer that can be used as a single agent (preferred) or in combination. A small series in 6 patients with advanced or recurrent/metastatic vulvar cancer noted limited clinical benefit of the combination regimen;¹⁰⁶ however, it has been included in these guidelines based on data from patients with advanced or recurrent/metastatic cervical cancer that suggest non-inferiority to cisplatin.^{139,140} Carboplatin-based combination regimens recommended in the guidelines include carboplatin/paclitaxel (preferred) and carboplatin/paclitaxel/bevacizumab (category 2B).

Single-agent paclitaxel was modestly active in a phase II trial of 31 women with advanced, recurrent/metastatic vulvar cancer, generating a response rate of 14% and PFS of 2.6 months.¹⁰⁷ Cisplatin/vinorelbine was studied in a small case series of patients with recurrent disease, producing a 40% response rate, 10-month PFS, and 19-month OS.¹⁴¹ Erlotinib was studied in a phase II trial that included a cohort of women with metastatic disease. Short-duration responses were observed, with partial responses and stable disease noted in 27.5% and 40% of enrolled patients, respectively.¹⁰⁸ Cisplatin/gemcitabine is also included as a category 2B option extrapolating from cervical cancer data; however, findings from case reports have been mixed.^{142,143}



NCCN Guidelines Version 3.2021

Vulvar Cancer (Squamous Cell Carcinoma)

Biomarker-directed systemic therapies are an emerging class of treatments that may be useful in patients with advanced or recurrent/metastatic cancer. Monoclonal antibodies that function as programmed cell death protein 1 (PD-1) inhibitors are one such example of these treatments. PD-1 functions as an immune checkpoint protein that promotes antitumor T cell activity. Many tumors, including vulvar cancer, are known to overexpress PD-L1, which disrupts PD-1 function. Thus, blocking PD-L1/PD-1 binding restores T-cell-mediated antitumor activity.¹⁴⁴⁻¹⁴⁶ An estimated 10% to 50% of vulvar cancers express PD-L1.^{147,148}

Pembrolizumab is one such PD-1 inhibitor that may be effective in patients with vulvar cancer. The single-arm phase II KEYNOTE-158 basket trial ([NCT02628067](#)) measured response to pembrolizumab monotherapy in patients with advanced solid tumors that progressed after standard-of-care systemic therapy. A conference abstract by Chung et al reported data from a subset of 98 patients in the study with advanced cervical cancer who were treated with pembrolizumab; approximately 83% of these patients had PD-L1–positive tumors. The overall response rate (ORR) was 13.3%; all 13 responses were in patients with PD-L1–positive tumors.¹⁴⁹ Based on these data, FDA approved pembrolizumab for treating recurrent or metastatic cervical cancer with disease progression on or after chemotherapy whose tumors express PD-L1 (CPS ≥1) as determined by an FDA-approved test.¹⁵⁰ A subsequent publication by Chung et al confirmed the conference abstract data.¹⁵¹ While no data have yet been reported for patients with PD-L1–positive vulvar cancer who were enrolled in the KEYNOTE-158 trial, the Panel felt that the drug was likely to be effective in this patient population. Thus, they added pembrolizumab as a recommended second-line, useful in certain circumstances option for PD-L1–positive advanced or recurrent/metastatic vulvar cancer.

Monoclonal antibodies targeting the PD-1 pathway may also be effective in tumors that have high TMB (TMB-H) or are deficient in MMR (dMMR)/have high levels of MSI (MSI-H). Of the 71 patients in the KEYNOTE-158 trial with advanced vulvar cancer, 12 had TMB-H tumors. The ORR for TMB-H vulvar cancer was approximately 17%, while the ORR for non-TMB-H disease was 3.4%.¹⁵² The KEYNOTE-158 study authors also analyzed pembrolizumab response in 233 enrolled patients with non-colorectal MSI-H/dMMR tumors, one of which had vulvar cancer. Overall ORR for the entire cohort was 34.3%. Median PFS was 4.1 months and median OS was 23.5 months.¹⁵³ Based on these data, FDA expanded pembrolizumab's approval for treatment of TMB-H and MSI-H/dMMR tumors that progressed after prior therapy, regardless of tumor type.^{154,155} Based on these additional data/FDA approvals, the Panel also recommends pembrolizumab as a second-line, useful in certain circumstances option for patients with advanced or recurrent/metastatic vulvar cancer whose tumors are MSI-H/dMMR or TMB-H.

Nivolumab is another PD-1 inhibitor shown to have some efficacy in certain patients with vulvar cancer. The single-arm phase I/II CheckMate 358 trial ([NCT02488759](#)) measured response to nivolumab monotherapy in a small cohort of 5 patients with recurrent or metastatic vaginal or vulvar cancer who were HPV-positive or had an unknown HPV status. The 12- and 18-month OS rates for the combined cohort were 40% and 20%, respectively; 6-month PFS was 40%.¹⁵⁶ Based on these data, the Panel added nivolumab as a second-line, useful in certain circumstances option for HPV-related advanced or recurrent/metastatic vulvar cancer.

NTRK gene fusions lead to constitutively active tropomyosin receptor kinases (TRKs), which in turn promote development and progression of cancer. Approximately 0.3% of solid tumors express *NTRK* gene fusions, although expression varies widely by cancer type.¹⁵⁷ Entrectinib and larotrectinib are broadly active TRK inhibitors that are effective in patients



NCCN Guidelines Version 3.2021

Vulvar Cancer (Squamous Cell Carcinoma)

with a variety of advanced or metastatic *NTRK* fusion-positive solid tumors.¹⁵⁷⁻¹⁵⁹ Although clinical trials of entrectinib and larotrectinib did not enroll any patients with *NTRK* fusion-positive vulvar cancer, the Panel felt that these regimens could potentially be useful as a second-line therapy in these patients, and thus added both as category 2B, useful in certain circumstances recommendations.

Gynecologic Survivorship

Treatment for gynecologic cancer typically involves surgery, chemotherapy, hormone therapy, RT, and/or immunotherapy, which may cause acute, short-term, and long-term toxicities. Surgical approaches may be extensive and cause adhesions to form, which in turn may cause pain and contribute to the development of small bowel obstruction, urinary or gastrointestinal complications (eg, incontinence, diarrhea), pelvic floor dysfunction (manifested by a variety of urinary, bowel, and/or sexual effects), and lymphedema.^{160,161} Chemotherapy agents vary, though commonly used regimens may pose a significant risk of neurotoxicity, cardiac toxicity, cognitive dysfunction, and the development of hematologic cancers.¹⁶² Long-term estrogen deprivation may cause symptoms such as hot flashes, vaginal dryness, and bone loss. RT may cause long-term complications (eg, fibrosis, stenosis, vulvovaginal atrophy)^{163,164} and may predispose patients to subsequent cancers of the skin, subcutaneous tissue, and/or underlying organs that are proximal to the radiation field.¹⁶⁵ Use of immunotherapy agents in gynecologic cancers is emerging, and to date, long-term effects of these treatments are unknown.^{166,167}

Following completion of treatment, all gynecologic cancer survivors should receive regular general medical care that focuses on managing chronic diseases (eg, depression, diabetes, hypertension), monitoring cardiovascular risk factors, receiving recommended vaccinations, and encouraging adoption of a healthy lifestyle (eg, promoting exercise,

smoking cessation).^{168,169} In order to assess the late and long-term effects of gynecologic cancers, clinicians should comprehensively document the patient's history, including prior treatment history, and conduct a thorough physical examination followed by necessary imaging and/or laboratory testing.¹⁶⁹ As most treatments for gynecologic cancers will cause sexual dysfunction, early menopause, and infertility, special attention to the resultant medical and psychosocial implications is needed. All women, whether sexually active or not, should be asked about genitourinary symptoms, including vulvovaginal dryness.¹⁷⁰ Post-radiation use of vaginal dilators and moisturizers is recommended.^{163,171} Psychosocial effects may include psychological (eg, depression, anxiety, fear of recurrence, altered body image), financial (eg, return to work, insurance concerns), and interpersonal (eg, relationships, sexuality, intimacy).¹⁶⁹ Patients should be referred to appropriate specialty providers (eg, physical therapy, pelvic floor therapy, sexual therapy, psychotherapy) as needed, based on prior treatment history and assessed risk of developing late effects and/or existing concerns.

Communication and coordination with all clinicians involved in the care of survivors, including primary care clinicians, is critical.^{169,172} Providing survivors with a summary of their treatment and recommendations for follow-up is also recommended. To this end, the SGO has developed templates for gynecologic cancer-specific Survivorship Care Plans to aid survivors and their clinicians in summarizing cancer history, treatments received, possible side effects, and recommended follow-up.¹⁷³



NCCN Guidelines Version 3.2021

Vulvar Cancer (Squamous Cell Carcinoma)

References

1. Siegel RL, Miller KD, Jemal A. Cancer statistics, 2020. *CA Cancer J Clin* 2020;70:7-30. Available at: <https://www.ncbi.nlm.nih.gov/pubmed/31912902>.
2. SEER Cancer Statistics Factsheets: Vulvar Cancer. Bethesda, MD: National Cancer Institute; Available at: <http://seer.cancer.gov/statfacts/html/vulva.html>. Accessed Sept 6, 2018.
3. Tergas AI, Tseng JH, Bristow RE. Impact of race and ethnicity on treatment and survival of women with vulvar cancer in the United States. *Gynecol Oncol* 2013;129:154-158. Available at: <https://www.ncbi.nlm.nih.gov/pubmed/23274562>.
4. Chase DM, Lin CC, Craig CD, et al. Disparities in Vulvar Cancer Reported by the National Cancer Database: Influence of Sociodemographic Factors. *Obstet Gynecol* 2015;126:792-802. Available at: <https://www.ncbi.nlm.nih.gov/pubmed/26348176>.
5. Vulvar Cancer Treatment- for health professionals (PDQ®). Bethesda, MD: 2015. Available at: <http://www.cancer.gov/types/vulvar/hp/vulvar-treatment-pdq#section/1>. Accessed August 3, 2015.
6. Stroup AM, Harlan LC, Trimble EL. Demographic, clinical, and treatment trends among women diagnosed with vulvar cancer in the United States. *Gynecol Oncol* 2008;108:577-583. Available at: <https://www.ncbi.nlm.nih.gov/pubmed/18155274>.
7. Figge DC. Rare Vulvar Malignancies. In: Greer BE, Berek JS, eds. *Current Topics In Obstetrics And Gynecology: Gynecologic Oncology: Treatment Rationale And Techniques*. Elsevier; 1991:239-257.
8. Sideri M, Jones RW, Wilkinson EJ, et al. Squamous vulvar intraepithelial neoplasia: 2004 modified terminology, ISSVD Vulvar Oncology Subcommittee. *J Reprod Med* 2005;50:807-810. Available at: <https://www.ncbi.nlm.nih.gov/pubmed/16419625>.
9. Bornstein J, Bogliatto F, Haefner HK, et al. The 2015 International Society for the Study of Vulvovaginal Disease (ISSVD) Terminology of Vulvar Squamous Intraepithelial Lesions. *Obstet Gynecol* 2016;127:264-268. Available at: <https://www.ncbi.nlm.nih.gov/pubmed/26942352>.
10. Gillison ML, Chaturvedi AK, Lowy DR. HPV prophylactic vaccines and the potential prevention of noncervical cancers in both men and women. *Cancer* 2008;113:3036-3046. Available at: <https://www.ncbi.nlm.nih.gov/pubmed/18980286>.
11. Watson M, Saraiya M, Ahmed F, et al. Using population-based cancer registry data to assess the burden of human papillomavirus-associated cancers in the United States: overview of methods. *Cancer* 2008;113:2841-2854. Available at: <https://www.ncbi.nlm.nih.gov/pubmed/18980203>.
12. Gargano JW, Wilkinson EJ, Unger ER, et al. Prevalence of human papillomavirus types in invasive vulvar cancers and vulvar intraepithelial neoplasia 3 in the United States before vaccine introduction. *J Low Genit Tract Dis* 2012;16:471-479. Available at: <https://www.ncbi.nlm.nih.gov/pubmed/22652576>.
13. Faber MT, Sand FL, Albieri V, et al. Prevalence and type distribution of human papillomavirus in squamous cell carcinoma and intraepithelial neoplasia of the vulva. *Int J Cancer* 2017;141:1161-1169. Available at: <https://www.ncbi.nlm.nih.gov/pubmed/28577297>.
14. Eifel PJ, Berek JS, Markman MA. Cancer of the cervix, vagina, and vulva. In: DeVita VT, Lawrence TS, Rosenberg SA, eds. *Principles and Practice of Oncology* (ed 9). Philadelphia, PA: Lippincott Williams & Wilkins; 2011:1311-1344.
15. Hampl M, Deckers-Figiel S, Hampl JA, et al. New aspects of vulvar cancer: changes in localization and age of onset. *Gynecol Oncol* 2008;109:340-345. Available at: <https://www.ncbi.nlm.nih.gov/pubmed/18407339>.
16. Hacker NF. Revised FIGO staging for carcinoma of the vulva. *Int J Gynaecol Obstet* 2009;105:105-106. Available at: <http://www.ncbi.nlm.nih.gov/pubmed/19329116>.



NCCN Guidelines Version 3.2021

Vulvar Cancer (Squamous Cell Carcinoma)

17. Pecorelli S. Revised FIGO staging for carcinoma of the vulva, cervix, and endometrium. *Int J Gynaecol Obstet* 2009;105:103-104. Available at: <http://www.ncbi.nlm.nih.gov/pubmed/19367689>.

18. Amin MB, Edge SB, Greene FL, et al. *AJCC Cancer Staging Manual*, 8th edition. (ed 8). New York: Springer; 2016.

19. Li J, Cai Y, Ke G, et al. Validation of the new FIGO staging system (2009) for vulvar cancer in the Chinese population. *Gynecol Oncol* 2015;137:274-279. Available at: <https://www.ncbi.nlm.nih.gov/pubmed/25759305>.

20. Tabbaa ZM, Gonzalez J, Sznurkowski JJ, et al. Impact of the new FIGO 2009 staging classification for vulvar cancer on prognosis and stage distribution. *Gynecol Oncol* 2012;127:147-152. Available at: <https://www.ncbi.nlm.nih.gov/pubmed/22704951>.

21. Tan J, Chetty N, Kondalsamy-Chennakesavan S, et al. Validation of the FIGO 2009 staging system for carcinoma of the vulva. *Int J Gynecol Cancer* 2012;22:498-502. Available at: <https://www.ncbi.nlm.nih.gov/pubmed/22367324>.

22. Greer BE, Berek JS. Evolution of the Primary Treatment of Invasive Squamous Cell Carcinoma of the Vulva. In: Greer BE, Berek JS, eds. *Current Topics In Obstetrics And Gynecology: Gynecologic Oncology: Treatment Rationale And Techniques*; Elsevier; 1991:227-238.

23. Kataoka MY, Sala E, Baldwin P, et al. The accuracy of magnetic resonance imaging in staging of vulvar cancer: a retrospective multi-centre study. *Gynecol Oncol* 2010;117:82-87. Available at: <https://www.ncbi.nlm.nih.gov/pubmed/20092880>.

24. Cohn DE, Dehdashti F, Gibb RK, et al. Prospective evaluation of positron emission tomography for the detection of groin node metastases from vulvar cancer. *Gynecol Oncol* 2002;85:179-184. Available at: <https://www.ncbi.nlm.nih.gov/pubmed/11925141>.

25. Kamran MW, O'Toole F, Meghan K, et al. Whole-body [18F]fluoro-2-deoxyglucose positron emission tomography scan as combined PET-CT

staging prior to planned radical vulvectomy and inguinofemoral lymphadenectomy for squamous vulvar cancer: a correlation with groin node metastasis. *Eur J Gynaecol Oncol* 2014;35:230-235. Available at: <https://www.ncbi.nlm.nih.gov/pubmed/24984533>.

26. Peiro V, Chiva L, Gonzalez A, et al. [Utility of the PET/CT in vulvar cancer management]. *Rev Esp Med Nucl Imagen Mol* 2014;35:87-92. Available at: <https://www.ncbi.nlm.nih.gov/pubmed/24095821>.

27. Homesley HD, Bundy BN, Sedlis A, et al. Assessment of current International Federation of Gynecology and Obstetrics staging of vulvar carcinoma relative to prognostic factors for survival (a Gynecologic Oncology Group study). *Am J Obstet Gynecol* 1991;164:997-1003; discussion 1003-1004. Available at: <https://www.ncbi.nlm.nih.gov/pubmed/2014852>.

28. Burger MP, Hollema H, Emanuels AG, et al. The importance of the groin node status for the survival of T1 and T2 vulvar carcinoma patients. *Gynecol Oncol* 1995;57:327-334. Available at: <https://www.ncbi.nlm.nih.gov/pubmed/7774836>.

29. Maggino T, Landoni F, Sartori E, et al. Patterns of recurrence in patients with squamous cell carcinoma of the vulva. A multicenter CTF Study. *Cancer* 2000;89:116-122. Available at: <https://www.ncbi.nlm.nih.gov/pubmed/10897008>.

30. van der Velden J, van Lindert AC, Lammes FB, et al. Extracapsular growth of lymph node metastases in squamous cell carcinoma of the vulva. The impact on recurrence and survival. *Cancer* 1995;75:2885-2890. Available at: <https://www.ncbi.nlm.nih.gov/pubmed/7773938>.

31. Luchini C, Nottegar A, Solmi M, et al. Prognostic implications of extranodal extension in node-positive squamous cell carcinoma of the vulva: A systematic review and meta-analysis. *Surg Oncol* 2016;25:60-65. Available at: <https://www.ncbi.nlm.nih.gov/pubmed/26394825>.

32. Origoni M, Sideri M, Garsia S, et al. Prognostic value of pathological patterns of lymph node positivity in squamous cell carcinoma of the vulva



NCCN Guidelines Version 3.2021

Vulvar Cancer (Squamous Cell Carcinoma)

stage III and IVA FIGO. *Gynecol Oncol* 1992;45:313-316. Available at: <https://www.ncbi.nlm.nih.gov/pubmed/1612509>.

33. Raspagliesi F, Hanozet F, Ditto A, et al. Clinical and pathological prognostic factors in squamous cell carcinoma of the vulva. *Gynecol Oncol* 2006;102:333-337. Available at: <https://www.ncbi.nlm.nih.gov/pubmed/16466657>.

34. Heaps JM, Fu YS, Montz FJ, et al. Surgical-pathologic variables predictive of local recurrence in squamous cell carcinoma of the vulva. *Gynecol Oncol* 1990;38:309-314. Available at: <https://www.ncbi.nlm.nih.gov/pubmed/2227541>.

35. Homesley HD, Bundy BN, Sedlis A, et al. Prognostic factors for groin node metastasis in squamous cell carcinoma of the vulva (a Gynecologic Oncology Group study). *Gynecol Oncol* 1993;49:279-283. Available at: <https://www.ncbi.nlm.nih.gov/pubmed/8314530>.

36. Aragona AM, Cuneo NA, Soderini AH, Alcoba EB. An analysis of reported independent prognostic factors for survival in squamous cell carcinoma of the vulva: is tumor size significance being underrated? *Gynecol Oncol* 2014;132:643-648. Available at: <https://www.ncbi.nlm.nih.gov/pubmed/24418199>.

37. Rouzier R, Haddad B, Plantier F, et al. Local relapse in patients treated for squamous cell vulvar carcinoma: incidence and prognostic value. *Obstet Gynecol* 2002;100:1159-1167. Available at: <https://www.ncbi.nlm.nih.gov/pubmed/12468158>.

38. Arvas M, Kahramanoglu I, Bese T, et al. The Role of Pathological Margin Distance and Prognostic Factors After Primary Surgery in Squamous Cell Carcinoma of the Vulva. *Int J Gynecol Cancer* 2018;28:623-631. Available at: <https://www.ncbi.nlm.nih.gov/pubmed/29324545>.

39. Bogani G, Cromi A, Serati M, et al. Predictors and Patterns of Local, Regional, and Distant Failure in Squamous Cell Carcinoma of the Vulva. *Am J Clin Oncol* 2017;40:235-240. Available at: <https://www.ncbi.nlm.nih.gov/pubmed/25503429>.

40. Te Grootenhuys NC, Pouwer AW, de Bock GH, et al. Prognostic factors for local recurrence of squamous cell carcinoma of the vulva: A systematic review. *Gynecol Oncol* 2018;148:622-631. Available at: <https://www.ncbi.nlm.nih.gov/pubmed/29137809>.

41. Figge DC, Tamimi HK, Greer BE. Lymphatic spread in carcinoma of the vulva. *Am J Obstet Gynecol* 1985;152:387-394. Available at: <https://www.ncbi.nlm.nih.gov/pubmed/4014331>.

42. Farias-Eisner R, Cirisano FD, Grouse D, et al. Conservative and individualized surgery for early squamous carcinoma of the vulva: the treatment of choice for stage I and II (T1-2N0-1M0) disease. *Gynecol Oncol* 1994;53:55-58. Available at: <https://www.ncbi.nlm.nih.gov/pubmed/8175023>.

43. Stehman FB, Look KY. Carcinoma of the vulva. *Obstet Gynecol* 2006;107:719-733. Available at: <https://www.ncbi.nlm.nih.gov/pubmed/16507947>.

44. Landrum LM, Lanneau GS, Skaggs VJ, et al. Gynecologic Oncology Group risk groups for vulvar carcinoma: improvement in survival in the modern era. *Gynecol Oncol* 2007;106:521-525. Available at: <https://www.ncbi.nlm.nih.gov/pubmed/17540438>.

45. Kim KW, Shinagare AB, Krajewski KM, et al. Update on imaging of vulvar squamous cell carcinoma. *AJR Am J Roentgenol* 2013;201:W147-157. Available at: <https://www.ncbi.nlm.nih.gov/pubmed/23789687>.

46. Slomovitz BM, Coleman RL, Oonk MH, et al. Update on sentinel lymph node biopsy for early-stage vulvar cancer. *Gynecol Oncol* 2015;138:472-477. Available at: <https://www.ncbi.nlm.nih.gov/pubmed/26022527>.

47. Magrina JF, Gonzalez-Bosquet J, Weaver AL, et al. Primary squamous cell cancer of the vulva: radical versus modified radical vulvar surgery. *Gynecol Oncol* 1998;71:116-121. Available at: <https://www.ncbi.nlm.nih.gov/pubmed/9784331>.

48. Ansink A, van der Velden J. Surgical interventions for early squamous cell carcinoma of the vulva. *Cochrane Database Syst Rev*



NCCN Guidelines Version 3.2021

Vulvar Cancer (Squamous Cell Carcinoma)

2000:CD002036. Available at:

<https://www.ncbi.nlm.nih.gov/pubmed/10796849>.

49. DeSimone CP, Van Ness JS, Cooper AL, et al. The treatment of lateral T1 and T2 squamous cell carcinomas of the vulva confined to the labium majus or minus. *Gynecol Oncol* 2007;104:390-395. Available at:

<https://www.ncbi.nlm.nih.gov/pubmed/17027067>.

50. De Hullu JA, Hollema H, Lolkema S, et al. Vulvar carcinoma. The price of less radical surgery. *Cancer* 2002;95:2331-2338. Available at:

<https://www.ncbi.nlm.nih.gov/pubmed/12436439>.

51. Viswanathan AN, Pinto AP, Schultz D, et al. Relationship of margin status and radiation dose to recurrence in post-operative vulvar carcinoma. *Gynecol Oncol* 2013;130:545-549. Available at:

<https://www.ncbi.nlm.nih.gov/pubmed/23747330>.

52. Chan JK, Sugiyama V, Pham H, et al. Margin distance and other clinico-pathologic prognostic factors in vulvar carcinoma: a multivariate analysis. *Gynecol Oncol* 2007;104:636-641. Available at:

<https://www.ncbi.nlm.nih.gov/pubmed/17095080>.

53. Faul CM, Mirmow D, Huang Q, et al. Adjuvant radiation for vulvar carcinoma: improved local control. *Int J Radiat Oncol Biol Phys* 1997;38:381-389. Available at:

<https://www.ncbi.nlm.nih.gov/pubmed/9226327>.

54. Woelber L, Eulenburg C, Grimm D, et al. The Risk of Contralateral Non-sentinel Metastasis in Patients with Primary Vulvar Cancer and Unilaterally Positive Sentinel Node. *Ann Surg Oncol* 2016;23:2508-2514. Available at:

<https://www.ncbi.nlm.nih.gov/pubmed/26856721>.

55. Coleman RL, Ali S, Levenback CF, et al. Is bilateral lymphadenectomy for midline squamous carcinoma of the vulva always necessary? An analysis from Gynecologic Oncology Group (GOG) 173. *Gynecol Oncol* 2013;128:155-159. Available at:

<https://www.ncbi.nlm.nih.gov/pubmed/23201592>.

56. Carlson JW, Kauderer J, Hutson A, et al. GOG 244-The lymphedema and gynecologic cancer (LEG) study: Incidence and risk factors in newly diagnosed patients. *Gynecol Oncol* 2020;156:467-474. Available at:

<https://www.ncbi.nlm.nih.gov/pubmed/31837831>.

57. DiSaia PJ, Creasman WT, Rich WM. An alternate approach to early cancer of the vulva. *Am J Obstet Gynecol* 1979;133:825-832. Available at:

<https://www.ncbi.nlm.nih.gov/pubmed/434024>.

58. Van der Zee AG, Oonk MH, De Hullu JA, et al. Sentinel node dissection is safe in the treatment of early-stage vulvar cancer. *J Clin Oncol* 2008;26:884-889. Available at:

<https://www.ncbi.nlm.nih.gov/pubmed/18281661>.

59. Levenback CF, Ali S, Coleman RL, et al. Lymphatic mapping and sentinel lymph node biopsy in women with squamous cell carcinoma of the vulva: a gynecologic oncology group study. *J Clin Oncol* 2012;30:3786-3791. Available at:

<https://www.ncbi.nlm.nih.gov/pubmed/22753905>.

60. Klapdor R, Hillemanns P, Wolber L, et al. Outcome After Sentinel Lymph Node Dissection in Vulvar Cancer: A Subgroup Analysis of the AGO-CaRE-1 Study. *Ann Surg Oncol* 2017;24:1314-1321. Available at:

<https://www.ncbi.nlm.nih.gov/pubmed/27896515>.

61. Covens A, Vella ET, Kennedy EB, et al. Sentinel lymph node biopsy in vulvar cancer: Systematic review, meta-analysis and guideline recommendations. *Gynecol Oncol* 2015;137:351-361. Available at:

<https://www.ncbi.nlm.nih.gov/pubmed/25703673>.

62. Oonk MH, van Hemel BM, Hollema H, et al. Size of sentinel-node metastasis and chances of non-sentinel-node involvement and survival in early stage vulvar cancer: results from GROINSS-V, a multicentre observational study. *Lancet Oncol* 2010;11:646-652. Available at:

<https://www.ncbi.nlm.nih.gov/pubmed/20537946>.

63. Oonk MH, van Os MA, de Bock GH, et al. A comparison of quality of life between vulvar cancer patients after sentinel lymph node procedure only and inguinofemoral lymphadenectomy. *Gynecol Oncol* 2009;113:301-305. Available at:

<https://www.ncbi.nlm.nih.gov/pubmed/19297013>.



NCCN Guidelines Version 3.2021

Vulvar Cancer (Squamous Cell Carcinoma)

64. Te Grootenhuis NC, van der Zee AG, van Doorn HC, et al. Sentinel nodes in vulvar cancer: Long-term follow-up of the GROningen International Study on Sentinel nodes in Vulvar cancer (GROINSS-V) I. *Gynecol Oncol* 2016;140:8-14. Available at: <https://www.ncbi.nlm.nih.gov/pubmed/26428940>.

65. Gonzalez Bosquet J, Magrina JF, Magtibay PM, et al. Patterns of inguinal groin metastases in squamous cell carcinoma of the vulva. *Gynecol Oncol* 2007;105:742-746. Available at: <https://www.ncbi.nlm.nih.gov/pubmed/17379281>.

66. Hacker NF, Berek JS, Lagasse LD, et al. Individualization of treatment for stage I squamous cell vulvar carcinoma. *Obstet Gynecol* 1984;63:155-162. Available at: <https://www.ncbi.nlm.nih.gov/pubmed/6694808>.

67. Burke TW, Levenback C, Coleman RL, et al. Surgical therapy of T1 and T2 vulvar carcinoma: further experience with radical wide excision and selective inguinal lymphadenectomy. *Gynecol Oncol* 1995;57:215-220. Available at: <https://www.ncbi.nlm.nih.gov/pubmed/7729737>.

68. Hacker NF, Van der Velden J. Conservative management of early vulvar cancer. *Cancer* 1993;71:1673-1677. Available at: <https://www.ncbi.nlm.nih.gov/pubmed/8431905>.

69. Morgan MA, Mikuta JJ. Surgical management of vulvar cancer. *Semin Surg Oncol* 1999;17:168-172. Available at: <https://www.ncbi.nlm.nih.gov/pubmed/10504664>.

70. van der Velden J, Fons G, Lawrie TA. Primary groin irradiation versus primary groin surgery for early vulvar cancer. *Cochrane Database Syst Rev* 2011;CD002224. Available at: <https://www.ncbi.nlm.nih.gov/pubmed/21563133>.

71. Stehman FB, Bundy BN, Thomas G, et al. Groin dissection versus groin radiation in carcinoma of the vulva: a Gynecologic Oncology Group study. *Int J Radiat Oncol Biol Phys* 1992;24:389-396. Available at: <https://www.ncbi.nlm.nih.gov/pubmed/1526880>.

72. Hallak S, Ladi L, Sorbe B. Prophylactic inguinal-femoral irradiation as an alternative to primary lymphadenectomy in treatment of vulvar carcinoma. *Int J Oncol* 2007;31:1077-1085. Available at: <https://www.ncbi.nlm.nih.gov/pubmed/17912433>.

73. Petereit DG, Mehta MP, Buchler DA, Kinsella TJ. Inguinofemoral radiation of N0,N1 vulvar cancer may be equivalent to lymphadenectomy if proper radiation technique is used. *Int J Radiat Oncol Biol Phys* 1993;27:963-967. Available at: <https://www.ncbi.nlm.nih.gov/pubmed/8244830>.

74. Rouzier R, Haddad B, Atallah D, et al. Surgery for vulvar cancer. *Clin Obstet Gynecol* 2005;48:869-878. Available at: <https://www.ncbi.nlm.nih.gov/pubmed/16286833>.

75. Magrina JF, Gonzalez-Bosquet J, Weaver AL, et al. Squamous cell carcinoma of the vulva stage IA: long-term results. *Gynecol Oncol* 2000;76:24-27. Available at: <https://www.ncbi.nlm.nih.gov/pubmed/10620436>.

76. Yoder BJ, Rufforny I, Massoll NA, Wilkinson EJ. Stage IA vulvar squamous cell carcinoma: an analysis of tumor invasive characteristics and risk. *Am J Surg Pathol* 2008;32:765-772. Available at: <https://www.ncbi.nlm.nih.gov/pubmed/18379417>.

77. Wilkinson EJ. Superficial invasive carcinoma of the vulva. *Clin Obstet Gynecol* 1985;28:188-195. Available at: <https://www.ncbi.nlm.nih.gov/pubmed/3987129>.

78. Forner DM, Lampe B. Exenteration in the treatment of Stage III/IV vulvar cancer. *Gynecol Oncol* 2012;124:87-91. Available at: <https://www.ncbi.nlm.nih.gov/pubmed/21992967>.

79. Miller B, Morris M, Levenback C, et al. Pelvic exenteration for primary and recurrent vulvar cancer. *Gynecol Oncol* 1995;58:202-205. Available at: <https://www.ncbi.nlm.nih.gov/pubmed/7622106>.

80. Hoffman MS, Cavanagh D, Roberts WS, et al. Ultraradical surgery for advanced carcinoma of the vulva: an update. *Int J Gynecol Cancer*



NCCN Guidelines Version 3.2021

Vulvar Cancer (Squamous Cell Carcinoma)

1993;3:369-372. Available at:

<https://www.ncbi.nlm.nih.gov/pubmed/11578371>.

81. Gadducci A, Cionini L, Romanini A, et al. Old and new perspectives in the management of high-risk, locally advanced or recurrent, and metastatic vulvar cancer. *Crit Rev Oncol Hematol* 2006;60:227-241.

Available at: <https://www.ncbi.nlm.nih.gov/pubmed/16945551>.

82. Boronow RC. Combined therapy as an alternative to exenteration for locally advanced vulvo-vaginal cancer: rationale and results. *Cancer* 1982;49:1085-1091. Available at:

<https://www.ncbi.nlm.nih.gov/pubmed/7059935>.

83. Fuh KC, Berek JS. Current management of vulvar cancer. *Hematol Oncol Clin North Am* 2012;26:45-62. Available at:

<https://www.ncbi.nlm.nih.gov/pubmed/22244661>.

84. Leiserowitz GS, Russell AH, Kinney WK, et al. Prophylactic chemoradiation of inguinofemoral lymph nodes in patients with locally extensive vulvar cancer. *Gynecol Oncol* 1997;66:509-514. Available at:

<https://www.ncbi.nlm.nih.gov/pubmed/9299268>.

85. Russell AH, Mesic JB, Scudder SA, et al. Synchronous radiation and cytotoxic chemotherapy for locally advanced or recurrent squamous cancer of the vulva. *Gynecol Oncol* 1992;47:14-20. Available at:

<https://www.ncbi.nlm.nih.gov/pubmed/1427394>.

86. Thomas G, Dembo A, DePetrillo A, et al. Concurrent radiation and chemotherapy in vulvar carcinoma. *Gynecol Oncol* 1989;34:263-267.

Available at: <https://www.ncbi.nlm.nih.gov/pubmed/2504651>.

87. Eifel PJ, Morris M, Burke TW, et al. Prolonged continuous infusion cisplatin and 5-fluorouracil with radiation for locally advanced carcinoma of the vulva. *Gynecol Oncol* 1995;59:51-56. Available at:

<https://www.ncbi.nlm.nih.gov/pubmed/7557615>.

88. Lupi G, Raspagliesi F, Zucali R, et al. Combined preoperative chemoradiotherapy followed by radical surgery in locally advanced vulvar

carcinoma. A pilot study. *Cancer* 1996;77:1472-1478. Available at:

<https://www.ncbi.nlm.nih.gov/pubmed/8608531>.

89. Moore DH, Thomas GM, Montana GS, et al. Preoperative chemoradiation for advanced vulvar cancer: a phase II study of the Gynecologic Oncology Group. *Int J Radiat Oncol Biol Phys* 1998;42:79-85.

Available at: <https://www.ncbi.nlm.nih.gov/pubmed/9747823>.

90. Geisler JP, Manahan KJ, Buller RE. Neoadjuvant chemotherapy in vulvar cancer: avoiding primary exenteration. *Gynecol Oncol* 2006;100:53-57. Available at: <https://www.ncbi.nlm.nih.gov/pubmed/16257042>.

91. Landoni F, Maneo A, Zanetta G, et al. Concurrent preoperative chemotherapy with 5-fluorouracil and mitomycin C and radiotherapy (FUMIR) followed by limited surgery in locally advanced and recurrent vulvar carcinoma. *Gynecol Oncol* 1996;61:321-327. Available at:

<https://www.ncbi.nlm.nih.gov/pubmed/8641609>.

92. Berek JS, Heaps JM, Fu YS, et al. Concurrent cisplatin and 5-fluorouracil chemotherapy and radiation therapy for advanced-stage squamous carcinoma of the vulva. *Gynecol Oncol* 1991;42:197-201.

Available at: <https://www.ncbi.nlm.nih.gov/pubmed/1955180>.

93. Koh WJ, Wallace HJ, 3rd, Greer BE, et al. Combined radiotherapy and chemotherapy in the management of local-regionally advanced vulvar cancer. *Int J Radiat Oncol Biol Phys* 1993;26:809-816. Available at:

<https://www.ncbi.nlm.nih.gov/pubmed/8344850>.

94. Cunningham MJ, Goyer RP, Gibbons SK, et al. Primary radiation, cisplatin, and 5-fluorouracil for advanced squamous carcinoma of the vulva. *Gynecol Oncol* 1997;66:258-261. Available at:

<https://www.ncbi.nlm.nih.gov/pubmed/9264573>.

95. Gerszten K, Selvaraj RN, Kelley J, Faul C. Preoperative chemoradiation for locally advanced carcinoma of the vulva. *Gynecol Oncol* 2005;99:640-644. Available at:

<https://www.ncbi.nlm.nih.gov/pubmed/16169579>.



NCCN Guidelines Version 3.2021

Vulvar Cancer (Squamous Cell Carcinoma)

96. Tans L, Ansink AC, van Rooij PH, et al. The role of chemo-radiotherapy in the management of locally advanced carcinoma of the vulva: single institutional experience and review of literature. *Am J Clin Oncol* 2011;34:22-26. Available at:

<https://www.ncbi.nlm.nih.gov/pubmed/20087157>.

97. Han SC, Kim DH, Higgins SA, et al. Chemoradiation as primary or adjuvant treatment for locally advanced carcinoma of the vulva. *Int J Radiat Oncol Biol Phys* 2000;47:1235-1244. Available at:

<https://www.ncbi.nlm.nih.gov/pubmed/10889377>.

98. Rao YJ, Chin RI, Hui C, et al. Improved survival with definitive chemoradiation compared to definitive radiation alone in squamous cell carcinoma of the vulva: A review of the National Cancer Database. *Gynecol Oncol* 2017;146:572-579. Available at:

<https://www.ncbi.nlm.nih.gov/pubmed/28662775>.

99. Montana GS, Thomas GM, Moore DH, et al. Preoperative chemo-radiation for carcinoma of the vulva with N2/N3 nodes: a gynecologic oncology group study. *Int J Radiat Oncol Biol Phys* 2000;48:1007-1013. Available at: <https://www.ncbi.nlm.nih.gov/pubmed/11072157>.

100. Moore DH, Ali S, Koh WJ, et al. A phase II trial of radiation therapy and weekly cisplatin chemotherapy for the treatment of locally-advanced squamous cell carcinoma of the vulva: a gynecologic oncology group study. *Gynecol Oncol* 2012;124:529-533. Available at:

<https://www.ncbi.nlm.nih.gov/pubmed/22079361>.

101. Natesan D, Hong JC, Foote J, et al. Primary Versus Preoperative Radiation for Locally Advanced Vulvar Cancer. *Int J Gynecol Cancer* 2017;27:794-804. Available at:

<https://www.ncbi.nlm.nih.gov/pubmed/28333840>.

102. Shylasree TS, Bryant A, Howells RE. Chemoradiation for advanced primary vulval cancer. *Cochrane Database Syst Rev* 2011;CD003752. Available at: <https://www.ncbi.nlm.nih.gov/pubmed/21491387>.

103. van Doorn HC, Ansink A, Verhaar-Langereis M, Stalpers L. Neoadjuvant chemoradiation for advanced primary vulvar cancer.

Cochrane Database Syst Rev 2006;CD003752. Available at:

<https://www.ncbi.nlm.nih.gov/pubmed/16856018>.

104. Reade CJ, Eiriksson LR, Mackay H. Systemic therapy in squamous cell carcinoma of the vulva: current status and future directions. *Gynecol Oncol* 2014;132:780-789. Available at:

<https://www.ncbi.nlm.nih.gov/pubmed/24296343>.

105. Chin JY, Hong TS, Ryan DP. Mitomycin in anal cancer: still the standard of care. *J Clin Oncol* 2012;30:4297-4301. Available at:

<https://www.ncbi.nlm.nih.gov/pubmed/23150704>.

106. Han SN, Vergote I, Amant F. Weekly paclitaxel/carboplatin in the treatment of locally advanced, recurrent, or metastatic vulvar cancer. *Int J Gynecol Cancer* 2012;22:865-868. Available at:

<https://www.ncbi.nlm.nih.gov/pubmed/22552830>.

107. Witteveen PO, van der Velden J, Vergote I, et al. Phase II study on paclitaxel in patients with recurrent, metastatic or locally advanced vulvar cancer not amenable to surgery or radiotherapy: a study of the EORTC-GCG (European Organisation for Research and Treatment of Cancer--Gynaecological Cancer Group). *Ann Oncol* 2009;20:1511-1516. Available at: <https://www.ncbi.nlm.nih.gov/pubmed/19487487>.

108. Horowitz NS, Olawaiye AB, Borger DR, et al. Phase II trial of erlotinib in women with squamous cell carcinoma of the vulva. *Gynecol Oncol* 2012;127:141-146. Available at:

<https://www.ncbi.nlm.nih.gov/pubmed/22750258>.

109. Jolly S, Soni P, Gaffney DK, et al. ACR Appropriateness Criteria(R) Adjuvant Therapy in Vulvar Cancer. *Oncology (Williston Park)* 2015;29:867-872, 874-865. Available at:

<https://www.ncbi.nlm.nih.gov/pubmed/26568534>.

110. Homesley HD, Bundy BN, Sedlis A, Adcock L. Radiation therapy versus pelvic node resection for carcinoma of the vulva with positive groin nodes. *Obstet Gynecol* 1986;68:733-740. Available at:

<https://www.ncbi.nlm.nih.gov/pubmed/3785783>.



NCCN Guidelines Version 3.2021

Vulvar Cancer (Squamous Cell Carcinoma)

111. Kunos C, Simpkins F, Gibbons H, et al. Radiation therapy compared with pelvic node resection for node-positive vulvar cancer: a randomized controlled trial. *Obstet Gynecol* 2009;114:537-546. Available at: <https://www.ncbi.nlm.nih.gov/pubmed/19701032>.

112. Swanick CW, Eifel PJ, Huo J, et al. Challenges to delivery and effectiveness of adjuvant radiation therapy in elderly patients with node-positive vulvar cancer. *Gynecol Oncol* 2017;146:87-93. Available at: <https://www.ncbi.nlm.nih.gov/pubmed/28506563>.

113. Fons G, Groenen SM, Oonk MH, et al. Adjuvant radiotherapy in patients with vulvar cancer and one intra capsular lymph node metastasis is not beneficial. *Gynecol Oncol* 2009;114:343-345. Available at: <https://www.ncbi.nlm.nih.gov/pubmed/19481242>.

114. Mahner S, Jueckstock J, Hilpert F, et al. Adjuvant therapy in lymph node-positive vulvar cancer: the AGO-CaRE-1 study. *J Natl Cancer Inst* 2015;107. Available at: <https://www.ncbi.nlm.nih.gov/pubmed/25618900>.

115. Parthasarathy A, Cheung MK, Osann K, et al. The benefit of adjuvant radiation therapy in single-node-positive squamous cell vulvar carcinoma. *Gynecol Oncol* 2006;103:1095-1099. Available at: <https://www.ncbi.nlm.nih.gov/pubmed/16889821>.

116. Woelber L, Eulenburg C, Choschzick M, et al. Prognostic role of lymph node metastases in vulvar cancer and implications for adjuvant treatment. *Int J Gynecol Cancer* 2012;22:503-508. Available at: <https://www.ncbi.nlm.nih.gov/pubmed/22266935>.

117. Gill BS, Bernard ME, Lin JF, et al. Impact of adjuvant chemotherapy with radiation for node-positive vulvar cancer: A National Cancer Data Base (NCDB) analysis. *Gynecol Oncol* 2015;137:365-372. Available at: <https://www.ncbi.nlm.nih.gov/pubmed/25868965>.

118. Swanick CW, Smith GL, Huo J, et al. (P021) Delivery and Outcomes of Adjuvant Radiation Therapy in Older Women With Node-Positive Vulvar Cancer. *Oncology (Williston Park)* 2016;30 Suppl. Available at: <https://www.ncbi.nlm.nih.gov/pubmed/27083660>.

119. Ignatov T, Eggemann H, Burger E, et al. Adjuvant radiotherapy for vulvar cancer with close or positive surgical margins. *J Cancer Res Clin Oncol* 2016;142:489-495. Available at: <https://www.ncbi.nlm.nih.gov/pubmed/26498775>.

120. van Beekhuizen HJ, Auzin M, van den Einden LC, et al. Lymph node count at inguinofemoral lymphadenectomy and groin recurrences in vulvar cancer. *Int J Gynecol Cancer* 2014;24:773-778. Available at: <https://www.ncbi.nlm.nih.gov/pubmed/24662136>.

121. Bell JG, Lea JS, Reid GC. Complete groin lymphadenectomy with preservation of the fascia lata in the treatment of vulvar carcinoma. *Gynecol Oncol* 2000;77:314-318. Available at: <https://www.ncbi.nlm.nih.gov/pubmed/10785485>.

122. Stehman FB, Bundy BN, Dvoretzky PM, Creasman WT. Early stage I carcinoma of the vulva treated with ipsilateral superficial inguinal lymphadenectomy and modified radical hemivulvectomy: a prospective study of the Gynecologic Oncology Group. *Obstet Gynecol* 1992;79:490-497. Available at: <https://www.ncbi.nlm.nih.gov/pubmed/1553164>.

123. Kirby TO, Rocconi RP, Numnum TM, et al. Outcomes of Stage I/II vulvar cancer patients after negative superficial inguinal lymphadenectomy. *Gynecol Oncol* 2005;98:309-312. Available at: <https://www.ncbi.nlm.nih.gov/pubmed/15975642>.

124. Gonzalez Bosquet J, Magrina JF, Gaffey TA, et al. Long-term survival and disease recurrence in patients with primary squamous cell carcinoma of the vulva. *Gynecol Oncol* 2005;97:828-833. Available at: <https://www.ncbi.nlm.nih.gov/pubmed/15896831>.

125. Nooij LS, Brand FA, Gaarenstroom KN, et al. Risk factors and treatment for recurrent vulvar squamous cell carcinoma. *Crit Rev Oncol Hematol* 2016;106:1-13. Available at: <https://www.ncbi.nlm.nih.gov/pubmed/27637349>.

126. Gien LT, Sutradhar R, Thomas G, et al. Patient, tumor, and health system factors affecting groin node dissection rates in vulvar carcinoma: A



NCCN Guidelines Version 3.2021

Vulvar Cancer (Squamous Cell Carcinoma)

population-based cohort study. *Gynecol Oncol* 2015;139:465-470. Available at: <https://www.ncbi.nlm.nih.gov/pubmed/26483007>.

127. Salani R, Khanna N, Frimer M, et al. An update on post-treatment surveillance and diagnosis of recurrence in women with gynecologic malignancies: Society of Gynecologic Oncology (SGO) recommendations. *Gynecol Oncol* 2017;146:3-10. Available at: <https://www.ncbi.nlm.nih.gov/pubmed/28372871>.

128. Mahner S, Prieske K, Grimm D, et al. Systemic treatment of vulvar cancer. *Expert Rev Anticancer Ther* 2015;15:629-637. Available at: <https://www.ncbi.nlm.nih.gov/pubmed/25997120>.

129. Salom EM, Penalver M. Recurrent vulvar cancer. *Curr Treat Options Oncol* 2002;3:143-153. Available at: <https://www.ncbi.nlm.nih.gov/pubmed/12057077>.

130. Piura B, Masotina A, Murdoch J, et al. Recurrent squamous cell carcinoma of the vulva: a study of 73 cases. *Gynecol Oncol* 1993;48:189-195. Available at: <https://www.ncbi.nlm.nih.gov/pubmed/8428690>.

131. Raffetto N, Tombolini V, Santarelli M, et al. Radiotherapy alone and chemoradiation in recurrent squamous cell carcinoma of the vulva. *Anticancer Res* 2003;23:3105-3108. Available at: <https://www.ncbi.nlm.nih.gov/pubmed/12926170>.

132. Podratz KC, Symmonds RE, Taylor WF, Williams TJ. Carcinoma of the vulva: analysis of treatment and survival. *Obstet Gynecol* 1983;61:63-74. Available at: <https://www.ncbi.nlm.nih.gov/pubmed/6823350>.

133. Chiantera V, Rossi M, De Iaco P, et al. Morbidity after pelvic exenteration for gynecological malignancies: a retrospective multicentric study of 230 patients. *Int J Gynecol Cancer* 2014;24:156-164. Available at: <https://www.ncbi.nlm.nih.gov/pubmed/24362721>.

134. Stehman FB, Bundy BN, Ball H, Clarke-Pearson DL. Sites of failure and times to failure in carcinoma of the vulva treated conservatively: a Gynecologic Oncology Group study. *Am J Obstet Gynecol* 1996;174:1128-

1132; discussion 1132-1123. Available at: <https://www.ncbi.nlm.nih.gov/pubmed/8623839>.

135. Hopkins MP, Reid GC, Morley GW. The surgical management of recurrent squamous cell carcinoma of the vulva. *Obstet Gynecol* 1990;75:1001-1005. Available at: <https://www.ncbi.nlm.nih.gov/pubmed/2342725>.

136. Bellati F, Angioli R, Manci N, et al. Single agent cisplatin chemotherapy in surgically resected vulvar cancer patients with multiple inguinal lymph node metastases. *Gynecol Oncol* 2005;96:227-231. Available at: <https://www.ncbi.nlm.nih.gov/pubmed/15589606>.

137. Tewari KS, Sill MW, Penson RT, et al. Bevacizumab for advanced cervical cancer: final overall survival and adverse event analysis of a randomised, controlled, open-label, phase 3 trial (Gynecologic Oncology Group 240). *Lancet* 2017;390:1654-1663. Available at: <https://www.ncbi.nlm.nih.gov/pubmed/28756902>.

138. Rosen VM, Guerra I, McCormack M, et al. Systematic Review and Network Meta-Analysis of Bevacizumab Plus First-Line Topotecan-Paclitaxel or Cisplatin-Paclitaxel Versus Non-Bevacizumab-Containing Therapies in Persistent, Recurrent, or Metastatic Cervical Cancer. *Int J Gynecol Cancer* 2017;27:1237-1246. Available at: <https://www.ncbi.nlm.nih.gov/pubmed/28448304>.

139. Kitagawa R, Katsumata N, Shibata T, et al. Paclitaxel Plus Carboplatin Versus Paclitaxel Plus Cisplatin in Metastatic or Recurrent Cervical Cancer: The Open-Label Randomized Phase III Trial JCOG0505. *J Clin Oncol* 2015;33:2129-2135. Available at: <https://www.ncbi.nlm.nih.gov/pubmed/25732161>.

140. Lorusso D, Petrelli F, Coinu A, et al. A systematic review comparing cisplatin and carboplatin plus paclitaxel-based chemotherapy for recurrent or metastatic cervical cancer. *Gynecol Oncol* 2014;133:117-123. Available at: <https://www.ncbi.nlm.nih.gov/pubmed/24486604>.



NCCN Guidelines Version 3.2021

Vulvar Cancer (Squamous Cell Carcinoma)

141. Cormio G, Loizzi V, Gissi F, et al. Cisplatin and vinorelbine chemotherapy in recurrent vulvar carcinoma. *Oncology* 2009;77:281-284. Available at: <https://www.ncbi.nlm.nih.gov/pubmed/19923866>.

142. Santeufemia DA, Capobianco G, Re GL, et al. Cisplatin-gemcitabine as palliative chemotherapy in advanced squamous vulvar carcinoma: report of two cases. *Eur J Gynaecol Oncol* 2012;33:421-422. Available at: <https://www.ncbi.nlm.nih.gov/pubmed/23091903>.

143. Monk BJ, Sill MW, McMeekin DS, et al. Phase III trial of four cisplatin-containing doublet combinations in stage IVB, recurrent, or persistent cervical carcinoma: a Gynecologic Oncology Group study. *J Clin Oncol* 2009;27:4649-4655. Available at: <https://www.ncbi.nlm.nih.gov/pubmed/19720909>.

144. Buchbinder EI, Desai A. CTLA-4 and PD-1 Pathways: Similarities, Differences, and Implications of Their Inhibition. *Am J Clin Oncol* 2016;39:98-106. Available at: <https://www.ncbi.nlm.nih.gov/pubmed/26558876>.

145. Chen DS, Irving BA, Hodi FS. Molecular pathways: next-generation immunotherapy--inhibiting programmed death-ligand 1 and programmed death-1. *Clin Cancer Res* 2012;18:6580-6587. Available at: <https://www.ncbi.nlm.nih.gov/pubmed/23087408>.

146. Wherry EJ. T cell exhaustion. *Nat Immunol* 2011;12:492-499. Available at: <https://www.ncbi.nlm.nih.gov/pubmed/21739672>.

147. Hecking T, Thiesler T, Schiller C, et al. Tumoral PD-L1 expression defines a subgroup of poor-prognosis vulvar carcinomas with non-viral etiology. *Oncotarget* 2017;8:92890-92903. Available at: <https://www.ncbi.nlm.nih.gov/pubmed/29190964>.

148. Howitt BE, Sun HH, Roemer MG, et al. Genetic Basis for PD-L1 Expression in Squamous Cell Carcinomas of the Cervix and Vulva. *JAMA Oncol* 2016;2:518-522. Available at: <https://www.ncbi.nlm.nih.gov/pubmed/26913631>.

149. Chung HC, Schellens JH, Delord J-P, et al. Pembrolizumab treatment of advanced cervical cancer: Updated results from the phase 2 KEYNOTE-158 study [abstract]. *J Clin Oncol* 2018 36. Available at: <https://meetinglibrary.asco.org/record/160523/abstract>.

150. FDA approves pembrolizumab for advanced cervical cancer with disease progression during or after chemotherapy. 2018. Available at: <https://www.fda.gov/drugs/resources-information-approved-drugs/fda-approves-pembrolizumab-advanced-cervical-cancer-disease-progression-during-or-after-chemotherapy>. Accessed

151. Chung HC, Ros W, Delord JP, et al. Efficacy and Safety of Pembrolizumab in Previously Treated Advanced Cervical Cancer: Results From the Phase II KEYNOTE-158 Study. *J Clin Oncol* 2019;37:1470-1478. Available at: <https://www.ncbi.nlm.nih.gov/pubmed/30943124>.

152. Marabelle A, Fakih M, Lopez J, et al. Association of tumour mutational burden with outcomes in patients with advanced solid tumours treated with pembrolizumab: prospective biomarker analysis of the multicohort, open-label, phase 2 KEYNOTE-158 study. *Lancet Oncol* 2020;21:1353-1365. Available at: <https://www.ncbi.nlm.nih.gov/pubmed/32919526>.

153. Marabelle A, Le DT, Ascierto PA, et al. Efficacy of Pembrolizumab in Patients With Noncolorectal High Microsatellite Instability/Mismatch Repair-Deficient Cancer: Results From the Phase II KEYNOTE-158 Study. *J Clin Oncol* 2020;38:1-10. Available at: <https://www.ncbi.nlm.nih.gov/pubmed/31682550>.

154. FDA grants accelerated approval to pembrolizumab for first tissue/site agnostic indication. 2017. Available at: <https://www.fda.gov/drugs/resources-information-approved-drugs/fda-grants-accelerated-approval-pembrolizumab-first-tissuesite-agnostic-indication>.

155. FDA approves pembrolizumab for adults and children with TMB-H solid tumors. 2020. Available at: <https://www.fda.gov/drugs/drug-approvals-and-databases/fda-approves-pembrolizumab-adults-and-children-tmb-h-solid-tumors>.



NCCN Guidelines Version 3.2021

Vulvar Cancer (Squamous Cell Carcinoma)

156. Naumann RW, Hollebecque A, Meyer T, et al. Safety and Efficacy of Nivolumab Monotherapy in Recurrent or Metastatic Cervical, Vaginal, or Vulvar Carcinoma: Results From the Phase I/II CheckMate 358 Trial. *J Clin Oncol* 2019;37:2825-2834. Available at: <https://www.ncbi.nlm.nih.gov/pubmed/31487218>.

157. Doebele RC, Drilon A, Paz-Ares L, et al. Entrectinib in patients with advanced or metastatic NTRK fusion-positive solid tumours: integrated analysis of three phase 1-2 trials. *Lancet Oncol* 2020;21:271-282. Available at: <https://www.ncbi.nlm.nih.gov/pubmed/31838007>.

158. Drilon A, Laetsch TW, Kummar S, et al. Efficacy of Larotrectinib in TRK Fusion-Positive Cancers in Adults and Children. *N Engl J Med* 2018;378:731-739. Available at: <https://www.ncbi.nlm.nih.gov/pubmed/29466156>.

159. Hong DS, Bauer TM, Lee JJ, et al. Larotrectinib in adult patients with solid tumours: a multi-centre, open-label, phase I dose-escalation study. *Ann Oncol* 2019;30:325-331. Available at: <https://www.ncbi.nlm.nih.gov/pubmed/30624546>.

160. Dessources K, Aviki E, Leitao MM, Jr. Lower extremity lymphedema in patients with gynecologic malignancies. *Int J Gynecol Cancer* 2020;30:252-260. Available at: <https://www.ncbi.nlm.nih.gov/pubmed/31915136>.

161. Bona AF, Ferreira KR, Carvalho RBM, et al. Incidence, prevalence, and factors associated with lymphedema after treatment for cervical cancer: a systematic review. *Int J Gynecol Cancer* 2020;30:1697-1704. Available at: <https://www.ncbi.nlm.nih.gov/pubmed/32863276>.

162. Loprinzi CL, Lacchetti C, Bleeker J, et al. Prevention and Management of Chemotherapy-Induced Peripheral Neuropathy in Survivors of Adult Cancers: ASCO Guideline Update. *J Clin Oncol* 2020;38:3325-3348. Available at: <https://www.ncbi.nlm.nih.gov/pubmed/32663120>.

163. Stahl JM, Qian JM, Tien CJ, et al. Extended duration of dilator use beyond 1 year may reduce vaginal stenosis after intravaginal high-dose-

rate brachytherapy. *Support Care Cancer* 2019;27:1425-1433. Available at: <https://www.ncbi.nlm.nih.gov/pubmed/30187220>.

164. Park HS, Ratner ES, Lucarelli L, et al. Predictors of vaginal stenosis after intravaginal high-dose-rate brachytherapy for endometrial carcinoma. *Brachytherapy* 2015;14:464-470. Available at: <https://www.ncbi.nlm.nih.gov/pubmed/25887343>.

165. Dracham CB, Shankar A, Madan R. Radiation induced secondary malignancies: a review article. *Radiat Oncol J* 2018;36:85-94. Available at: <https://www.ncbi.nlm.nih.gov/pubmed/29983028>.

166. Borella F, Preti M, Bertero L, et al. Is There a Place for Immune Checkpoint Inhibitors in Vulvar Neoplasms? A State of the Art Review. *Int J Mol Sci* 2020;22. Available at: <https://www.ncbi.nlm.nih.gov/pubmed/33375467>.

167. Schepisi G, Casadei C, Toma I, et al. Immunotherapy and Its Development for Gynecological (Ovarian, Endometrial and Cervical) Tumors: From Immune Checkpoint Inhibitors to Chimeric Antigen Receptor (CAR)-T Cell Therapy. *Cancers (Basel)* 2021;13. Available at: <https://www.ncbi.nlm.nih.gov/pubmed/33671294>.

168. Lin KY, Frawley HC, Denehy L, et al. Exercise interventions for patients with gynaecological cancer: a systematic review and meta-analysis. *Physiotherapy* 2016;102:309-319. Available at: <https://www.ncbi.nlm.nih.gov/pubmed/27553642>.

169. Nekhlyudov L, Mollica MA, Jacobsen PB, et al. Developing a Quality of Cancer Survivorship Care Framework: Implications for Clinical Care, Research, and Policy. *J Natl Cancer Inst* 2019;111:1120-1130. Available at: <https://www.ncbi.nlm.nih.gov/pubmed/31095326>.

170. Bober SL, Reese JB, Barbera L, et al. How to ask and what to do: a guide for clinical inquiry and intervention regarding female sexual health after cancer. *Current Opinion in Supportive and Palliative Care* 2016;10. Available at: https://journals.lww.com/co-supportiveandpalliativecare/Fulltext/2016/03000/How_to_ask_and_what_to_do_a_guide_for_clinical.12.aspx.



National
Comprehensive
Cancer
Network®

NCCN Guidelines Version 3.2021 Vulvar Cancer (Squamous Cell Carcinoma)

171. Damast S, Jeffery DD, Son CH, et al. Literature Review of Vaginal Stenosis and Dilator Use in Radiation Oncology. *Pract Radiat Oncol* 2019;9:479-491. Available at:
<https://www.ncbi.nlm.nih.gov/pubmed/31302301>.

172. Campbell G, Thomas TH, Hand L, et al. Caring for Survivors of Gynecologic Cancer: Assessment and Management of Long-term and Late Effects. *Semin Oncol Nurs* 2019;35:192-201. Available at:
<https://www.ncbi.nlm.nih.gov/pubmed/30867102>.

173. SGO/FWC Survivorship Toolkit. Available at:
<https://www.sgo.org/resources/survivorship-toolkit/>.