



National Comprehensive  
Cancer Network®

NCCN Clinical Practice Guidelines in Oncology (NCCN Guidelines®)

# Primary Cutaneous Lymphomas

Version 2.2021 — March 4, 2021

**NCCN.org**

**Continue**



National  
Comprehensive  
Cancer  
Network®

# NCCN Guidelines Version 2.2021

## Primary Cutaneous Lymphomas

[NCCN Guidelines Index](#)  
[Table of Contents](#)  
[Discussion](#)

**\*Steven M. Horwitz, MD/Chair † P**  
Memorial Sloan Kettering Cancer Center

**\*Stephen Ansell, MD, PhD/Vice-Chair ‡**  
Mayo Clinic Cancer Center

**Weiyun Z. Ai, MD, PhD † ‡**  
UCSF Helen Diller Family  
Comprehensive Cancer Center

**Jeffrey Barnes, MD, PhD †**  
Massachusetts General Hospital  
Cancer Center

**Stefan K. Barta, MD, MRCP, MS † ‡ P**  
Abramson Cancer Center at the  
University of Pennsylvania

**Mark W. Clemens, MD O**  
The University of Texas  
MD Anderson Cancer Center

**Ahmet Dogan, MD, PhD ≠**  
Memorial Sloan Kettering Cancer Center

**Aaron M. Goodman, MD ‡ §**  
UC San Diego Moores Cancer Center

**Gaurav Goyal, MD † ‡**  
O'Neal Comprehensive Cancer Center at UAB

**\*Joan Guitart, MD ≠**  
Robert H. Lurie Comprehensive Cancer  
Center of Northwestern University

**Ahmad Halwani, MD ‡**  
Huntsman Cancer Institute  
at the University of Utah

**Bradley M. Haverkos, MD, MPH, MS †**  
University of Colorado Cancer Center

**Richard T. Hoppe, MD §**  
Stanford Cancer Institute

**\*Eric Jacobsen, MD †**  
Dana-Farber/Brigham and Women's  
Cancer Center

**\*Deepa Jagadeesh, MD, MPH † ‡**  
Case Comprehensive Cancer Center/University  
Hospitals Seidman Cancer Center and  
Cleveland Clinic Taussig Cancer Institute

**Allison Jones, MD O**  
St. Jude Children's Research Hospital/The  
University of Tennessee Health Science Center

**\*Youn H. Kim, MD O †**  
Stanford Cancer Institute

**Neha Mehta-Shah, MD † ‡**  
Siteman Cancer Center at Barnes-  
Jewish Hospital and Washington  
University School of Medicine

**Elise A. Olsen, MD O †**  
Duke Cancer Institute

**Barbara Pro, MD †**  
Robert H. Lurie Comprehensive Cancer  
Center of Northwestern University

**Saurabh A. Rajguru, MD † ‡**  
University of Wisconsin  
Carbone Cancer Center

**Sima Rozati, MD, PhD O**  
The Sidney Kimmel Comprehensive  
Cancer Center at Johns Hopkins

**Jonathan Said, MD ≠**  
UCLA Jonsson Comprehensive Cancer Center

**Aaron Shaver, MD, PhD ≠**  
Vanderbilt-Ingram Cancer Center

**Andrei Shustov, MD †**  
Fred Hutchinson Cancer Research Center/  
Seattle Cancer Care Alliance

**Lubomir Sokol, MD, PhD † ‡ P**  
Moffitt Cancer Center

**Pallawi Torka, MD †**  
Roswell Park Cancer Institute

**Carlos Torres-Cabala, MD ≠**  
The University of Texas  
MD Anderson Cancer Center

**Ryan Wilcox, MD, PhD †**  
University of Michigan  
Rogel Cancer Center

**Basem M. William, MD ‡**  
The Ohio State University Comprehensive  
Cancer Center - James Cancer Hospital  
and Solove Research Institute

**\*Jasmine Zain, MD † ‡**  
City of Hope National Medical Center

**NCCN**  
**Mary Dwyer, MS**  
**Hema Sundar, PhD**

[NCCN Guidelines Panel Disclosures](#)

**Continue**

§ Bone marrow transplantation	≠ Pathology
O Dermatology	O Plastic surgery
‡ Hematology/Hematology oncology	§ Radiotherapy/Radiation oncology
P Internal medicine	* Discussion Writing Committee Member
† Medical oncology	



National  
Comprehensive  
Cancer  
Network®

# NCCN Guidelines Version 2.2021

## Primary Cutaneous Lymphomas

[NCCN Guidelines Index](#)  
[Table of Contents](#)  
[Discussion](#)

### [NCCN Primary Cutaneous Lymphomas Panel Members](#) [Summary of the Guidelines Updates](#)

#### Primary Cutaneous B-Cell Lymphomas

- [Diagnosis and Workup \(CUTB-1\)](#)
- [Primary Cutaneous Marginal Zone Lymphoma \(CUTB-2\)](#)
- [Primary Cutaneous Follicle Center Lymphoma \(CUTB-2\)](#)
- [TNM Classification of Cutaneous Lymphoma other than MF/SS \(CUTB-A\)](#)
- [Treatment References \(CUTB-B\)](#)

#### Mycosis Fungoides/Sézary Syndrome (MF/SS)

- [Overview of Definition and Diagnosis \(MFSS/INTRO-1\)](#)
- [General Principles \(MFSS/INTRO-2\)](#)
- [Diagnosis \(MFSS-1\)](#)
- [Workup \(MFSS-2\)](#)
- [TNMB Classification and Staging \(MFSS-3\)](#)
- [Clinical Staging \(MFSS-4\)](#)
- [Stage IA \(Limited Skin Involvement Alone, <10% BSA\) \(MFSS-6\)](#)
- [Stage IB \(Skin Only Disease with ≥10% BSA\) - Stage IIA \(MFSS-7\)](#)
- [Stage IIB \(Tumor Stage Disease\) \(MFSS-8\)](#)
- [Stage III \(Erythrodermic Disease\) \(MFSS-10\)](#)
- [Stage IV \(MFSS-11\)](#)
- [Large Cell Transformation \(LCT\) \(MFSS-12\)](#)
- [Suggested Treatment Regimens \(MFSS-A\)](#)
- [Supportive Care \(MFSS-B\)](#)

#### Primary Cutaneous CD30+ T-Cell Lymphoproliferative Disorders

- [Overview and Definition \(PCTLD/INTRO-1\)](#)
- [Diagnosis \(PCTLD-1\)](#)
- [Workup \(PCTLD-2\)](#)
- [Primary Cutaneous ALCL \(PCTLD-3\)](#)
- [Lymphomatoid Papulosis \(PCTLD-4\)](#)
- [Therapy References \(PCTLD-A\)](#)

- [Principles of Radiation Therapy \(PCLYM-A\)](#)
- [Principles of Molecular Analysis in T-Cell Lymphomas \(PCLYM-B\)](#)
- [Supportive Care for Patients With Cutaneous Lymphomas \(PCLYM-C\)](#)

[Use of Immunophenotyping/Genetic Testing in Differential Diagnosis of Mature B-Cell and NK/T-Cell Neoplasms \(See NCCN Guidelines for B-Cell Lymphomas - NHODG-A\)](#)

[For Primary Cutaneous Diffuse Large B-Cell Lymphoma, Leg Type \(See NCCN Guidelines for B-Cell Lymphomas - DLBCL\)](#)

[Classification \(ST-1\)](#)

**Clinical Trials:** NCCN believes that the best management for any patient with cancer is in a clinical trial. Participation in clinical trials is especially encouraged.

To find clinical trials online at NCCN Member Institutions, [click here: nccn.org/clinical\\_trials/member\\_institutions.html](#).

**NCCN Categories of Evidence and Consensus:** All recommendations are category 2A unless otherwise specified.

See [NCCN Categories of Evidence and Consensus](#).

**NCCN Categories of Preference:** All recommendations are considered appropriate.  
[See NCCN Categories of Preference](#).

The NCCN Guidelines® are a statement of evidence and consensus of the authors regarding their views of currently accepted approaches to treatment. Any clinician seeking to apply or consult the NCCN Guidelines is expected to use independent medical judgment in the context of individual clinical circumstances to determine any patient's care or treatment. The National Comprehensive Cancer Network® (NCCN®) makes no representations or warranties of any kind regarding their content, use or application and disclaims any responsibility for their application or use in any way. The NCCN Guidelines are copyrighted by National Comprehensive Cancer Network®. All rights reserved. The NCCN Guidelines and the illustrations herein may not be reproduced in any form without the express written permission of NCCN. ©2021.



# NCCN Guidelines Version 2.2021

## Primary Cutaneous Lymphomas

Updates in Version 2.2021 of the NCCN Guidelines for Primary Cutaneous Lymphomas from Version 1.2021 include:

### MS-1

- The Discussion section has been updated to reflect the changes in the algorithm.

Updates in Version 1.2021 of the NCCN Guidelines for Primary Cutaneous Lymphomas from Version 2.2020 include:

### Global changes

- Suggested treatment regimen references were updated throughout the guidelines.

### Primary Cutaneous B-Cell Lymphomas

#### CUTB-1

- Workup, Useful, "Discussion of fertility and sperm banking, if fertility-impacting therapy is planned" was added.

#### CUTB-3

- Footnote n, "An FDA-approved biosimilar is an appropriate substitute for rituximab" was added.

### Mycosis Fungoides/Sézary Syndrome

#### MFSS/INTRO-2

##### • General Principles

- ▶ 4th bullet was added, "Folliculotropic MF (FMF) and LCT are histologic features that can occur irrespective of stage."
- ▶ 5th bullet was revised, "~~Folliculotropism is a histologic feature that can occur irrespective of stage. Histologic evidence of folliculotropic MF is may be associated with higher risk of disease progression. Recent studies have reported that FMF presents with two distinct patterns of clinicopathologic features with different prognostic implications (early stage and advanced stage); in a subgroup of patients with early skin-limited disease, FMF has an indolent disease course and a favorable prognosis. Treatment...~~"
- ▶ 6th bullet was revised, "~~The incidence of LCT is strongly dependent on the disease stage at diagnosis. LCT is a histologic feature that often but not always...~~"

#### MFSS-1

##### • Diagnosis, Essential

- ▶ 2nd bullet was revised from "Dermatopathology review of slides" to "Review of all slides with at least one paraffin block representative of the tumor should be done by a pathologist with expertise in the diagnosis of CTCLs. Rebiopsy if consult material in conjunction with the clinical picture is nondiagnostic."
- ▶ 4th bullet for "Molecular analysis to detect clonal T-cell antigen receptor (TCR) gene rearrangements or other assessment of clonality" was revised by removing the detection methods and clarifying the methods in the Principles of Molecular Analysis in Cutaneous Lymphomas (PCLYM-B). Also for PCTLD-1.

#### MFSS-1

##### • Diagnosis, Useful

- ▶ 1st bullet, 2nd sub-bullet was revised, "Flow cytometry *and molecular analysis is useful* to assess..."
- ▶ 2nd bullet, 1st sub-bullet was revised by adding, "CXCL13, ICOS, and PD-1."
- ▶ 4th bullet was revised, "Assessment of HTLV-1/2 by serology or other methods *is encouraged in at-risk populations, as results can impact therapy.*" Also for PCTLD-1
- ▶ Footnote h was revised by adding, "HTLV-1 has been described in patients in non-endemic areas." Also for PCTLD-1.

#### MFSS-2

- Footnote k was revised, "Patients with T-cell *cutaneous* lymphomas ~~often~~ have extranodal disease..."

#### MFSS-7

- Footnote z was moved from MFSS-9 and added to higher skin disease burden, "Patients with indolent/plaque folliculotropic MF (without evidence of LCT) should first be considered for therapies under SYST-CAT A before proceeding to treatments listed in SYST-CAT B. See MFSS-A (2 of 6)."

#### MFSS-9

- Additional therapy, "Regimens for relapsed/refractory disease requiring systemic therapy" was added as an option after relapsed disease to multiple previous therapies. Also for MFSS-10, MFSS-11, and MFSS-12.

#### MFSS-10

- Footnote gg was added, "Olsen E, Whittaker S, Kim Y, et al. J Clin Oncol 2011;29:2598-2607." Also for MFSS-11.

#### MFSS-11

- For Sézary syndrome, "Stage IVA1 or IVA2" was added.
- For Non-Sézary, "Stage IVA2" was added and for Visceral disease, "stage IVB" was added.
- Primary treatment
  - ▶ Non-Sézary, "± RT for local control" was added to "Systemic therapies (SYST-CAT B, MFSS-A)."

#### MFSS-12

- Primary treatment
  - ▶ Limited cutaneous lesions revised, "~~Consider~~ RT (~~preferred~~) to lesions with LCT."

[Continued](#)



# NCCN Guidelines Version 2.2021

## Primary Cutaneous Lymphomas

Updates in Version 1.2021 of the NCCN Guidelines for Primary Cutaneous Lymphomas from Version 2.2020 include:

### [MFSS-A 2 of 6](#)

- Relapsed/refractory disease requiring systemic therapy, "pembrolizumab" was changed from a category 2B to a category 2A recommendation.
- Footnote b was revised by adding, "Laboratory studies for triglycerides, and thyroid function tests (with free thyroxine T4) are recommended for patients receiving bexarotene."
- Footnote h was revised, "...combining phototherapy with vorinostat, romidepsin, or mogamulizumab is unknown."
- Footnote p was revised by adding, "While alemtuzumab is no longer commercially available, it may be obtained for clinical use. Recommend CMV monitoring or prophylaxis."

### [Primary Cutaneous CD30+ T-Cell Lymphoproliferative Disorders](#)

#### [PCTLD-1](#)

- Diagnosis, Essential
  - ▶ 4th bullet was revised, "...Rebiopsy if consult material *in conjunction with the clinical picture* is nondiagnostic." Also for Cutaneous ALCL, Workup on PCTLD-2.

#### [PCTLD-2](#)

- Workup, after PET/CT, "(arms/legs included when disease assessment of entire body is needed)" was added.

### [Principles of Radiation Therapy](#)

#### [PCLYM-A 1 of 3](#)

- Target volumes, 4th sub-bullet was revised by adding, "If using CT-based planning, delineating tumor boundary with wire for CT simulation will guide treatment volumes."

#### [PCLYM-A 2 of 3](#)

- General Dose Guidelines:
  - ▶ PCMZL and PCFCL, 1st sub-bullet, 4th tertiary bullet was added, "Doses as low as 4 Gy are used occasionally, but data are limited regarding response and duration."
  - ▶ MFSS, 1st sub-bullet, 1st tertiary bullet was revised, "... 8 Gy may be given in a single 1-2 fractions."
  - ▶ Primary cutaneous ALCL, 3rd sub-bullet was added, "Doses as low as 6 Gy are used occasionally, but data are limited regarding response and duration."

### [Principles of Molecular Analysis](#)

#### [PCLYM-B 1 of 3](#)

- 1st bullet was revised, "Genetic testing, including high-throughput sequencing (HTS) or NGS ~~and FISH that detect somatic gene abnormalities~~ *array-based comparative genomic hybridization (CGH) or next-generation sequencing (NGS), karyotype or FISH to detect somatic mutations or genetic abnormalities* are often informative..."
- 6th bullet, 1st sub-bullet, "Determination of clonal TCR gene rearrangement is an ancillary confirmatory test without prognostic value, except when used to assess relapsed or residual disease. Identification of clonal TCR gene rearrangement has no definitive established prognostic value however it could be helpful when used to determine clinical staging or assess relapsed or residual disease" was changed to "Identification of clonal TCR gene rearrangement has no definitive established prognostic value; however, it could be helpful when used to determine clinical staging or assess relapsed or residual disease."

#### [PCLYM-B 2 of 3](#)

- TP63 rearrangement, "or mRNA sequencing by HTS technologies" was replaced with "targeted mRNA sequencing."

### [Supportive Care](#)

#### [PCLYM-C](#)

- Section was removed, "Methotrexate: Renal dysfunction associated with methotrexate: Consider use of glucarpidase if significant renal dysfunction and methotrexate levels are >10 microM beyond 42 to 48 hours. Leucovorin remains a component in the treatment of methotrexate toxicity and should be continued for at least 2 days following glucarpidase administration. However, be aware that leucovorin is a substrate for glucarpidase, and therefore should not be administered within two hours prior to or following glucarpidase."
- A new section for Prevention of Pralatrexate-Induced Mucositis was added.

### [Staging](#)

- "Lugano Modification of Ann Arbor Staging System" was removed.





# NCCN Guidelines Version 2.2021

## Primary Cutaneous B-Cell Lymphomas

### DIAGNOSIS<sup>a</sup>

#### ESSENTIAL:

- Review of all slides with at least one paraffin block representative of the tumor should be done by a pathologist with expertise in the diagnosis of primary cutaneous B-cell lymphoma. Rebiopsy if consult material is nondiagnostic.
- Adequate biopsy (punch, incisional, excisional) of clinical lesions
- Adequate immunophenotyping to establish diagnosis<sup>b</sup>
  - ▶ IHC panel: CD20, CD3, CD10, BCL2, BCL6, IRF4/MUM1

#### USEFUL IN CERTAIN CIRCUMSTANCES:

- Additional immunohistochemical studies to establish lymphoma subtype
  - ▶ IHC panel may include: Ki-67, CD5, CD43, CD21, CD23, cyclin D1, kappa/lambda (IHC or ISH), EBER-ISH
  - ▶ Assessment of IgM, IgD, and FOXP1 expression (to further help in distinguishing PC-DLBCL, leg type from PCFCL)
- Cytogenetics (FISH and karyotype): t(14;18) if systemic FL is suspected
- If adequate biopsy material available, flow cytometry or *IgH* gene rearrangement studies can be useful in determining B-cell clonality.

### WORKUP

#### ESSENTIAL:<sup>c</sup>

- History and physical exam, including complete skin exam
- CBC with differential
- Comprehensive metabolic panel
- LDH
- Chest/abdominal/pelvic CT with contrast and/or PET/CT scan (may be omitted if clinically indicated)
- Pregnancy testing in women of childbearing age (if chemotherapy or RT planned)

#### USEFUL IN SELECTED CASES:

- Bone marrow biopsy<sup>d</sup>
- Peripheral blood flow cytometry, if CBC demonstrates lymphocytosis
- SPEP/quantitative immunoglobulins for PCMZL
- HIV testing
- Hepatitis B and C testing<sup>e</sup>
- Discussion of fertility and sperm banking, if fertility-impacting therapy is planned

[Primary Cutaneous Marginal Zone Lymphoma \(PCMZL\) \(CUTB-2\)](#)

[Primary Cutaneous Follicle Center Lymphoma \(PCFCL\) \(CUTB-2\)](#)

[Primary Cutaneous Diffuse Large B-Cell Lymphoma \(PC-DLBCL\), Leg Type \(See \[NCCN Guidelines for B-Cell Lymphomas - DLBCL\]\(#\)\)](#)

<sup>a</sup> For non-cutaneous extranodal B-cell lymphomas, [see Nongastric MALT Lymphoma in the NCCN Guidelines for B-Cell Lymphomas](#). A germinal (or follicle) center phenotype and large cells in a skin lesion is not equivalent to DLBCL but is consistent with primary cutaneous germinal/follicle center lymphoma.

<sup>b</sup> [See Use of Immunophenotyping/Genetic Testing in Differential Diagnosis of Mature B-Cell and NK/T-Cell Neoplasms \(See NCCN Guidelines for B-Cell Lymphomas\)](#).

<sup>c</sup> Rule out drug-induced cutaneous lymphoid hyperplasia.

<sup>d</sup> Often reserved for patient with unexplained cytopenias or if there is clinical suspicion of other subtypes (eg, PC-DLBCL, leg type).

<sup>e</sup> Hepatitis B testing is indicated because of the risk of reactivation with immunotherapy + chemotherapy. See monoclonal antibody and viral reactivation in the [NCCN Guidelines B-Cell Lymphomas](#). Tests include hepatitis B surface antigen and core antibody for a patient with no risk factors. For patients with risk factors or previous history of hepatitis B, add e-antigen. If positive, check viral load and consult with gastroenterologist.

**Note:** All recommendations are category 2A unless otherwise indicated.

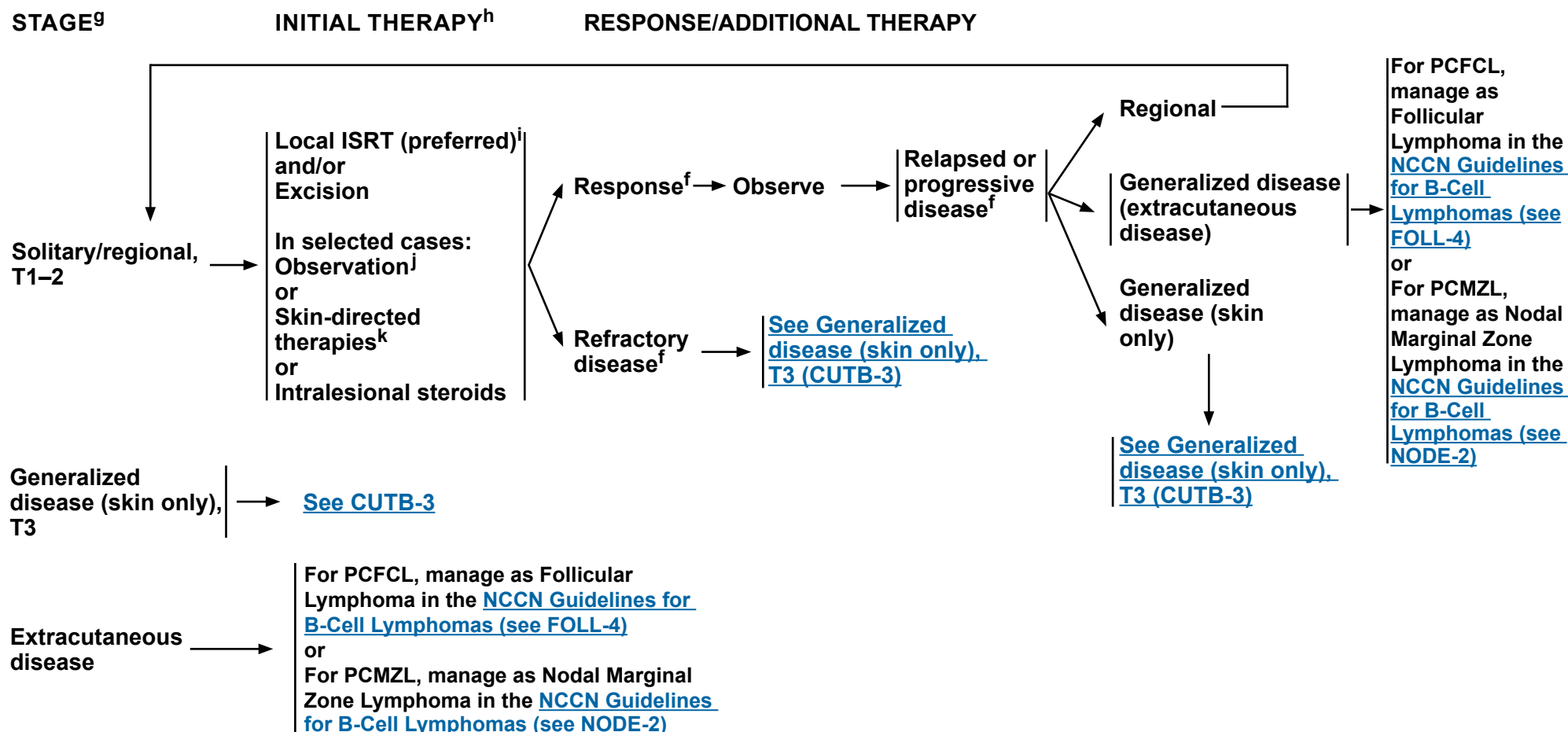
**Clinical Trials:** NCCN believes that the best management of any patient with cancer is in a clinical trial. Participation in clinical trials is especially encouraged.



# NCCN Guidelines Version 2.2021

## Primary Cutaneous B-Cell Lymphomas

### PRIMARY CUTANEOUS MARGINAL ZONE LYMPHOMA OR FOLLICLE CENTER LYMPHOMA<sup>f</sup>



<sup>f</sup> Additional imaging studies during the course of treatment are not needed. PET/CT (strongly preferred) or C/A/P CT with contrast at the end of treatment are needed to assess response. This can be repeated if there is clinical suspicion of progressive disease.

<sup>g</sup> [See TNM Classification of Cutaneous Lymphoma other than MF/SS \(CUTB-A\).](#)

<sup>h</sup> [See Treatment References \(CUTB-B\).](#)

<sup>i</sup> Local RT is the preferred initial treatment, but not necessarily the preferred treatment for relapse. [See Principles of Radiation Therapy \(PCLYM-A\).](#)

<sup>j</sup> When RT or surgical treatment is neither feasible nor desired.

<sup>k</sup> There are case reports showing efficacy of topicals, which include steroids, imiquimod, nitrogen mustard, and bexarotene (useful in pediatric patients).

**Note:** All recommendations are category 2A unless otherwise indicated.

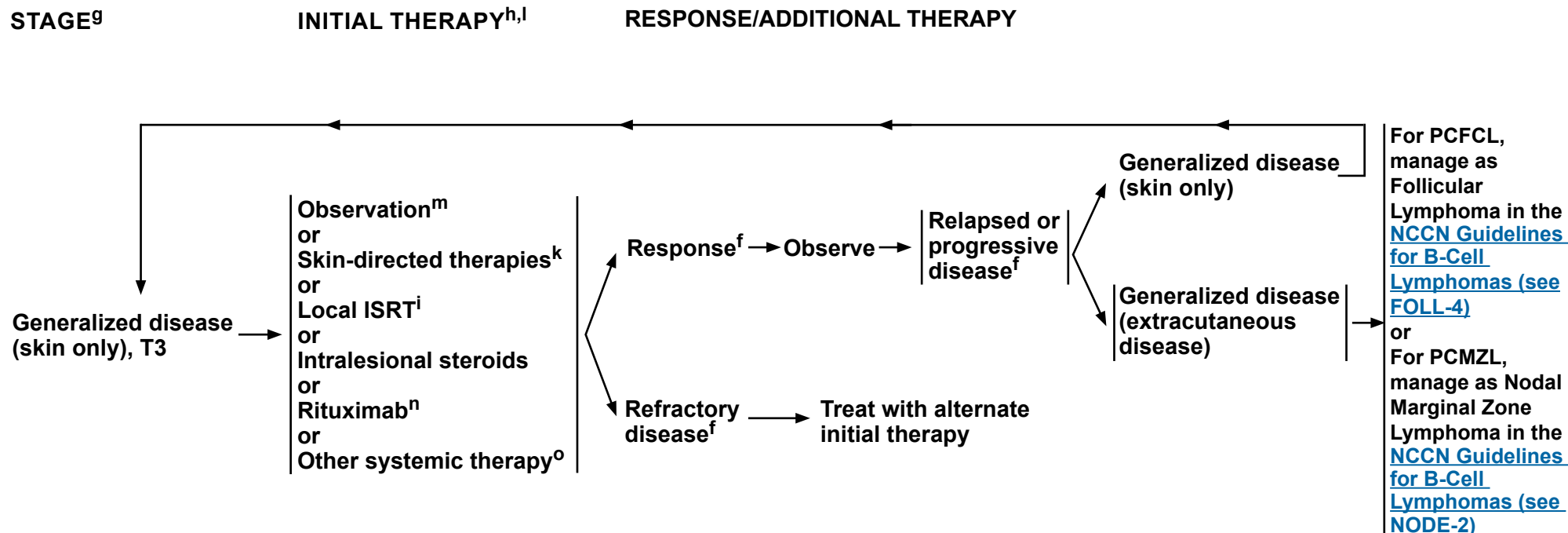
**Clinical Trials:** NCCN believes that the best management of any patient with cancer is in a clinical trial. Participation in clinical trials is especially encouraged.



# NCCN Guidelines Version 2.2021

## Primary Cutaneous B-Cell Lymphomas

### PRIMARY CUTANEOUS MARGINAL ZONE LYMPHOMA OR FOLLICLE CENTER LYMPHOMA<sup>f</sup>



<sup>f</sup> Additional imaging studies during the course of treatment are not needed. PET/CT (strongly preferred) or C/A/P CT with contrast at the end of treatment are needed to assess response. This can be repeated if there is clinical suspicion of progressive disease.

<sup>g</sup> See [TNM Classification of Cutaneous Lymphoma other than MF/SS \(CUTB-A\)](#).

<sup>h</sup> See [Treatment References \(CUTB-B\)](#).

<sup>i</sup> Local ISRT is the preferred initial treatment, but not necessarily the preferred treatment for relapse. See [Principles of Radiation Therapy \(PCLYM-A\)](#).

<sup>k</sup> There are case reports showing efficacy of topicals, which include steroids, imiquimod, nitrogen mustard, and bexarotene (useful in pediatric patients).

<sup>l</sup> See monoclonal antibody and viral reactivation (See [NCCN Guidelines B-Cell Lymphomas](#)).

<sup>m</sup> Considered appropriate in asymptomatic patients.

<sup>n</sup> Rituximab and hyaluronidase human injection for subcutaneous use may be substituted for rituximab after patients have received the first full dose of rituximab by intravenous infusion. This substitution cannot be made for rituximab used in combination with ibritumomab tiuxetan. An FDA-approved biosimilar is an appropriate substitute for rituximab.

<sup>o</sup> In rare circumstances for very extensive or refractory disease, other combination chemotherapy regimens listed in [NCCN Guidelines for B-Cell Lymphomas, FOLL-B](#) are used.

**Note:** All recommendations are category 2A unless otherwise indicated.

**Clinical Trials:** NCCN believes that the best management of any patient with cancer is in a clinical trial. Participation in clinical trials is especially encouraged.





# NCCN Guidelines Version 2.2021

## Primary Cutaneous B-Cell Lymphomas

### TNM CLASSIFICATION OF CUTANEOUS LYMPHOMA OTHER THAN MF/SS<sup>a,b</sup>

<b>T</b>	
<b>T1</b>	<b>Solitary skin involvement</b> T1a: a solitary lesion <5 cm diameter T1b: a solitary >5 cm diameter
<b>T2</b>	<b>Regional skin involvement: multiple lesions limited to 1 body region or 2 contiguous body regions<sup>b</sup></b> T2a: all-disease-encompassing in a <15-cm-diameter circular area T2b: all-disease-encompassing in a >15- and <30-cm-diameter circular area T2c: all-disease-encompassing in a >30-cm-diameter circular area
<b>T3</b>	<b>Generalized skin involvement</b> T3a: multiple lesions involving 2 noncontiguous body regions <sup>b</sup> T3b: multiple lesions involving ≥3 body regions <sup>b</sup>
<b>N</b>	
<b>N0</b>	<b>No clinical or pathologic lymph node involvement</b>
<b>N1</b>	<b>Involvement of 1 peripheral lymph node region<sup>c</sup> that drains an area of current or prior skin involvement</b>
<b>N2</b>	<b>Involvement of 2 or more peripheral lymph node regions<sup>c</sup> or involvement of any lymph node region that does not drain an area of current or prior skin involvement</b>
<b>N3</b>	<b>Involvement of central lymph nodes</b>
<b>M</b>	
<b>M0</b>	<b>No evidence of extracutaneous non-lymph node disease</b>
<b>M1</b>	<b>Extracutaneous non-lymph node disease present</b>

<sup>a</sup> This work was originally published in Blood. Kim YH, Willemze R, Pimpinell Ni, et al, for the ISCL and the EORTC. TNM classification system for primary cutaneous lymphomas other than mycosis fungoides and Sézary syndrome: A proposal of the International Society for Cutaneous Lymphomas (ISCL) and the Cutaneous Lymphoma Task Force of the European Organization of Research and Treatment of Cancer (EORTC) Blood 2007;110:479-484. © The American Society of Hematology.

<sup>b</sup> For definition of body regions, [see Body Regions for the Designation of T \(Skin Involvement\) Category \(CUTB-A 2 of 2\)](#).

<sup>c</sup> Definition of lymph node regions is consistent with the Ann Arbor system: Peripheral sites: antecubital, cervical, supraclavicular, axillary, inguinal-femoral, and popliteal. Central sites: mediastinal, pulmonary hilar, paraortic, and iliac.

**Note:** All recommendations are category 2A unless otherwise indicated.

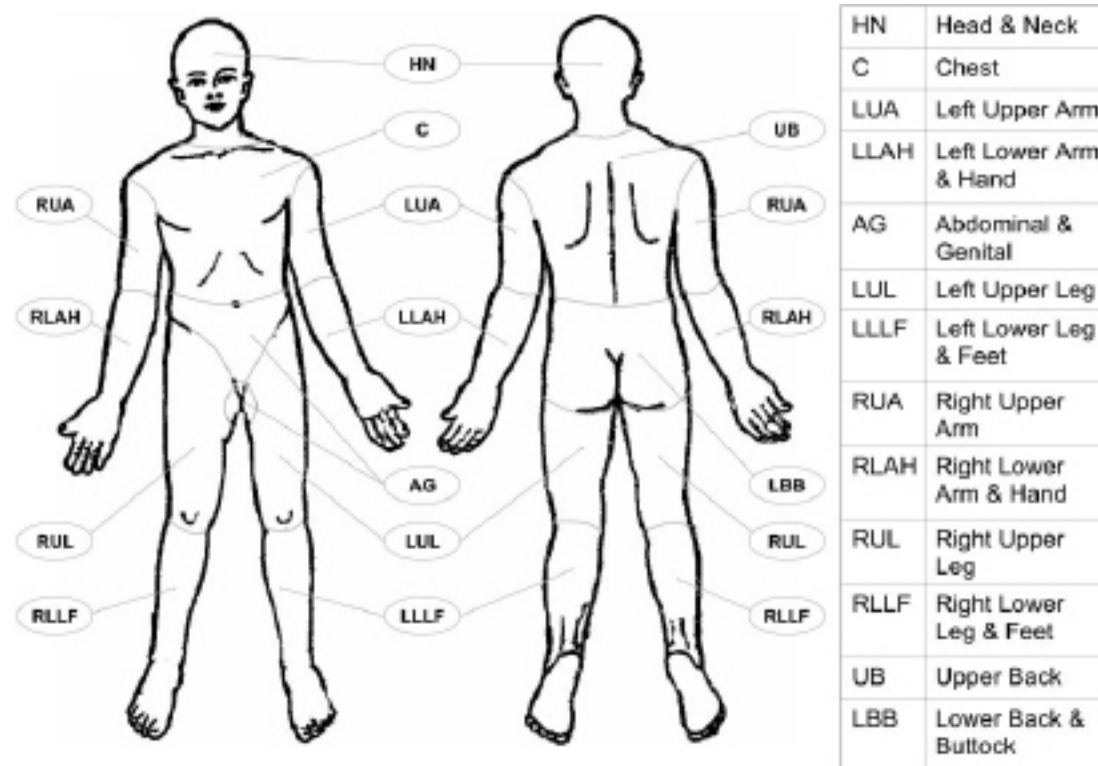
**Clinical Trials:** NCCN believes that the best management of any patient with cancer is in a clinical trial. Participation in clinical trials is especially encouraged.



# NCCN Guidelines Version 2.2021

## Primary Cutaneous B-Cell Lymphomas

### BODY REGIONS FOR THE DESIGNATION OF T (SKIN INVOLVEMENT) CATEGORY<sup>a,d,e</sup>



<sup>a</sup> This work was originally published in Blood. Kim YH, Willemze R, Pimpinell Ni, et al, for the ISCL and the EORTC. TNM classification system for primary cutaneous lymphomas other than mycosis fungoides and Sézary syndrome: A proposal of the International Society for Cutaneous Lymphomas (ISCL) and the Cutaneous Lymphoma Task Force of the European Organization of Research and Treatment of Cancer (EORTC) Blood 2007;110:479-484. © The American Society of Hematology.

<sup>d</sup> Left and right extremities are assessed as separate body regions. The designation of these body regions is based on regional lymph node drainage patterns.

<sup>e</sup> Definition of body regions: Head and neck: inferior border—superior border of clavicles, T1 spinous process. Chest: superior border—superior border of clavicles; inferior border—inferior margin of rib cage; lateral borders—midaxillary lines, glenohumeral joints (inclusive of axillae). Abdomen/genital: superior border—inferior margin of rib cage; inferior border—inguinal folds, anterior perineum; lateral borders—mid-axillary lines. Upper back: superior border—T1 spinous process; inferior border—inferior margin of rib cage; lateral borders—mid-axillary lines. Lower back/buttocks: superior border—inferior margin of rib cage; inferior border—inferior gluteal fold, anterior perineum (inclusive of perineum); lateral borders—midaxillary lines. Each upper arm: superior borders—glenohumeral joints (exclusive of axillae); inferior borders—ulnar/radial-humeral (elbow) joint. Each lower arm/hand: superior borders—ulnar/radial-humeral (elbow) joint. Each upper leg (thigh): superior borders—inguinal folds, inferior gluteal folds; inferior borders—mid-patellae, midpopliteal fossae. Each lower leg/foot: superior borders—mid-patellae, mid-popliteal fossae.

**Note:** All recommendations are category 2A unless otherwise indicated.

**Clinical Trials:** NCCN believes that the best management of any patient with cancer is in a clinical trial. Participation in clinical trials is especially encouraged.



# NCCN Guidelines Version 2.2021

## Primary Cutaneous B-Cell Lymphomas

### TREATMENT REFERENCES

#### Topicals

##### *Topical/intralesional corticosteroids*

Bekkenk MW, Vermeer MH, Geerts ML, et al. Treatment of multifocal primary cutaneous B-cell lymphoma: a clinical follow-up study of 29 patients. *J Clin Oncol* 1999;17:2471-2478.

Perry A, Vincent BJ, Parker SR. Intralesional corticosteroid therapy for primary cutaneous B-cell lymphoma. *Br J Dermatol* 2010;163:223-225.

##### *Topical nitrogen mustard*

Bachmeyer C, Orlandini V, Aractingi S. Topical mechlorethamine and clobetasol in multifocal primary cutaneous marginal zone-B cell lymphoma. *B J Dermatol* 2006;154:1207-1209.

##### *Topical bexarotene*

Trent JT, Romanelli P, Kerdel FA. Topical targretin and intralesional interferon alfa for cutaneous lymphoma of the scalp. *Arch Dermatol* 2002;138:1421-1423.

##### *Topical imiquimod*

Coors EA, Schuler G, Von Den Driesch P. Topical imiquimod as treatment for different kinds of cutaneous lymphoma. *Eur J Dermatol* 2006;16:391-393.

Stavrakoglou A, Brown VL, Coutts I. Successful treatment of primary cutaneous follicle centre lymphoma with topical 5% imiquimod. *Br J Dermatol* 2007;157:620-622.

#### Rituximab

Morales AV, Advani R, Horwitz SM, et al. Indolent primary cutaneous B-cell lymphoma: experience using systemic rituximab. *J Am Acad Dermatol* 2008;59:953-957.

Heinzerling LM, Urbanek M, Funk JO, et al. Reduction of tumor burden and stabilization of disease by systemic therapy with anti-CD20 antibody (rituximab) in patients with primary cutaneous B-cell lymphoma. *Cancer* 2000;89:1835-1844.

Valencak J, Weihsengruber F, Rappersberger K, et al. Rituximab monotherapy for primary cutaneous B-cell lymphoma: Response and follow-up in 16 patients. *Ann Oncol* 2009;20:326-330.

Senff NJ, Noordijk EM, Kim YH, et al. European Organization for Research and Treatment of Cancer and International Society for Cutaneous Lymphoma consensus recommendations for the management of cutaneous B-cell lymphomas. *Blood* 2008;112:1600-1609.

Heinzerling L, Dummer R, Kempf W, Schmid MH, Burg G. Intralesional therapy with anti-CD20 monoclonal antibody rituximab in primary cutaneous B-cell lymphoma. *Arch Dermatol* 2000;136:374-378.

#### Chemotherapy/Chemoimmunotherapy

Bekkenk MW, Vermeer MH, Geerts ML, et al. Treatment of multifocal primary cutaneous B-cell lymphoma: a clinical follow-up study of 29 patients. *J Clin Oncol* 1999;17:2471-2478.

Brice P, Cazals D, Mounier N, et al. Primary cutaneous large-cell lymphoma: analysis of 49 patients included in the LNH87 prospective trial of polychemotherapy for high-grade lymphomas. *Groupe d'Etude des Lymphomes de l'Adulte. Leukemia* 1998;12:213-219.

Hoefnagel JJ, Vermeer MH, Jansen PM, et al. Primary cutaneous marginal zone B-cell lymphoma: Clinical and therapeutic features in 50 cases. *Arch Dermatol* 2005;141:1139-1145.

Grange F, Beylot-Barry M, Courville P, et al. Primary cutaneous diffuse large B-cell lymphoma, leg type: clinicopathologic features and prognostic analysis in 60 cases. *Arch Dermatol* 2007;143:1144-1150.

Grange F, Joly P, Barbe C, et al. Improvement of survival in patients with primary cutaneous diffuse large B-cell lymphoma, leg type, in France. *JAMA Dermatol* 2014;150:535-541.

Rijlaarsdam JU, Toonstra J, Meijer OW, Noordijk EM, Willemze R. Treatment of primary cutaneous B-cell lymphomas of follicle center cell origin: A clinical follow-up study of 55 patients treated with radiotherapy or polychemotherapy. *J Clin Oncol* 1996;14:549-555.

Senff NJ, Noordijk EM, Kim YH, et al. European Organization for Research and Treatment of Cancer and International Society for Cutaneous Lymphoma consensus recommendations for the management of cutaneous B-cell lymphomas. *Blood* 2008;112:1600-1609.

Vermeer MH, Geelen FA, van Haselen CW, et al. Primary cutaneous large B-cell lymphomas of the legs. A distinct type of cutaneous B-cell lymphoma with an intermediate prognosis. Dutch Cutaneous Lymphoma Working Group. *Arch Dermatol* 1996;132:1304-1308.

#### Palliative low-dose RT

Neelis KJ, Schimmel EC, Vermeer MH, et al. Low-dose palliative radiotherapy for cutaneous B- and T-cell lymphomas. *Int J Radiat Oncol Biol Phys* 2009;74:154-158.

**Note:** All recommendations are category 2A unless otherwise indicated.

**Clinical Trials:** NCCN believes that the best management of any patient with cancer is in a clinical trial. Participation in clinical trials is especially encouraged.



# NCCN Guidelines Version 2.2021

## Mycosis Fungoides/Sezary Syndrome

### PRINCIPLES FOR MYCOSIS FUNGOIDES/SÉZARY SYNDROME

#### Definition

- **Mycosis fungoides (MF)**
  - MF is the most common cutaneous T-cell lymphoma (CTCL) and many clinicopathologic variants of MF have been described.<sup>a</sup>
  - Most patients with MF exhibit an indolent clinical course with intermittent, stable, or slow progression of the lesions.
  - Extracutaneous involvement may be seen in advanced stages, with involvement of lymph nodes, blood, or less commonly other organs.<sup>a</sup>
- **Sézary syndrome (SS)**
  - SS is closely related to MF but has unique characteristics. SS is rare, accounting for less than 5% of cutaneous lymphomas and predominantly affects older individuals.
  - SS is characterized by the presence of atypical T cells (Sézary cells) in skin causing diffuse erythema (erythroderma) and significant blood involvement with abnormal T cells (>1000 abnormal cells/uL) defined as Sézary cells by cytopathologic assessment or flow cytometry (abnormal subsets including but not limited to CD4+CD7- or CD4+CD26- cells).<sup>b</sup>
  - SS is thought to arise from thymic memory T cells, while skin resident effector memory T cells are the cells of origin of MF. This supports the contention that SS is a process distinct from MF.<sup>c</sup> Cases presenting clinically as an overlap of these two conditions exist.

#### Diagnosis

- The histopathologic findings of MF, even in cases showing classic features, need to be correlated with clinical presentation in order to reach a definitive diagnosis.<sup>d</sup>
- Patch lesions are often difficult for conclusive diagnosis; thus, in some instances multiple skin biopsies may be necessary for diagnosis. Stopping skin-directed therapy for 2–3 weeks or longer to individual lesions before obtaining a skin biopsy is advisable and may aid in diagnosis.<sup>a</sup>
- Awareness of specific clinicopathologic variants may aid in accurate diagnosis:
  - Lesions may be hyper- or hypopigmented.
  - Folliculotropic MF may present as folliculocentric papules or nodules or areas of alopecia in any hair-bearing area of the body.
  - Unilesional, pagetoid reticulosis and CD8+ MF variants tend to be associated with an indolent course.
  - Granulomatous slack skin is rare and presents with redundant skin resembling cutis laxa on flexural areas.
- The tumor cells are usually CD3+, CD4+, and CD8-, although CD8+ variants are not uncommon.
- Large-cell transformation (LCT) of MF is defined histologically as greater than 25% of the tumor cells displaying large size. CD30 expression may be seen but is not included in the definition of LCT.
- The histopathologic findings of SS in skin are generally similar to, but may be more subtle than those seen in MF. Correlation with clinical and laboratory findings in blood is essential for a definitive diagnosis.

[See General Principles \(MFSS/INTRO-2\)](#)

<sup>a</sup> Swerdlow SH, Campo E, Pileri SA, et al. The 2016 revision of the World Health Organization classification of lymphoid neoplasms. *Blood* 2016;127:2375-2390.

<sup>b</sup> Olsen E, Whittaker S, Kim YH, et al. *J Clin Oncol* 2011;29:2598-2607.

<sup>c</sup> Campbell JJ, Clark RA, Watanabe R, Kupper TS. Sezary syndrome and mycosis fungoides arise from distinct T-cell subsets: a biologic rationale for their distinct clinical behaviors. *Blood* 2010;116:767-771.

<sup>d</sup> Pimpinelli N, Olsen EA, Santucci M, et al. Defining early mycosis fungoides. *J Am Acad Dermatol* 2005;53:1053-1063.

**Note:** All recommendations are category 2A unless otherwise indicated.

**Clinical Trials:** NCCN believes that the best management of any patient with cancer is in a clinical trial. Participation in clinical trials is especially encouraged.



# NCCN Guidelines Version 2.2021

## Mycosis Fungoides/Sezary Syndrome

### PRINCIPLES FOR MYCOSIS FUNGOIDES/SÉZARY SYNDROME

#### General principles

- A multidisciplinary team approach involving hematology/oncology, dermatology, and radiation oncology is often optimal for the management of patients with MF/SS, particularly those with advanced disease.
- Given the rarity of the disease, it is preferred that treatment or consultation occur at centers with expertise in the management of CTCL.
- Evaluation by a pathologist at a referral center is recommended.
- Folliculotropic MF (FMF) and LCT are histologic features that can occur irrespective of stage.
- Recent studies have reported that FMF presents with two distinct patterns of clinicopathologic features with different prognostic implications (early stage and advanced stage); in a subgroup of patients with early skin-limited disease, FMF has an indolent disease course and a favorable prognosis.<sup>e,f,g</sup> Treatment may require skin-directed therapy that reaches the subcutaneous tissue (eg, PUVA, ISRT) or the addition of systemic therapy as used in stages I–IIB for patients with disease not responding to skin-directed therapy alone.
- The incidence of LCT is strongly dependent on the disease stage at diagnosis.<sup>h,i</sup> LCT often but not always corresponds to a more aggressive growth rate requiring systemic therapies ([see MFSS-12](#)).
- Goals of therapy should be individualized but often include:
  - ▶ Attain adequate response in order to reduce and control symptoms and minimize risk of progression.
  - ▶ Most treatments for MF/SS do not result in durable remissions off of treatment.
  - ▶ Therapies with lower side-effect profiles and an absence of cumulative toxicity are often given in an ongoing or maintenance fashion to improve and maintain disease control and quality of life.
  - ▶ Other than allogeneic HCT, therapies are not given with curative intent.
- Generally, skin-directed therapies and biologic agents with lower rates of immunosuppression are used in earlier lines of therapy.
- When chemotherapy is required, in general, single agents are preferred over combination chemotherapy (eg, CHOP), due to short-lived responses associated with shorter durations of therapy and higher toxicity profiles associated with multiagent regimens.
- Responses can vary between the different compartments (ie, skin, blood, lymph nodes). Unlike other non-Hodgkin lymphoma subtypes, response criteria for MF/SS has not been demonstrated to correlate with prognosis. Often decisions to continue or switch therapy are on a clinical basis.
- Disease relapse after discontinuation of therapy may respond to re-treatment with previous therapy.
- Partial responses with suboptimal quality of life should be treated with other or additional primary treatment options.
- Use of supportive care measures to minimize risk of skin infections and treat pruritus is an important part of disease and symptom control ([see MFSS-B](#)).

<sup>e</sup> Hodak E, Amitay-Laish I, Atzmony L, et al. New insights into folliculotropic mycosis fungoides (FMF): A single-center experience. *J Am Acad Dermatol* 2016;75:347-355.

<sup>f</sup> van Santen S, Roach RE, van Doorn R, et al. Clinical staging and prognostic factors in folliculotropic mycosis fungoides. *JAMA Dermatol* 2016;152:992-1000.

<sup>g</sup> van Santen S, van Doorn R, Neelis KJ, et al. Recommendations for treatment in folliculotropic mycosis fungoides: report of the Dutch Cutaneous Lymphoma Group. *Br J Dermatol* 2017;177:223-228.

<sup>h</sup> Vergier B, de Muret A, Beylot-Barry M, et al. Transformation of mycosis fungoides: clinicopathological and prognostic features of 45 cases. *French Study Group of Cutaneous Lymphomas. Blood* 2000;95:2212-2218.

<sup>i</sup> Arulogun SO, Prince HM, Ng J, et al. Long-term outcomes of patients with advanced-stage cutaneous T-cell lymphoma and large cell transformation. *Blood* 2008;112:3082-3087.

**Note:** All recommendations are category 2A unless otherwise indicated.

**Clinical Trials:** NCCN believes that the best management of any patient with cancer is in a clinical trial. Participation in clinical trials is especially encouraged.





# NCCN Guidelines Version 2.2021

## Mycosis Fungoides/Sezary Syndrome

### DIAGNOSIS<sup>a</sup>

#### ESSENTIAL:

- Biopsy of suspicious skin sites
  - Multiple biopsies may be necessary to capture the pathologic variability of disease at diagnosis
- Review of all slides with at least one paraffin block representative of the tumor should be done by a pathologist with expertise in the diagnosis of CTCLs. Rebiopsy if consult material in conjunction with the clinical picture is nondiagnostic.<sup>b</sup>
- IHC panel of skin biopsy<sup>c,d,e</sup>
  - CD2, CD3, CD4, CD5, CD7, CD8, CD20, CD30
- Molecular analysis to detect clonal T-cell antigen receptor (*TCR*) gene rearrangements or other assessment of clonality<sup>a,f</sup>

#### USEFUL UNDER CERTAIN CIRCUMSTANCES:

- Assessment of peripheral blood for Sézary cells (in extensive skin disease where skin biopsy is not diagnostic in extensive patch or erythrodermic skin disease and/or strongly suggestive but not diagnostic of advanced-stage disease) including:
  - Sézary cell prep is less useful than flow cytometry due to the subjective nature of the process but can be useful where flow cytometry is not available.
  - Flow cytometry and molecular analysis to assess and quantitate an expanded T-cell population with aberrant phenotype.<sup>a,g</sup> [See MFSS-3](#) for specifics.
- IHC panel of skin biopsy<sup>b,c</sup>
  - CD25, CD56, TIA1, granzyme B, TCRβ, TCRδ; CXCL13, ICOS, and PD-1
- Biopsy of enlarged lymph nodes or suspected extracutaneous sites (if biopsy of skin is not diagnostic). Excisional or incisional biopsy is preferred over core needle biopsy. An FNA alone is not sufficient for the initial diagnosis of lymphoma. A core needle biopsy is not optimal but can be used under certain circumstances. In certain circumstances, when a lymph node is not easily accessible for excisional or incisional biopsy, a combination of core needle biopsy and FNA in conjunction with appropriate ancillary techniques may be sufficient for diagnosis. Rebiopsy if consult material is nondiagnostic.
- Assessment of HTLV-1/2<sup>h</sup> by serology or other methods is encouraged as results can impact therapy.

→ [See Workup \(MFSS-2\)](#)

<sup>a</sup> [See Principles of Molecular Analysis in Cutaneous Lymphomas \(PCLYM-B\)](#).

<sup>b</sup> Presence of transformation or areas of folliculotropism may have important implications for selection of therapy and outcome and should be included in pathology reports.

<sup>c</sup> Clinically suspicious and histologically non-diagnostic cases. Pimpinelli N, et al. J Am Acad Dermatol 2005;53:1053-1063.

<sup>d</sup> [See Use of Immunophenotyping/Genetic Testing in Differential Diagnosis of Mature B-Cell and NK/T-Cell Neoplasms \(See NCCN Guidelines for B-Cell Lymphomas\)](#).

<sup>e</sup> Typical immunophenotype: CD2+, CD3+, CD5+, CD7-, CD4+, CD8- (rarely CD8+), CD30-/+ cytotoxic granule proteins negative.

<sup>f</sup> Clonal *TCR* gene rearrangements alone are not sufficient for diagnosis, as these can also be seen in patients with non-malignant conditions. Results should be interpreted in the context of overall presentation. [See Principles of Molecular Analysis in Cutaneous Lymphomas \(PCLYM-B\)](#).

<sup>g</sup> CD3, CD4, CD7, CD8, CD26 to assess for expanded CD4+ cells with increased CD4/CD8 ratio or with abnormal immunophenotype, including loss of CD7 or CD26.

<sup>h</sup> See [map](#) for prevalence of HTLV-1/2 by geographic region. HTLV-1 has been described in patients in non-endemic areas.

**Note:** All recommendations are category 2A unless otherwise indicated.

**Clinical Trials:** NCCN believes that the best management of any patient with cancer is in a clinical trial. Participation in clinical trials is especially encouraged.



# NCCN Guidelines Version 2.2021

## Mycosis Fungoides/Sezary Syndrome

### WORKUP

#### ESSENTIAL:

- History and complete physical examination:
  - Complete skin examination: assessment of % body surface area (BSA) (palm plus digits ≈1% BSA) and type of skin lesion (ie, patch/plaque, tumor, erythroderma)
  - Palpation of peripheral lymph node regions
  - Palpation for organomegaly/masses
- Laboratory studies:<sup>i</sup>
  - CBC with differential and determination of absolute lymphocyte count
  - Sézary flow cytometric studies to assess and quantitate an expanded T-cell population with aberrant phenotype (optional for T1<sup>j</sup>) ([see MFSS-3](#))
    - ◊ Recommended for any patient with T2–4 skin classification, any suspected extracutaneous disease including adenopathy
  - Clonal TCR gene rearrangement in peripheral blood lymphocytes if blood involvement suspected<sup>a</sup>
  - Comprehensive metabolic panel
  - LDH
- Imaging studies:
  - C/A/P CT with contrast or integrated whole body PET/CT<sup>k</sup> for T3 or T4 (arms/legs included when disease assessment of entire body is needed)

For TNMB Classification, see [MFSS-3](#) and For Clinical Staging of MF and SS, see [MFSS-4](#)

#### USEFUL IN SELECTED CASES:

- Bone marrow biopsy in patients with unexplained hematologic abnormality
- Biopsy of enlarged lymph nodes or suspected extracutaneous sites (if biopsy of skin is not diagnostic). Excisional or incisional biopsy is preferred over core needle biopsy. An FNA alone is not sufficient for the initial diagnosis of lymphoma. A core needle biopsy is not optimal but can be used under certain circumstances. In certain circumstances, when a lymph node is not easily accessible for excisional or incisional biopsy, a combination of core needle biopsy and FNA in conjunction with appropriate ancillary techniques may be sufficient for diagnosis. Rebiopsy if consult material is nondiagnostic.
- Rebiopsy skin if suspicious of LCT or folliculotropism and not previously confirmed pathologically
- C/A/P CT with contrast or integrated whole body PET/CT<sup>k</sup> for ≥T2b or large-cell transformed or folliculotropic MF, or with palpable adenopathy or abnormal laboratory studies; consider for T2a (patch disease with ≥10% BSA)
- Neck CT with contrast if have not done whole body PET/CT
- Pregnancy testing in women of childbearing age if contemplating treatments that are contraindicated in pregnancy<sup>l</sup>
- Discussion of fertility and sperm banking, if fertility-impacting therapy is planned

<sup>a</sup> See [Principles of Molecular Analysis in Cutaneous Lymphomas \(PCLYM-B\)](#).

<sup>i</sup> Sézary syndrome (B2) is as defined on [MFSS-3](#).

<sup>j</sup> See [Discussion](#) for when Sézary flow cytometric study is appropriate in T1 disease.

<sup>k</sup> Patients with cutaneous lymphomas have extranodal disease, which may be inadequately imaged by CT. PET scan may be preferred in these instances.

<sup>l</sup> Many skin-directed and systemic therapies are contraindicated or of unknown safety in pregnancy. Refer to individual drug information.

**Note:** All recommendations are category 2A unless otherwise indicated.

**Clinical Trials:** NCCN believes that the best management of any patient with cancer is in a clinical trial. Participation in clinical trials is especially encouraged.



# NCCN Guidelines Version 2.2021

## Mycosis Fungoides/Sézary Syndrome

TNMB		TNMB Classification and Staging of Mycosis Fungoides and Sézary Syndrome <sup>m,n</sup> See Clinical Staging of MF and SS on <a href="#">MFSS-4</a>	
Skin	T1	Limited patches, <sup>o</sup> papules, and/or plaques <sup>p</sup> covering <10% of the skin surface	
	T2	Patches, papules, <sup>o</sup> and/or plaques <sup>o</sup> covering ≥10% of the skin surface	
	T2a	Patch only	
	T2b	Plaque ± patch	
	T3	One or more tumors <sup>q</sup> (≥1 cm in diameter)	
	T4	Confluence of erythema ≥80% body surface area	
Node	N0	No abnormal lymph nodes; biopsy not required	<a href="#">See NCI Lymph Node Classification on MFSS-5</a>
	N1	Abnormal lymph nodes; histopathology Dutch Gr 1 or NCI LN 0-2	<a href="#">See Dutch Criteria for Lymph Nodes on MFSS-5</a>
	N2	Abnormal lymph nodes; histopathology Dutch Gr 2 or NCI LN 3	
	N3	Abnormal lymph nodes; histopathology Dutch Gr 3-4 or NCI LN 4	
	NX	Abnormal lymph nodes; no histologic confirmation	
Visceral	M0	No visceral organ involvement	
	M1	Visceral involvement (must have pathology confirmation and organ involved should be specified)	
	MX	Abnormal visceral site; no histologic confirmation	
Blood	B0	Absence of significant blood involvement: ≤5% of peripheral blood lymphocytes or <250/mcL are atypical (Sézary) cells or <15% CD4+/CD26- or CD4+/CD7- cells of total lymphocytes	
	B1	Low blood tumor burden: >5% of peripheral blood lymphocytes are atypical (Sézary) cells or >15% CD4+CD26- or CD4+CD7- of total lymphocytes but do not meet the criteria of B0 or B2	
	B2	High blood tumor burden: ≥1000/mcL Sézary cells <sup>n</sup> determined by cytopathology or ≥1000 CD4+CD26- or CD4+CD7- cells/uL or other abnormal subset of T lymphocytes by flow cytometry with clone in blood same as that in skin. Other criteria for documenting high blood tumor burden in CD4+ MF/SS include CD4+/CD7- cells ≥40% and CD4+CD26- cells ≥30%.	

<sup>m</sup> Adapted from Olsen E, et al. Blood 2007;110:1713-1722 and Olsen E, et al. J Clin Oncol 2011;29:2598-2607.

<sup>n</sup> Sézary syndrome is defined by B2 blood involvement and a clonal rearrangement of *TCR* in the blood (clones should be relevant to clone in the skin).

<sup>o</sup> Patch = Any size skin lesion without significant elevation or induration. Presence/absence of hypo- or hyperpigmentation, scale, crusting, and/or poikiloderma should be noted.

<sup>p</sup> Plaque = Any size skin lesion that is elevated or indurated. Presence or absence of scale, crusting, and/or poikiloderma should be noted. Histologic features such as folliculotropism or LCT (≥25% large cells), CD30+ or CD30-, and clinical features such as ulceration are important to document.

<sup>q</sup> Tumor = at least one ≥1 cm diameter solid or nodular lesion with evidence of depth and/or vertical growth. Note total number of lesions, total volume of lesions, largest size lesion, and region of body involved. Also note if histologic evidence of LCT has occurred. Phenotyping for CD30 is encouraged.

**Note: All recommendations are category 2A unless otherwise indicated.**

**Clinical Trials: NCCN believes that the best management of any patient with cancer is in a clinical trial. Participation in clinical trials is especially encouraged.**



# NCCN Guidelines Version 2.2021

## Mycosis Fungoides/Sézary Syndrome

### Clinical Staging of MF and SS<sup>1</sup>

Clinical Stage <sup>r</sup>	T (Skin)	N (Node)	M (Visceral)	B (Blood Involvement)	Guidelines Page
IA (Limited skin involvement)	T1 (Patches, papules, and/or plaques covering <10% body surface area [BSA])	N0	M0	B0 or B1	<a href="#">MFSS-6</a>
IB (Skin only disease)	T2 (Patches, papules, and/or plaques covering ≥10% BSA)	N0	M0	B0 or B1	<a href="#">MFSS-7</a>
IIA	T1–2	N1–2	M0	B0 or B1	<a href="#">MFSS-7</a>
IIB (Tumor stage disease)	T3 (One or more tumors [≥1 cm in diameter])	N0–2	M0	B0 or B1	<a href="#">MFSS-8</a>
IIIA (Erythrodermic disease)	T4 (Confluence of erythema ≥80% BSA)	N0–2	M0	B0	<a href="#">MFSS-10</a>
IIIB (Erythrodermic disease)	T4 (Confluence of erythema ≥80% BSA)	N0–2	M0	B1	<a href="#">MFSS-10</a>
IVA <sub>1</sub> (Sézary syndrome)	T1–4	N0–2	M0	B2	<a href="#">MFSS-11</a>
IVA <sub>2</sub> (Sézary syndrome or Non-Sézary)	T1–4	N3	M0	B0 or B1 or B2	<a href="#">MFSS-11</a>
IVB (Visceral disease)	T1–4	N0–3	M1	B0 or B1 or B2	<a href="#">MFSS-11</a>
	Large-cell transformation (LCT) <sup>s</sup>				<a href="#">MFSS-12</a>

<sup>1</sup> Olsen E, et al. Blood 2007;110:1713-1722.

<sup>r</sup> Folliculotropism is a histologic feature that can occur irrespective of stage. Histologic evidence of folliculotropic MF is associated with higher risk of disease progression. In selected cases or inadequate response, consider primary treatment for stage IIB (tumor stage disease).

<sup>s</sup> LCT is a histologic feature that can occur irrespective of clinical stage. LCT often but not always corresponds to a more aggressive growth rate requiring systemic therapies.

**Note: All recommendations are category 2A unless otherwise indicated.**

**Clinical Trials: NCCN believes that the best management of any patient with cancer is in a clinical trial. Participation in clinical trials is especially encouraged.**

**For TNMB Classification, see MFSS-3**



### LYMPH NODE CLASSIFICATION IN MF AND SS

#### NCI-VA Lymph Node Classification

**LN0: no atypical lymphocytes**

**LN1: occasional and isolated atypical lymphocytes (not arranged in clusters)**

**LN2: many atypical lymphocytes or in 3–6 cell clusters**

**LN3: aggregates of atypical lymphocytes; nodal architecture preserved**

**LN4: partial/complete effacement of nodal architecture by atypical lymphocytes or frankly neoplastic cells**

Clendenning WE, Rappaport HW. Report of the Committee on Pathology of Cutaneous T Cell Lymphomas. Cancer Treat Rep 1979;63:719-724.

#### Dutch Criteria for Lymph Nodes

**Grade 1: Dermatopathic lymphadenopathy**

**Grade 2: Early involvement by mycosis fungoides (presence of cerebriform nuclei >7.5 micrometers)**

**Grade 3: Partial effacement of lymph node architecture; many atypical cerebriform mononuclear cells**

**Grade 4: Complete effacement of lymph node architecture**

Scheffer E, Meijer CJLM, van Vloten WA. Dermatopathic lymphadenopathy and lymph node involvement in mycosis fungoides. Cancer 1980;45:137-148.

**Note:** All recommendations are category 2A unless otherwise indicated.

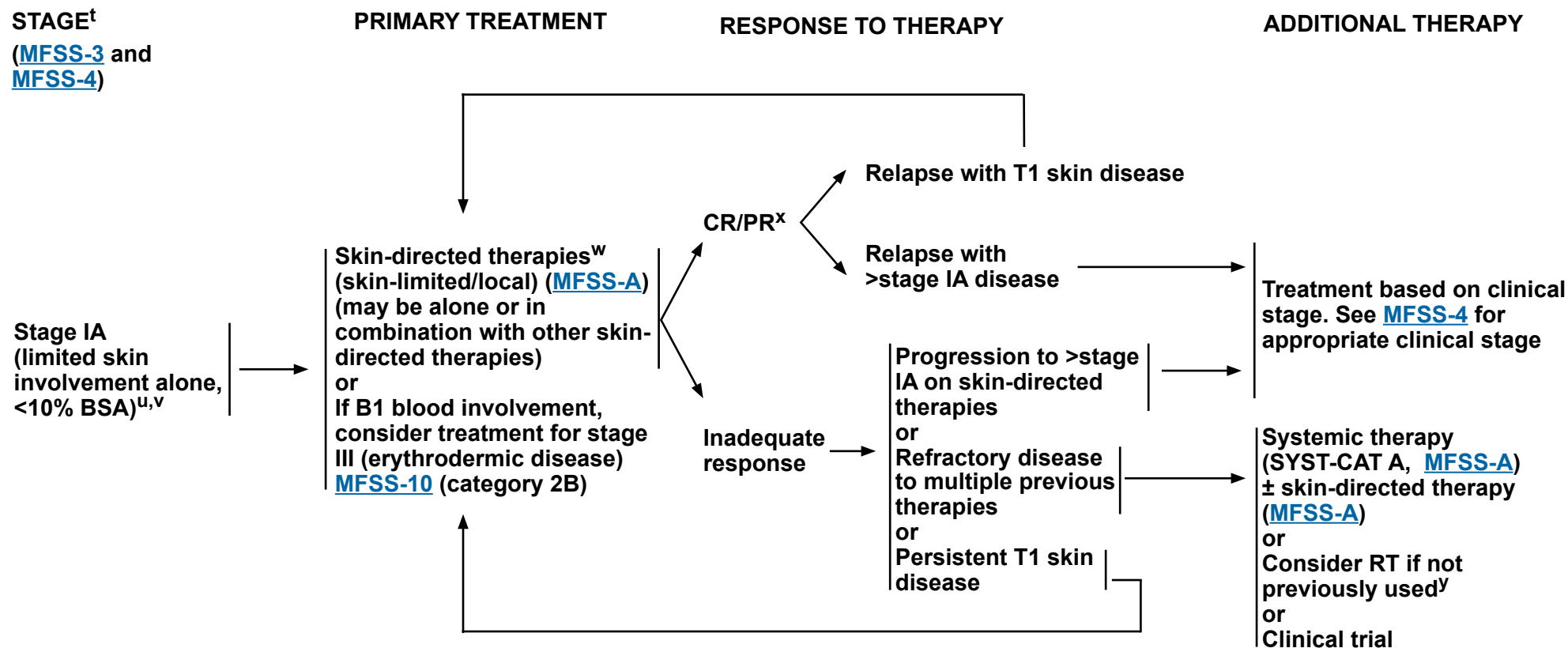
**Clinical Trials:** NCCN believes that the best management of any patient with cancer is in a clinical trial. Participation in clinical trials is especially encouraged.





# NCCN Guidelines Version 2.2021

## Mycosis Fungoides/Sézary Syndrome



See Supportive Care for Patients MF/SS  
([MFSS-B](#))

<sup>t</sup> See [Principles for Mycosis Fungoides/Sézary Syndrome \(MFSS/INTRO-1\)](#).

<sup>u</sup> In rare cases of confirmed unilesional MF, RT has been shown to provide long-term remission.

<sup>v</sup> Rebiopsy if suspect LCT; if histologic evidence of LCT, see [MFSS-12](#).

<sup>w</sup> In patients with histologic evidence of folliculotropic MF, skin disease may be less responsive to topical therapies.

<sup>x</sup> Patients with disease achieving a clinical benefit and/or those with disease responding to primary treatment should be considered for maintenance or tapering of regimens to optimize response duration.

<sup>y</sup> See [Principles of Radiation Therapy \(PCLYM-A\)](#).

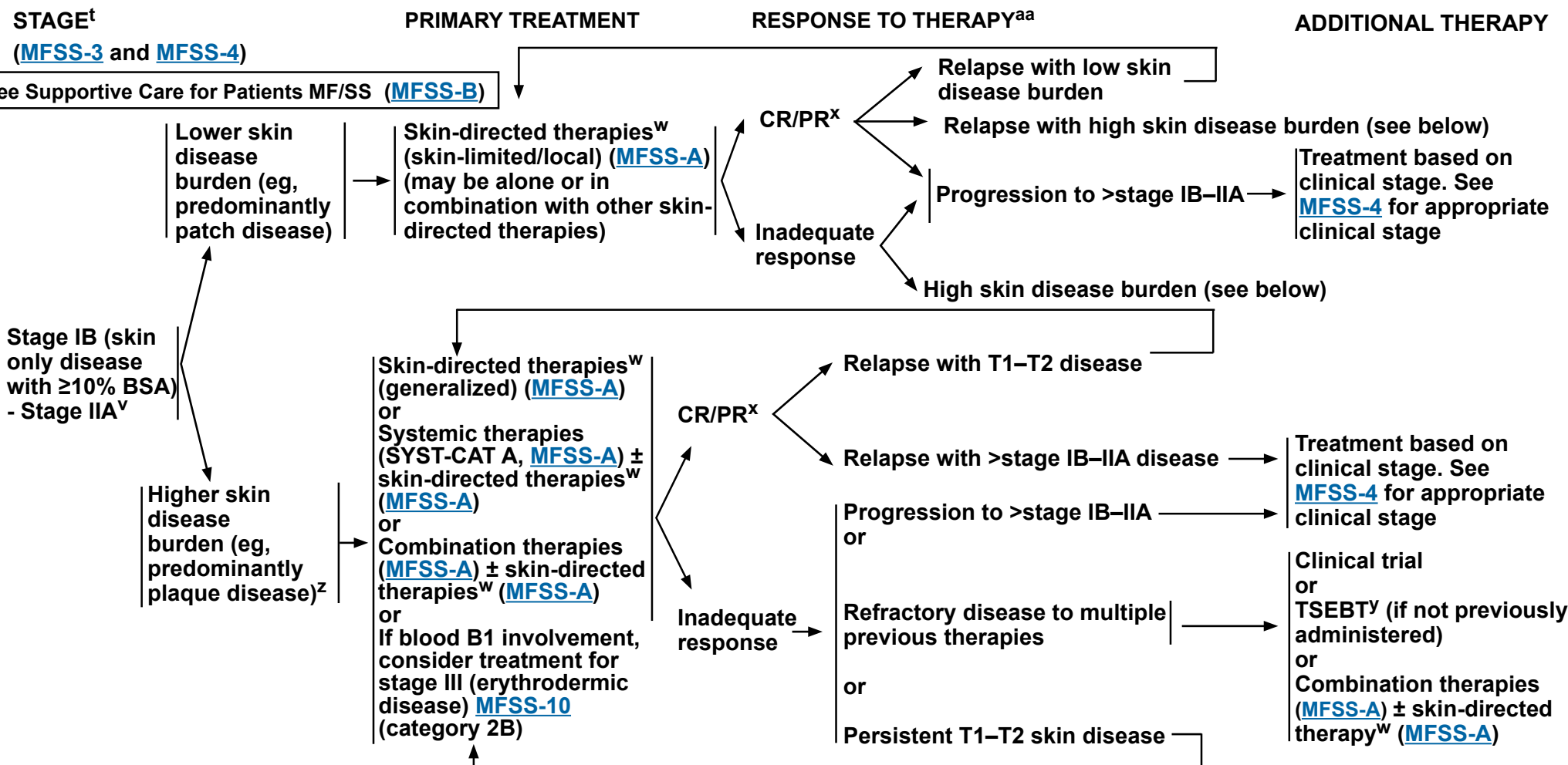
**Note:** All recommendations are category 2A unless otherwise indicated.

**Clinical Trials:** NCCN believes that the best management of any patient with cancer is in a clinical trial. Participation in clinical trials is especially encouraged.



# NCCN Guidelines Version 2.2021

## Mycosis Fungoides/Sézary Syndrome



<sup>t</sup> See Principles for Mycosis Fungoides/Sézary Syndrome ([MFSS/INTRO-1](#)).

<sup>v</sup> Rebiopsy if LCT is suspected; if histologic evidence of LCT, see [MFSS-12](#).

<sup>w</sup> In patients with histologic evidence of folliculotropic MF, skin disease may be less responsive to topical therapies.

<sup>x</sup> Patients with disease achieving a clinical benefit and/or those with disease responding to primary treatment should be considered for maintenance or tapering of regimens to optimize response duration.

<sup>y</sup> See Principles of Radiation Therapy ([PCLYM-A](#)).

<sup>z</sup> Patients with indolent/plaque folliculotropic MF (without evidence of LCT) should first be considered for therapies under SYST-CAT A before proceeding to treatments listed in SYST-CAT B. See [MFSS-A \(2 of 6\)](#).

<sup>aa</sup> Imaging indicated when suspicious of clinical extracutaneous disease with modalities used in workup.

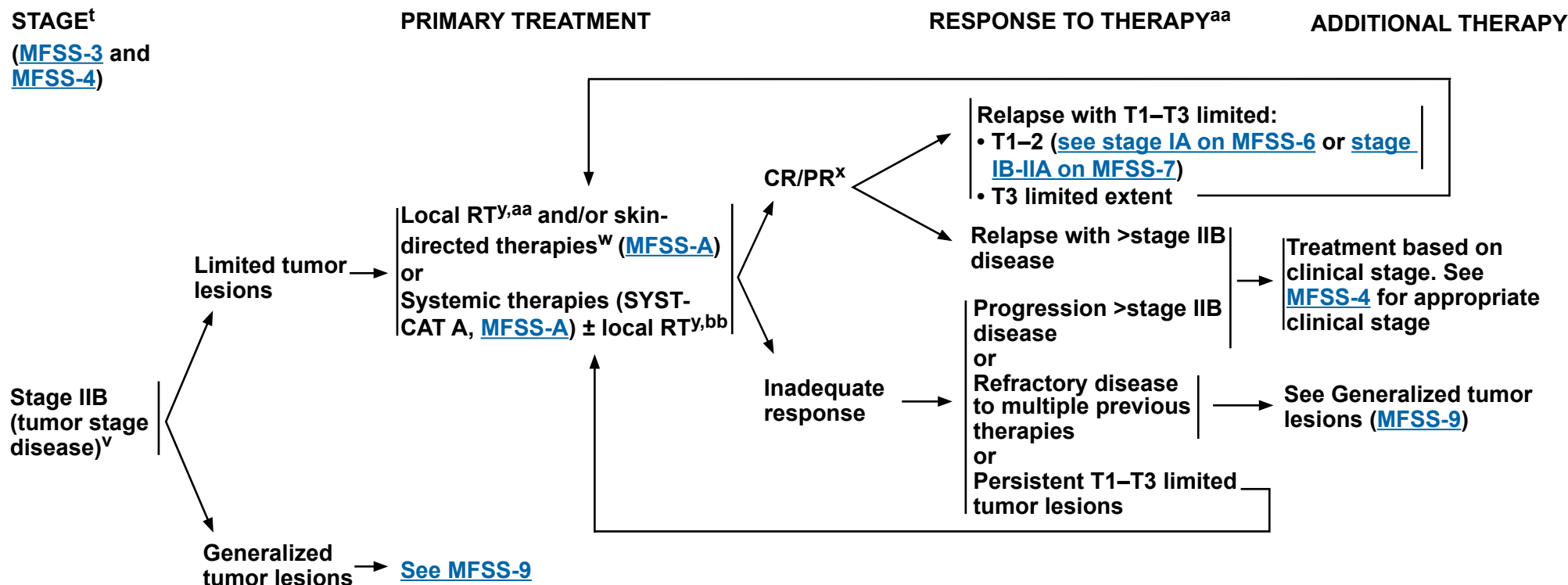
**Note:** All recommendations are category 2A unless otherwise indicated.

**Clinical Trials:** NCCN believes that the best management of any patient with cancer is in a clinical trial. Participation in clinical trials is especially encouraged.



# NCCN Guidelines Version 2.2021

## Mycosis Fungoides/Sezary Syndrome



**See Supportive Care for Patients MF/SS ([MFSS-B](#))**

<sup>t</sup> See [Principles for Mycosis Fungoides/Sézary Syndrome \(MFSS/INTRO-1\)](#).

<sup>v</sup> Rebiopsy if LCT is suspected; if histologic evidence of LCT, [see MFSS-12](#).

<sup>w</sup> In patients with histologic evidence of folliculotropic MF, skin disease may be less responsive to topical therapies.

<sup>x</sup> Patients with disease achieving a clinical benefit and/or those with disease responding to primary treatment should be considered for maintenance or tapering of regimens to optimize response duration.

<sup>y</sup> See [Principles of Radiation Therapy \(PCLYM-A\)](#).

<sup>aa</sup> Imaging indicated when suspicious of clinical extracutaneous disease with modalities used in workup.

<sup>bb</sup> RT is preferred for tumor lesions.

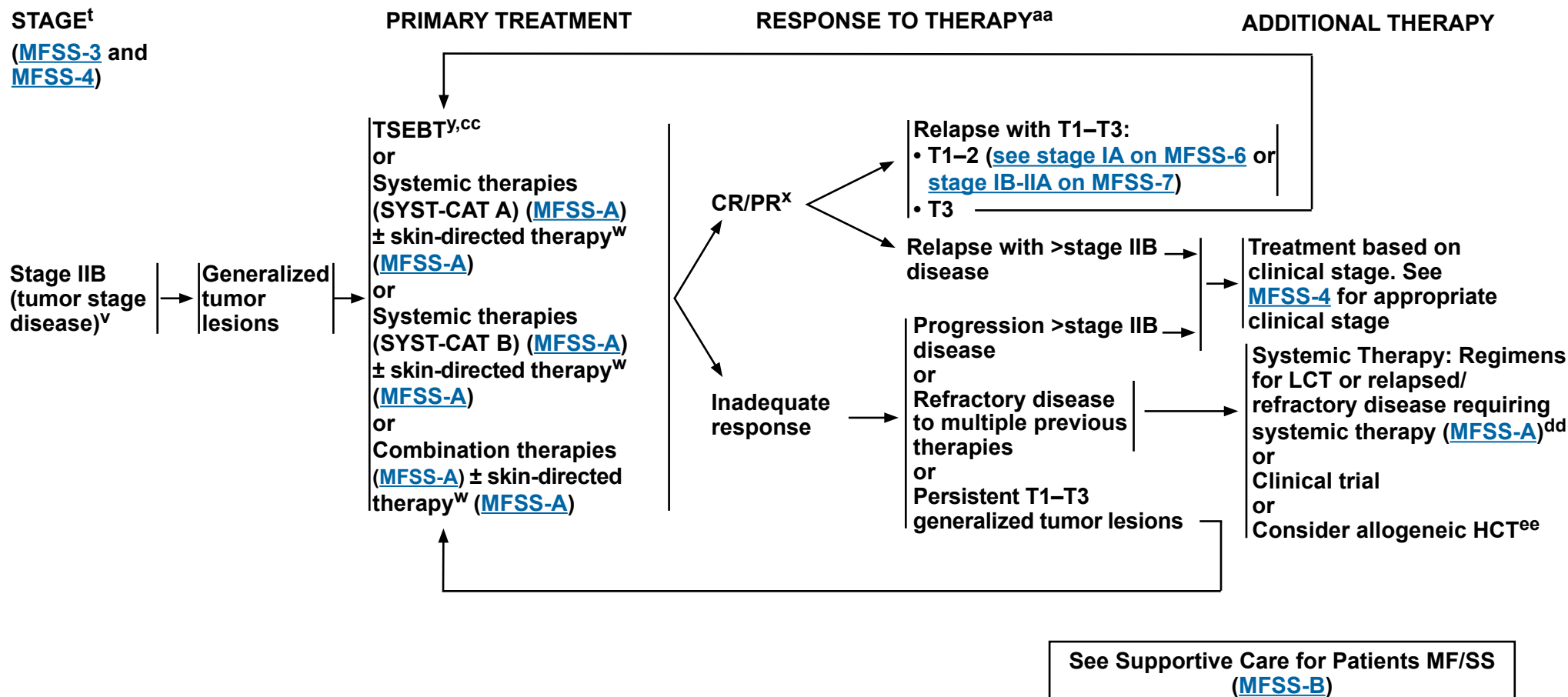
**Note:** All recommendations are category 2A unless otherwise indicated.

**Clinical Trials:** NCCN believes that the best management of any patient with cancer is in a clinical trial. Participation in clinical trials is especially encouraged.



# NCCN Guidelines Version 2.2021

## Mycosis Fungoides/Sézary Syndrome



<sup>t</sup> See [Principles for Mycosis Fungoides/Sézary Syndrome \(MFSS/INTRO-1\)](#).

<sup>v</sup> Rebiopsy if LCT is suspected, if histologic evidence of LCT, [see MFSS-12](#).

<sup>w</sup> In patients with histologic evidence of folliculotropic MF, skin disease may be less responsive to topical therapies.

<sup>x</sup> Patients with disease achieving a clinical benefit and/or those with disease responding to primary treatment should be considered for maintenance or tapering of regimens to optimize response duration.

<sup>y</sup> See [Principles of Radiation Therapy \(PCLYM-A\)](#).

<sup>aa</sup> Imaging indicated when suspicious of clinical extracutaneous disease with modalities used in workup.

<sup>cc</sup> May consider adjuvant systemic biologic therapy (SYST-CAT A) after TSEBT to improve response duration. [See MFSS-A \(2 of 6\)](#).

<sup>dd</sup> Most patients will receive multiple SYST-CAT A/B before switching to multiagent chemotherapy. [See MFSS-A \(2 of 6\)](#).

<sup>ee</sup> Allogeneic HCT is associated with better outcomes in patients with disease responding to primary treatment prior to transplant. See [Discussion](#) for further details.

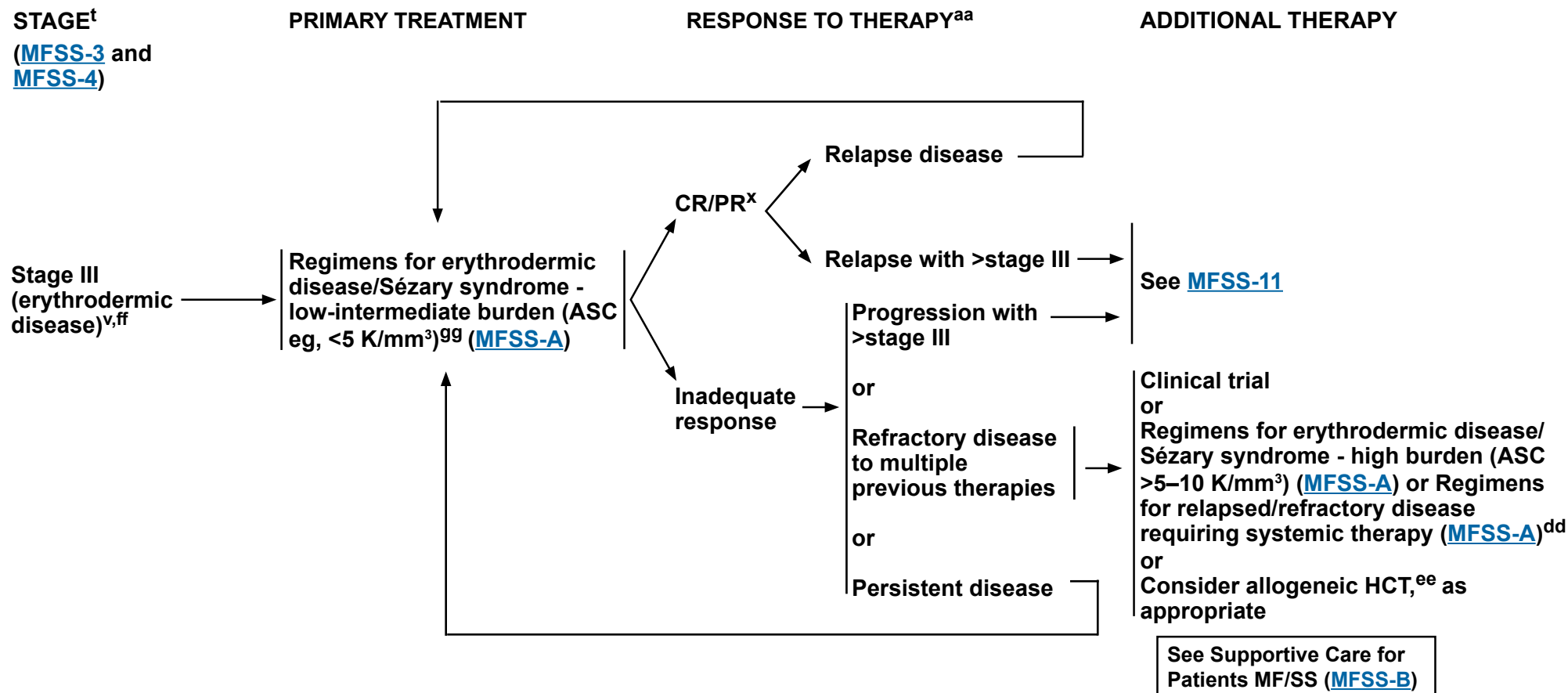
**Note:** All recommendations are category 2A unless otherwise indicated.

**Clinical Trials:** NCCN believes that the best management of any patient with cancer is in a clinical trial. Participation in clinical trials is especially encouraged.



# NCCN Guidelines Version 2.2021

## Mycosis Fungoides/Sézary Syndrome



<sup>t</sup> See [Principles for Mycosis Fungoides/Sézary Syndrome \(MFSS/INTRO-1\)](#).

<sup>v</sup> Rebiopsy if LCT is suspected; if histologic evidence of LCT, see [MFSS-12](#).

<sup>x</sup> Patients with disease achieving a clinical benefit and/or those with disease responding to primary treatment should be considered for maintenance or tapering of regimens to optimize response duration.

<sup>aa</sup> Imaging indicated when suspicious of clinical extracutaneous disease with modalities used in workup.

<sup>dd</sup> Most patients will receive multiple SYST-CAT A/B before switching to multiagent chemotherapy. See [MFSS-A \(2 of 6\)](#).

<sup>ee</sup> Allogeneic HCT is associated with better outcomes in patients with disease responding to primary treatment prior to transplant. See [Discussion](#) for further details.

<sup>ff</sup> Patients with erythrodermic disease are at increased risk for secondary infection with skin pathogens and systemic antibiotic therapy should be considered.

<sup>gg</sup> Olsen E, et al. J Clin Oncol 2011;29:2598-2607.

**Note:** All recommendations are category 2A unless otherwise indicated.

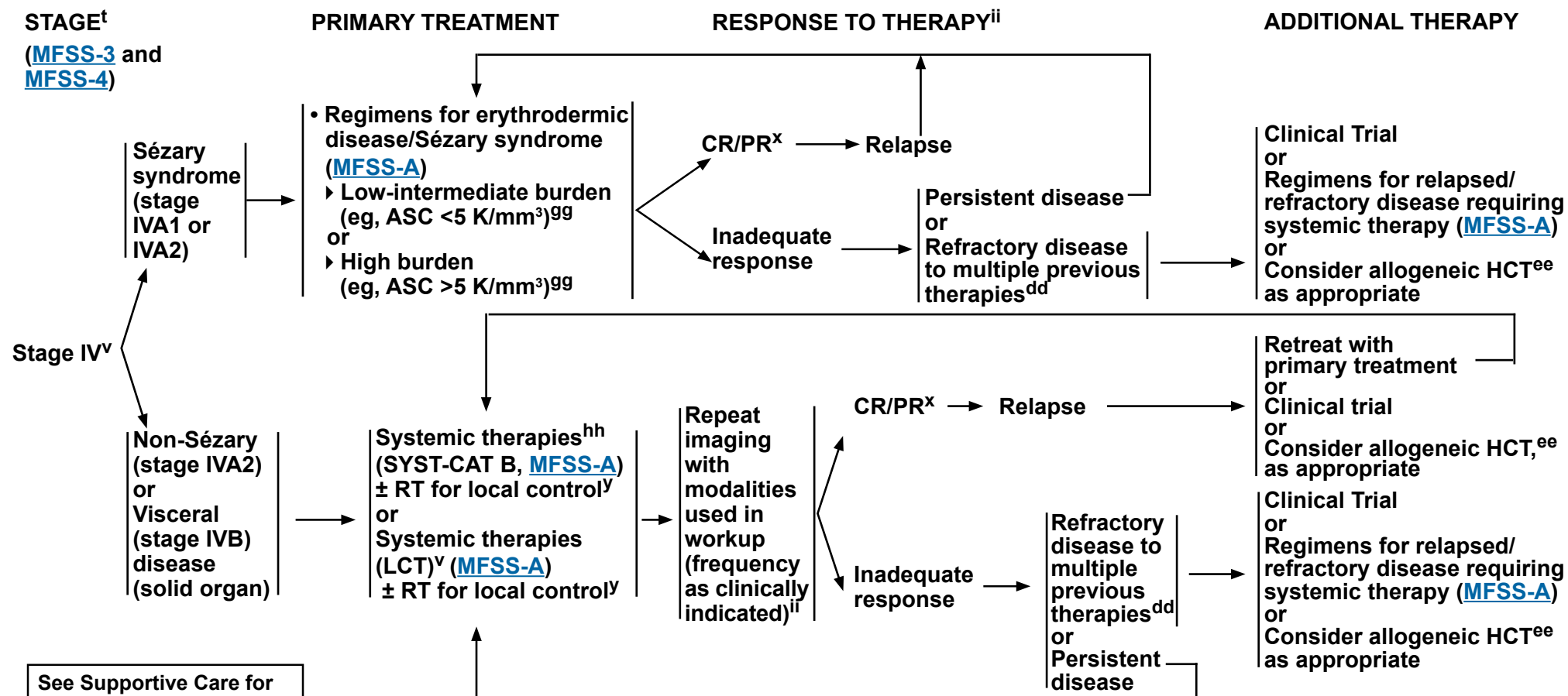
**Clinical Trials:** NCCN believes that the best management of any patient with cancer is in a clinical trial. Participation in clinical trials is especially encouraged.





# NCCN Guidelines Version 2.2021

## Mycosis Fungoides/Sézary Syndrome



<sup>t</sup> See [Principles for Mycosis Fungoides/Sézary Syndrome \(MFSS/INTRO-1\)](#).

<sup>v</sup> Rebiopsy if LCT is suspected; if histologic evidence of LCT, see [MFSS-12](#).

<sup>x</sup> Patients with disease achieving a clinical benefit and/or those with disease responding to primary treatment should be considered for maintenance or tapering of regimens to optimize response duration.

<sup>y</sup> See [Principles of Radiation Therapy \(PCLYM-A\)](#).

<sup>dd</sup> Most patients will receive multiple SYST-CAT A/B before switching to multiagent chemotherapy. See [MFSS-A \(2 of 6\)](#).

<sup>ee</sup> Allogeneic HCT is associated with better outcomes in patients with disease responding to primary treatment prior to transplant. See [Discussion](#) for further details.

<sup>gg</sup> Olsen E, et al. J Clin Oncol 2011;29:2598-2607.

<sup>hh</sup> Patients with stage IV non-Sézary/visceral disease may present with more aggressive growth characteristics. If there is no evidence of more aggressive growth, systemic therapies from SYST-CAT B are appropriate. If aggressive growth is seen, then systemic therapies listed for LCT are preferred. See [MFSS-A \(2 of 6\)](#).

<sup>ii</sup> If disease in lymph nodes and/or viscera or suspicious of disease progression, imaging indicated with modalities used in workup as clinically indicated based on distribution of disease.

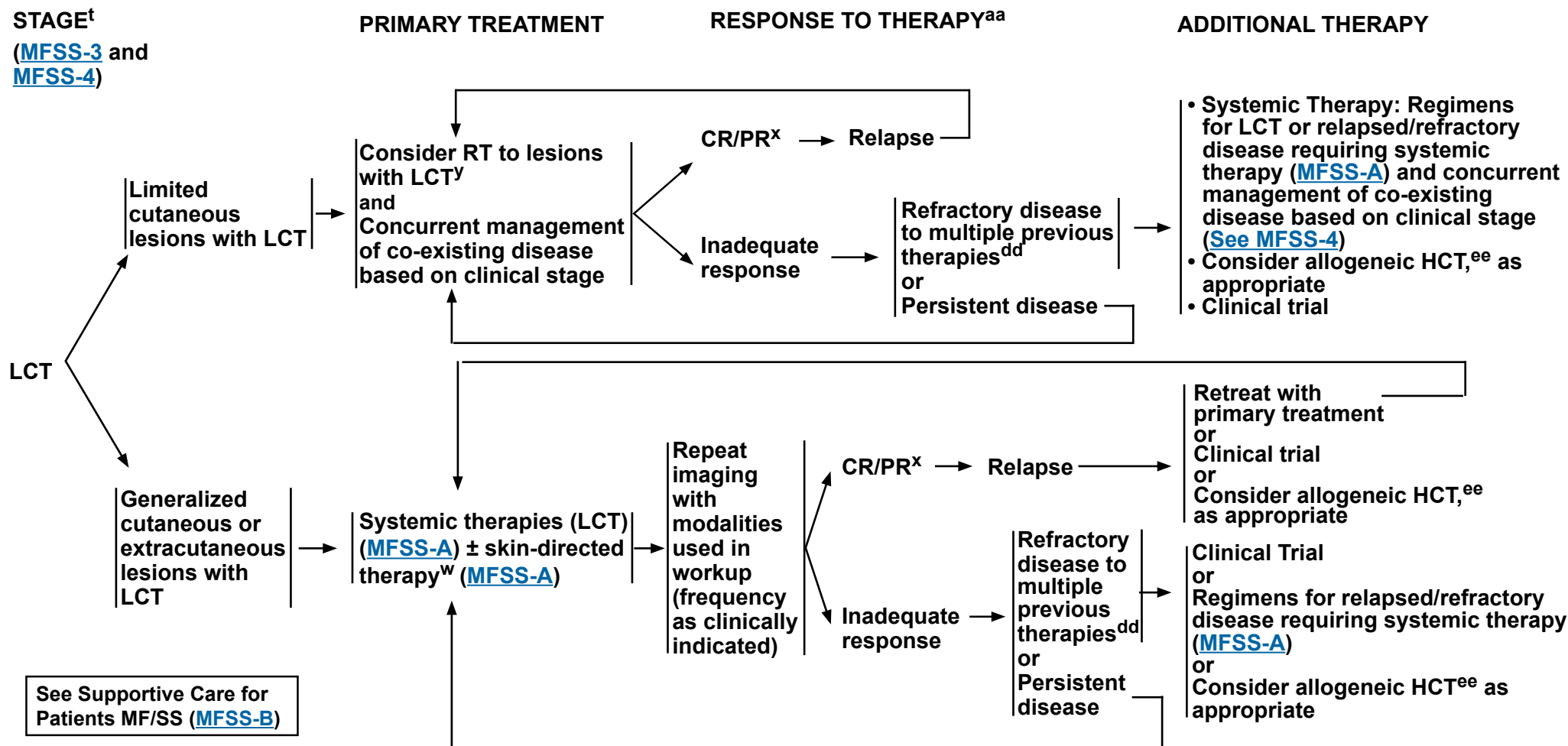
**Note:** All recommendations are category 2A unless otherwise indicated.

**Clinical Trials:** NCCN believes that the best management of any patient with cancer is in a clinical trial. Participation in clinical trials is especially encouraged.



# NCCN Guidelines Version 2.2021

## Mycosis Fungoides/Sezary Syndrome



<sup>t</sup> See Principles for Mycosis Fungoides/Sézary Syndrome ([MFSS/INTRO-1](#)).

<sup>w</sup> In patients with histologic evidence of folliculotropic MF, skin disease may be less responsive to topical therapies.

<sup>x</sup> Patients with disease achieving a clinical benefit and/or those with disease responding to primary treatment should be considered for maintenance or tapering of regimens to optimize response duration.

<sup>y</sup> See Principles of Radiation Therapy ([PCLYM-A](#)).

<sup>aa</sup> Imaging indicated when suspicious of clinical extracutaneous disease with modalities used in workup.

<sup>dd</sup> Most patients will receive multiple SYST-CAT A/B before switching to multiagent chemotherapy. [See MFSS-A \(2 of 6\)](#).

<sup>ee</sup> Allogeneic HCT is associated with better outcomes in patients with disease responding to primary treatment prior to transplant. See [Discussion](#) for further details.

**Note:** All recommendations are category 2A unless otherwise indicated.

**Clinical Trials:** NCCN believes that the best management of any patient with cancer is in a clinical trial. Participation in clinical trials is especially encouraged.



# NCCN Guidelines Version 2.2021

## Mycosis Fungoides/Sezary Syndrome

### SUGGESTED TREATMENT REGIMENS<sup>a,b</sup>

SKIN-DIRECTED THERAPIES	
<i>Skin-Limited/Local (For limited/localized skin involvement) (in alphabetical order)</i>	<i>Skin-Generalized (For generalized skin involvement) (in alphabetical order)</i>
<ul style="list-style-type: none"> <li>• Local radiation (ISRT) (8–12 Gy; 24–30 Gy for unilesional presentation)<sup>c</sup></li> <li>• Phototherapy (UVB, NB-UVB for patch/thin plaques; PUVA/UVA1 for thicker plaques or tumors)<sup>d,e</sup></li> <li>• Topical carmustine (category 2B)</li> <li>• Topical corticosteroids<sup>f</sup></li> <li>• Topical imiquimod</li> <li>• Topical mechlorethamine (nitrogen mustard)</li> <li>• Topical retinoids (bexarotene, tazarotene)</li> </ul>	<ul style="list-style-type: none"> <li>• Phototherapy (UVB, NB-UVB, for patch/thin plaques; PUVA/UVA-1)<sup>e</sup></li> <li>• Topical corticosteroids<sup>f</sup></li> <li>• Topical mechlorethamine (nitrogen mustard)</li> <li>• TSEBT (12–36 Gy)<sup>c,g,h</sup></li> </ul>

<sup>a</sup> See references for regimens [MFSS-A 4 of 6](#), [MFSS-A 5 of 6](#), and [MFSS-A 6 of 6](#).

<sup>b</sup> The optimal treatment for any patient at any given time is often individualized based on symptoms of disease, route of administration, toxicities, and overall goals of therapy.

<sup>c</sup> See [Principles of Radiation Therapy \(PCLYM-A\)](#).

<sup>d</sup> PUVA/UVA and TSEBT should be considered for widespread thicker plaques or tumors. For thinner plaques or patch disease, UVB/NB-UVB are preferred.

<sup>e</sup> Cumulative dose of UV is associated with increased risk of UV-associated skin neoplasms; thus, phototherapy may not be appropriate in patients with a history of extensive squamoproliferative skin neoplasms or basal cell carcinomas or who have had melanoma.

<sup>f</sup> Long-term use of topical steroid may be associated with skin atrophy and/or striae formation. This risk worsens with increased potency of the steroid. High-potency steroid used on large skin surfaces may lead to systemic absorption.

<sup>g</sup> It is common practice to follow TSEBT with systemic therapies such as interferon or bexarotene to maintain response.

<sup>h</sup> Safety of combining TSEBT with systemic retinoids, HDAC inhibitors (such as vorinostat or romidepsin), or mogamulizumab, or combining phototherapy with vorinostat or romidepsin is unknown.

**Note:** All recommendations are category 2A unless otherwise indicated.

**Clinical Trials:** NCCN believes that the best management of any patient with cancer is in a clinical trial. Participation in clinical trials is especially encouraged.



# NCCN Guidelines Version 2.2021

## Mycosis Fungoides/Sézary Syndrome

### SUGGESTED TREATMENT REGIMENS<sup>a,b</sup>

SYSTEMIC THERAPIES			
SYST-CAT A	SYST-CAT B	Large-Cell Transformation (LCT)	Relapsed/Refractory Disease Requiring Systemic Therapy
<b>Preferred Regimens (alphabetical order)</b> <ul style="list-style-type: none"> <li>• Bexarotene<sup>h</sup></li> <li>• Brentuximab vedotin<sup>i,j,k</sup></li> <li>• Extracorporeal photopheresis (ECP)<sup>l</sup></li> <li>• Interferons (IFN alfa-2b<sup>m</sup> or IFN gamma-1b)</li> <li>• Methotrexate (≤50 mg q week)</li> <li>• Mogamulizumab<sup>n</sup></li> <li>• Romidepsin<sup>h</sup></li> <li>• Vorinostat<sup>h</sup></li> </ul> <b>Other Recommended Regimens</b> <ul style="list-style-type: none"> <li>• Acitretin<sup>h</sup></li> <li>• All-trans retinoic acid<sup>h</sup></li> <li>• Isotretinoin (13-cis-retinoic acid)<sup>h</sup></li> </ul>	<b>Preferred Regimens</b> <ul style="list-style-type: none"> <li>• Brentuximab vedotin<sup>i,j,k</sup></li> <li>• Gemcitabine</li> <li>• Liposomal doxorubicin</li> <li>• Pralatrexate (low-dose or standard dose)</li> </ul>	<b>Preferred Regimens</b> <ul style="list-style-type: none"> <li>• Brentuximab vedotin<sup>i,j,k</sup></li> <li>• Gemcitabine</li> <li>• Liposomal doxorubicin</li> <li>• Pralatrexate (low-dose or standard dose)</li> <li>• Romidepsin</li> <li>• See <a href="#">TCEL-B 2 of 5</a> for regimens listed for PTCL-NOS<sup>o</sup></li> </ul>	<b>Useful Under Certain Circumstances (alphabetical order by category)</b> <ul style="list-style-type: none"> <li>• Alemtuzumab<sup>p</sup></li> <li>• Chlorambucil</li> <li>• Cyclophosphamide</li> <li>• Etoposide</li> <li>• Pembrolizumab<sup>q,r</sup></li> <li>• Pentostatin</li> <li>• Temozolomide for CNS involvement</li> <li>• Bortezomib (category 2B)</li> <li>• See <a href="#">TCEL-B 2 of 5</a> for regimens listed for PTCL-NOS<sup>o</sup></li> </ul>

<sup>a</sup> See references for regimens [MFSS-A 4 of 6](#), [MFSS-A 5 of 6](#), and [MFSS-A 6 of 6](#).

<sup>b</sup> The optimal treatment for any patient at any given time is often individualized based on symptoms of disease, route of administration, toxicities, and overall goals of therapy. Laboratory studies for triglycerides, and thyroid function tests (with free thyroxine T4) are recommended for patients receiving bexarotene.

<sup>h</sup> Safety of combining TSEBT with systemic retinoids, HDAC inhibitors (such as vorinostat or romidepsin), or mogamulizumab, or combining phototherapy with vorinostat, romidepsin, or mogamulizumab is unknown.

<sup>i</sup> In the ALCANZA trial (Prince HM, et al. Lancet 2017;390:555-566) brentuximab vedotin (BV) was associated with superior clinical outcome in patients with CD30+ MF and pcALCL. CD30 positivity was defined as CD30 expression ≥10% of total lymphoid cells. However, in other clinical studies, clinical responses with BV have been reported across all CD30 expression levels including negligible CD30 expression.

<sup>j</sup> Patients with Sézary syndrome were excluded from the ALCANZA trial.

<sup>k</sup> See [Supportive Care for Patients with Cutaneous Lymphomas \(PCLYM-C\)](#).

<sup>l</sup> ECP may be more appropriate as systemic therapy in patients with some blood involvement (B1 or B2).

<sup>m</sup> Peginterferon alfa-2a may be substituted for other interferon preparations. Schiller M, et al. J Eur Acad Dermatol Venerol 2017;31:1841-1847.

<sup>n</sup> Patients with LCT were excluded from the MAVORIC trial.

<sup>o</sup> Multiagent chemotherapy regimens are generally reserved for patients with relapsed/refractory or extracutaneous disease. Most patients are treated with multiple SYST-CAT A/B before receiving multiagent chemotherapy.

<sup>p</sup> Lower doses of alemtuzumab administered subcutaneously have shown lower incidence of infectious complications. While alemtuzumab is no longer commercially available, it may be obtained for clinical use. Recommend CMV monitoring or prophylaxis. ([See PCLYM-C](#)).

<sup>q</sup> Preliminary phase II data in patients with MF and SS. Disease flare is seen in some patients (especially in erythrodermic skin/Sézary patients) and should be distinguished from disease progression. Khodadoust MS, et al. J Clin Oncol 2020;38:20-28.

<sup>r</sup> Rapid progression has been reported in HTLV positive patients receiving pembrolizumab.

**Note:** All recommendations are category 2A unless otherwise indicated.

**Clinical Trials:** NCCN believes that the best management of any patient with cancer is in a clinical trial. Participation in clinical trials is especially encouraged.



# NCCN Guidelines Version 2.2021

## Mycosis Fungoides/Sezary Syndrome

### SUGGESTED TREATMENT REGIMENS<sup>a,b</sup>

#### ERYTHRODERMIC DISEASE/SÉZARY SYNDROME

<i>Low-Intermediate Burden (eg, absolute Sézary cell [ASC] count &lt;5 K/mm<sup>3</sup>)<sup>s</sup></i>	<i>Higher Burden (eg, ASC &gt;5 K/mm<sup>3</sup>)<sup>s</sup></i>
<b>Preferred Regimens</b> <ul style="list-style-type: none"> <li>Combination therapies (see below)</li> <li>SYST-CAT A (<a href="#">See MFSS-A 2 of 6</a>) ± skin-directed therapies (skin-generalized)</li> </ul> <b>Other Recommended Regimens</b> <ul style="list-style-type: none"> <li>SYST-CAT B (<a href="#">See MFSS-A 2 of 6</a>) ± skin-directed therapies (skin-generalized)</li> <li>Alemtuzumab<sup>p</sup></li> <li>Pembrolizumab<sup>q,r</sup></li> </ul>	<b>Preferred Regimens</b> <ul style="list-style-type: none"> <li>Combination therapies (see below)</li> <li>Mogamulizumab ± skin-directed therapies (skin-generalized)<sup>h</sup></li> <li>Romidepsin ± skin-directed therapies (skin-generalized)<sup>h</sup></li> </ul> <b>Other Recommended Regimens</b> <ul style="list-style-type: none"> <li>SYST-CAT A (options not listed under preferred regimens) (<a href="#">See MFSS-A 2 of 6</a>)</li> <li>SYST-CAT B (<a href="#">See MFSS-A 2 of 6</a>)</li> <li>Alemtuzumab<sup>p</sup></li> <li>Pembrolizumab<sup>q,r</sup></li> </ul>

#### COMBINATION THERAPIES (alphabetical order)

<i>Skin-directed + systemic</i>	<ul style="list-style-type: none"> <li>Phototherapy + ECP<sup>l</sup></li> <li>Phototherapy + interferon (IFN alfa-2b<sup>m</sup> or IFN gamma-1b)</li> <li>Phototherapy + retinoid</li> <li>TSEBT + ECP<sup>l</sup></li> </ul>
<i>Systemic + systemic</i>	<ul style="list-style-type: none"> <li>ECP<sup>l</sup> + interferon (IFN alfa-2b<sup>m</sup> or IFN gamma-1b)</li> <li>ECP<sup>l</sup> + retinoid</li> <li>ECP<sup>l</sup> + retinoid + interferon (IFN alfa-2b<sup>m</sup> or IFN gamma-1b)</li> <li>Retinoid + interferon (IFN alfa-2b<sup>m</sup> or IFN gamma-1b)</li> </ul>

<sup>a</sup> See references for regimens [MFSS-A 4 of 6](#), [MFSS-A 5 of 6](#), and [MFSS-A 6 of 6](#).

<sup>b</sup> The optimal treatment for any patient at any given time is often individualized based on symptoms of disease, route of administration, toxicities, and overall goals of therapy.

<sup>h</sup> Safety of combining TSEBT with systemic retinoids, HDAC inhibitors (such as vorinostat or romidepsin), or mogamulizumab, or combining phototherapy with vorinostat, romidepsin, or mogamulizumab is unknown.

<sup>l</sup> ECP may be more appropriate as systemic therapy in patients with some blood involvement (B1 or B2).

<sup>m</sup> Peginterferon alfa-2a may be substituted for other interferon preparations. Schiller M, et al. J Eur Acad Dermatol Venerol 2017;31:1841-1847.

<sup>p</sup> Lower doses of alemtuzumab administered subcutaneously have shown lower incidence of infectious complications. While alemtuzumab is no longer commercially available, it may be obtained for clinical use. Recommend CMV monitoring or prophylaxis. ([See PCLYMP-C](#)).

<sup>q</sup> Preliminary phase II data in patients with MF and SS. Disease flare is seen in some patients (especially in erythrodermic skin/Sézary patients) and should be distinguished from disease progression. Khodadoust MS, et al. J Clin Oncol 2020;38:20-28.

<sup>r</sup> Rapid progression has been reported in HTLV-positive patients receiving pembrolizumab.

<sup>s</sup> Olsen E, et al. J Clin Oncol 2011;29:2598-2607.

**Note:** All recommendations are category 2A unless otherwise indicated.

**Clinical Trials:** NCCN believes that the best management of any patient with cancer is in a clinical trial. Participation in clinical trials is especially encouraged.





# NCCN Guidelines Version 2.2021

## Mycosis Fungoides/Sezary Syndrome

### SUGGESTED TREATMENT REGIMENS

#### References

#### **Skin-Directed Therapies**

##### **Topical corticosteroids**

Zackheim HS, Kashani-Sabet M, Amin S. Topical corticosteroids for mycosis fungoides. Experience in 79 patients. Arch Dermatol 1998;134(8):949-954.

Zackheim HS. Treatment of patch stage mycosis fungoides with topical corticosteroids. Dermatol Ther 2003;16:283-287.

##### **Nitrogen mustard (mechlorethamine hydrochloride)**

Kim YH, Martinez G, Varghese A, Hoppe RT. Topical nitrogen mustard in the management of mycosis fungoides: Update of the Stanford experience. Arch Dermatol 2003;139:165-173.

Lessin SR, Duvic M, Guitart J, et al. Topical chemotherapy in cutaneous T-cell lymphoma: positive results of a randomized, controlled, multicenter trial testing the efficacy and safety of a novel mechlorethamine, 0.02%, gel in mycosis fungoides. JAMA Dermatol 2013;149:25-32.

##### **Local radiation**

Wilson LD, Kacinski BM, Jones GW. Local superficial radiotherapy in the management of minimal stage IA cutaneous T-cell lymphoma (Mycosis Fungoides). Int J Radiat Oncol Biol Phys 1998;40:109-115.

Neelis KJ, Schimmel EC, Vermeer MH, et al. Low-dose palliative radiotherapy for cutaneous B- and T-cell lymphomas. Int J Radiat Oncol Biol Phys 2009;74:154-158.

Thomas TO, Agrawal P, Guitart J, et al. Outcome of patients treated with a single-fraction dose of palliative radiation for cutaneous T-cell lymphoma. Int J Radiat Oncol Biol Phys 2013;85:747-753.

##### **Topical bexarotene**

Breneman D, Duvic M, Kuzel T, et al. Phase 1 and 2 trial of bexarotene gel for skin directed treatment of patients with cutaneous T cell lymphoma. Arch Dermatol 2002;138:325-332.

Heald P, Mehlmayer M, Martin AG, et al. Topical bexarotene therapy for patients with refractory or persistent early stage cutaneous T cell lymphoma: results of the phase III clinical trial. J Am Acad Dermatol 2003;49:801-815.

##### **Tazarotene gel**

Apisarnthanarax N, Talpur R, Ward S, Ni X, Kim HW, Duvic M. Tazarotene 0.1% gel for refractory mycosis fungoides lesions: an open-label pilot study. J Am Acad Dermatol 2004;50:600-607.

##### **Topical imiquimod**

Deeths MJ, Chapman JT, Dellavalle RP, Zeng C, Aeling JL. Treatment of patch and plaque stage mycosis fungoides with imiquimod 5% cream. J Am Acad Dermatol 2005;52:275-280.

##### **Phototherapy (UVB and PUVA)**

Gathers RC, Scherschun L, Malick F, Fivenson DP, Lim HW. Narrowband UVB phototherapy for early stage mycosis fungoides. J Am Acad Dermatol 2002;47:191-197.

Querfeld C, Rosen ST, Kuzel TM, et al. Long term follow up of patients with early stage cutaneous T cell lymphoma who achieved complete remission with psoralen plus UVA monotherapy. Arch Dermatol 2005;141:305-311.

Ponte P, Serrao V, Apetato M. Efficacy of narrowband UVB vs. PUVA in patients with early-stage mycosis fungoides. J Eur Acad Dermatol Venereol 2010;24:716-721.

Olsen EA, Hodak E, Anderson T, et al. Guidelines for phototherapy of mycosis fungoides and Sézary syndrome: A consensus statement of the United States Cutaneous Lymphoma Consortium. J Am Acad Dermatol 2018;74:27-58.

##### **Total skin electron beam therapy (TSEBT)**

Chinn DM, Chow S, Kim YH, Hoppe RT. Total skin electron beam therapy with or without adjuvant topical nitrogen mustard or nitrogen mustard alone as initial treatment of T2 and T3 mycosis fungoides. Int J Radiat Oncol Biol Phys 1999;43:951-958.

Ysebaert L, Truc G, Dalac S et al. Ultimate results of radiation therapy for T1-T2 mycosis fungoides. Int J Radiat Oncol Biol Phys 2004;58:1128-1134.

Hoppe RT, Harrison C, Tavallaee M, et al. Low-dose total skin electron beam therapy as an effective modality to reduce disease burden in patients with mycosis fungoides: results of a pooled analysis from 3 phase-II clinical trials. J Am Acad Dermatol 2015;72:286-292.

Morris S, Scarisbrick J, Frew J, et al. The results of low-dose total skin electron beam radiation therapy (TSEB) in patients with mycosis fungoides from the UK Cutaneous Lymphoma Group. Int J Radiat Oncol Biol Phys 2018;99(3):627-633.

##### **Systemic Therapies**

##### **Alemtuzumab for Sézary syndrome ± lymph node disease**

Lundin J, Hagberg H, Repp R, et al. Phase 2 study of alemtuzumab (anti-CD52 monoclonal antibody) in patients with advanced mycosis fungoides/Sezary syndrome. Blood 2003;101:4267-4272.

Bernengo MG, Quaglini P, Comessatti A, et al. Low-dose intermittent alemtuzumab in the treatment of Sézary syndrome: clinical and immunologic findings in 14 patients. Haematologica 2007;92:784-794.

Gautschi O, Blumenthal N, Streit M, et al. Successful treatment of chemotherapy-refractory Sézary syndrome with alemtuzumab (Campath-1H). Eur J Haematol 2004;72:61-63.

Querfeld C, Mehta N, Rosen ST, et al. Alemtuzumab for relapsed and refractory erythrodermic cutaneous T-cell lymphoma: a single institution experience from the Robert H. Lurie Comprehensive Cancer Center. Leuk Lymphoma 2009;50:1969-1976.

##### **Bortezomib**

Zinzani PL, Musuraca G, Tani M, et al. Phase II trial of proteasome inhibitor bortezomib in patients with relapsed or refractory cutaneous T-cell lymphoma. J Clin Oncol 2007;25:4293-4297.

##### **Brentuximab vedotin**

Kim YH, Tavallaee M, Sundram U, et al. Phase II investigator-initiated study of brentuximab vedotin in mycosis fungoides and Sézary syndrome with variable CD30 expression level: A multi-institution collaborative project. J Clin Oncol 2015;33:3750-3758.

Prince HM, Kim YH, Horwitz SM, et al. Brentuximab vedotin or physician's choice in CD30-positive cutaneous T-cell lymphoma (ALCANZA): an international, open-label, randomised, phase 3, multicentre trial. The Lancet 2018;390:555-566.

##### **Extracorporeal photopheresis (ECP)**

Talpur R, Demierre MF, Geskin L, et al. Multicenter photopheresis intervention trial in early-stage mycosis fungoides. Clin Lymphoma Myeloma Leuk 2011;11:219-227.

Knobler R, Duvic M, Querfeld C, et al. Long-term follow-up and survival of cutaneous T-cell lymphoma patients treated with extracorporeal photopheresis. Photodermatol Photoimmunol Photomed 2012;28:250-257.

Atilla E, Atilla PA, Bozdogan SC, et al. Extracorporeal photochemotherapy in mycosis fungoides. Transfus Clin Biol 2017;24:454-457.

Gao C, McCormack C, van der Weyden C, et al. Prolonged survival with the early use of a novel extracorporeal photopheresis regimen in patients with Sézary syndrome. Blood 2019;134:1346-1350.

**Note:** All recommendations are category 2A unless otherwise indicated.

**Clinical Trials:** NCCN believes that the best management of any patient with cancer is in a clinical trial. Participation in clinical trials is especially encouraged.

[Continued](#)





# NCCN Guidelines Version 2.2021

## Mycosis Fungoides/Sezary Syndrome

### SUGGESTED TREATMENT REGIMENS

#### References

#### **Systemic Therapies Continued**

##### **Gemcitabine**

Duvic M, Talpur R, Wen S, et al. Phase II evaluation of gemcitabine monotherapy for cutaneous T-cell lymphoma. *Clin Lymphoma Myeloma* 2006;7:51-58.

Marchi E, Alinari L, Tani M, et al. Gemcitabine as frontline treatment for cutaneous T-cell lymphoma: phase II study of 32 patients. *Cancer* 2005;104:2437-2441.

Zinzani PL, Baliva G, Magagnoli M, et al. Gemcitabine treatment in pretreated cutaneous T-cell lymphoma: experience in 44 patients. *J Clin Oncol* 2000;18:2603-2606.

Zinzani PL, Venturini F, Stefoni V, et al. Gemcitabine as single agent in pretreated T-cell lymphoma patients: evaluation of the long-term outcome. *Ann Oncol* 2010;21:860-863.

Awar O, Duvic M. Treatment of transformed mycosis fungoides with intermittent low-dose gemcitabine. *Oncology* 2007;73:130-135.

##### **Interferon**

Olsen EA. Interferon in the treatment of cutaneous T-cell lymphoma. *Dermatol Ther* 2003;16:311-321.

Kaplan EH, Rosen ST, Norris DB, et al. Phase II study of recombinant human interferon gamma for treatment of cutaneous T-cell lymphoma. *J Natl Cancer Inst* 1990;82:208-212.

##### **Liposomal doxorubicin**

Wollina U, Dummer R, Brockmeyer NH, et al. Multicenter study of pegylated liposomal doxorubicin in patients with cutaneous T-cell lymphoma. *Cancer* 2003;98:993-1001.

Quereux G, Marques S, Nguyen J-M, et al. Prospective multicenter study of pegylated liposomal doxorubicin treatment in patients with advanced or refractory mycosis fungoides or Sezary syndrome. *Arch Dermatol* 2008;144:727-733.

Dummer R, Quaglino P, Becker JC, et al. Prospective international multicenter phase II trial of intravenous pegylated liposomal doxorubicin monotherapy in patients with stage IIB, IVA, or IVB advanced mycosis fungoides: final results from EORTC 21012. *J Clin Oncol* 2012;30:4091-4097.

##### **Methotrexate**

Zackheim HS, Kashani-Sabet M, Hwang ST. Low-dose methotrexate to treat erythrodermic cutaneous T-cell lymphoma: results in twenty-nine patients. *J Am Acad Dermatol* 1996;34:626-631.

Zackheim HS, Kashani-Sabet M, McMillan A. Low-dose methotrexate to treat mycosis fungoides: a retrospective study in 69 patients. *J Am Acad Dermatol* 2003;49:873-878.

##### **Mogamulizumab**

Kim YH, Bagot M, Pinter-Brown L et al. Mogamulizumab versus vorinostat in previously treated cutaneous T-cell lymphoma (MAVORIC): An international, open-label, randomised, controlled phase 3 trial. *Lancet Oncol* 2018;19:1192-1204.

##### **Pembrolizumab**

Khodadoust MS, Rook AH, Porcu P, et al. Pembrolizumab in relapsed and refractory mycosis fungoides and Sezary syndrome: A multicenter phase II study. *J Clin Oncol* 2020;38:20-28.

##### **Pentostatin**

Cummings FJ, Kim K, Neiman RS, et al. Phase II trial of pentostatin in refractory lymphomas and cutaneous T-cell disease. *J Clin Oncol* 1991;9:565-571.

Greiner D, Olsen EA, Petroni G. Pentostatin (2'-deoxycytosine) in the treatment of cutaneous T-cell lymphoma. *J Am Acad Dermatol* 1997;36:950-955.

Tsimberidou AM, Giles F, Duvic M, Fayad L, Kurzrock R. Phase II study of pentostatin in advanced T-cell lymphoid malignancies. Update on an M.D. Anderson Cancer Center Series. *Cancer* 2004;100:342-349.

##### **Pralatrexate**

Horwitz SM, Kim YH, Foss F, et al. Identification of an active, well-tolerated dose of pralatrexate in patients with relapsed or refractory cutaneous T-cell lymphoma. *Blood* 2012;119:4115-4122.

Foss F, Horwitz SM, Coiffier B, et al. Pralatrexate is an effective treatment for relapsed or refractory transformed mycosis fungoides: a subgroup efficacy analysis from the PROPEL study. *Clin Lymphoma Myeloma Leuk* 2012;12:238-243.

##### **Romidepsin**

Piekarz RL, Frye R, Turner M, et al. Phase II multi-institutional trial of the histone deacetylase inhibitor romidepsin as monotherapy for patients with cutaneous T-cell lymphoma. *J Clin Oncol* 2009;27:5410-5417.

Whittaker SJ, Demierre MF, Kim EJ, et al. Final results from a multicenter, international, pivotal study of romidepsin in refractory cutaneous T-cell lymphoma. *J Clin Oncol* 2010; 28:4485-4491.

##### **Retinoids**

Zhang C, Duvic M. Treatment of cutaneous T-cell lymphoma with retinoids. *Dermatol Ther* 2006;19:264-271.

Duvic M, Martin AG, Kim Y, et al. Phase 2 and 3 clinical trial of oral bexarotene (Targretin capsules) for the treatment of refractory or persistent early-stage cutaneous T-cell lymphoma. *Arch Dermatol* 2001;137:581-593.

Duvic M, Hymes K, Heald P, et al. Bexarotene is effective and safe for treatment of refractory advanced-stage cutaneous T-cell lymphoma: multinational phase II-III trial results. *J Clin Oncol* 2001;19:2456-2471.

##### **Temozolomide**

Tani M, Fina M, Alinari L, et al. Phase II trial of temozolomide in patients with pretreated cutaneous T-cell lymphoma. *Haematologica* 2005;90(9):1283-1284.

Querfeld C, Rosen ST, Guitart J, et al. Multicenter phase II trial of temozolomide in mycosis fungoides/sezary syndrome: correlation with O<sup>6</sup>-methylguanine-DNA methyltransferase and mismatch repair proteins. *Clin Cancer Res* 2011;17:5748-5754.

##### **Vorinostat**

Duvic M, Talpur R, Ni X, et al. Phase 2 trial of oral vorinostat (suberoylanilide hydroxamic acid, SAHA) for refractory cutaneous T-cell lymphoma (CTCL). *Blood* 2007;109:31-39.

Olsen EA, Kim YH, Kuzel TM, et al. Phase IIb multicenter trial of vorinostat in patients with persistent, progressive, or treatment refractory cutaneous T-cell lymphoma. *J Clin Oncol* 2007;25:3109-3115.

Duvic M, Olsen EA, Breneman D, et al. Evaluation of the long-term tolerability and clinical benefit of vorinostat in patients with advanced cutaneous T-cell lymphoma. *Clin Lymphoma Myeloma* 2009;9:412-416.

**Note:** All recommendations are category 2A unless otherwise indicated.

**Clinical Trials:** NCCN believes that the best management of any patient with cancer is in a clinical trial. Participation in clinical trials is especially encouraged.

[Continued](#)

**MFSS-A**  
**5 OF 6**



### SUGGESTED TREATMENT REGIMENS

#### References

#### **Combination Therapies**

##### **Skin-directed + systemic**

Rupoli S, Goteri G, Pulini S, et al. Long term experience with low dose interferon alpha and PUVA in the management of early mycosis fungoides. *Eur J Haematol* 2005;75:136-145.

Kuzel T, Roenigk H Jr, Samuelson E, et al. Effectiveness of interferon alfa-2a combined with phototherapy for mycosis fungoides and the Sézary syndrome. *J Clin Oncol* 1995;13:257-263.

McGinnis K, Shapiro M, Vittorio C, et al. Psoralen plus long wave UV A (PUVA) and bexarotene therapy: An effective and synergistic combined adjunct to therapy for patients with advanced cutaneous T cell lymphoma. *Arch Dermatol* 2003;139:771-775.

Wilson LD, Jones GW, Kim D, et al. Experience with total skin electron beam therapy in combination with extracorporeal photopheresis in the management of patients with erythrodermic (T4) mycosis fungoides. *J Am Acad Dermatol* 2000;43:54-60.

Stadler R, Otte H-G, Luger T, et al. Prospective randomized multicenter clinical trial on the use of interferon alpha -2a plus acitretin versus interferon alpha -2a plus PUVA in patients with cutaneous T-cell lymphoma stages I and II. *Blood* 1998;92:3578-3581.

##### **Systemic + systemic**

Straus DJ, Duvic M, Kuzel T, et al. Results of a phase II trial of oral bexarotene (Targretin) combined with interferon alfa 2b (Intron A) for patients with cutaneous T cell lymphoma. *Cancer* 2007;109:1799-1803.

Talpur R, Ward S, Apisarnthanarax N, et al. Optimizing bexarotene therapy for cutaneous T cell lymphoma. *J Am Acad Dermatol* 2002;47:672-684.

Suchin KR, Cucchiara AJ, Gottlieb SL, et al. Treatment of cutaneous T-cell lymphoma with combined immunomodulatory therapy: a 14-year experience at a single institution. *Arch Dermatol*. 2002;138:1054-1060.

Raphael BA, Shin DB, Suchin KR, et al. High clinical response rate of Sezary syndrome to immunomodulatory therapies: prognostic markers of response. *Arch Dermatol* 2011;147:1410-1415.

#### **Allogeneic Hematopoietic Cell Transplant**

de Masson A, Beylot-Barry M, Bouaziz J, et al. Allogeneic stem cell transplantation for advanced cutaneous T-cell lymphomas: a study from the French Society of Bone Marrow Transplantation and French Study Group on Cutaneous Lymphomas. *Haematologica* 2014;99:527-534.

Duarte R, Boumendil A, Onida F, et al. Long-term outcome of allogeneic hematopoietic cell transplantation for patients with mycosis fungoides and Sézary syndrome: a European society for blood and marrow transplantation lymphoma working party extended analysis. *J Clin Oncol* 2014;32:3347-3348.

Duarte RF, Schmitz N, Servitje O, Sureda A. Haematopoietic stem cell transplantation for patients with primary cutaneous T-cell lymphoma. *Bone Marrow Transplant* 2008;41:597-604.

Hosing C, Bassett R, Dabaja B, et al. Allogeneic stem-cell transplantation in patients with cutaneous lymphoma: updated results from a single institution. *Ann Oncol* 2015;26:2490-2495.

Iqbal M, Reljic T, Ayala E, et al. Efficacy of allogeneic hematopoietic cell transplantation in cutaneous T-cell lymphoma: Results of a systematic review and meta-analysis. *Biol Blood Marrow Transplant* 2020;26:76-82.

Johnson WT, Mukherji R, Kartan S, et al. Allogeneic hematopoietic stem cell transplantation in advanced stage mycosis fungoides and Sezary syndrome: a concise review. *Chin Clin Oncol* 2019;8:12.

Lechowicz M, Lazarus H, Carreras J, et al. Allogeneic hematopoietic cell transplantation for mycosis fungoides and Sezary syndrome. *Bone Marrow Transplant* 2014;49:1360-1365.

Wu PA, Kim YH, Lavori PW, Hoppe RT, Stockerl-Goldstein KE. A meta-analysis of patients receiving allogeneic or autologous hematopoietic stem cell transplant in mycosis fungoides and Sezary syndrome. *Biol Blood Marrow Transplant* 2009;15:982-990.

**Note:** All recommendations are category 2A unless otherwise indicated.

**Clinical Trials:** NCCN believes that the best management of any patient with cancer is in a clinical trial. Participation in clinical trials is especially encouraged.



# NCCN Guidelines Version 2.2021

## Mycosis Fungoides/Sezary Syndrome

### SUPPORTIVE CARE FOR PATIENTS WITH MF/SS

Collaboration with dermatologist for supportive care is essential.

#### Pruritus

##### • Assessment

- ▶ Pruritus should be assessed
- ▶ Correlation between sites of disease and localization of pruritus may be useful in tailoring therapy
- ▶ For severe or persistent pruritus despite therapeutic response other potential causes for pruritus should be investigated

##### • Treatment

- ▶ Co-management with a dermatologist with expertise in skin care and CTCL
- ▶ Optimized skin-directed and systemic therapy for MF/SS
- ▶ Mild, unscented soaps for bathing are gentle and optimal to prevent skin dryness
- ▶ Moisturizers/emollients
- ▶ Topical steroid application (appropriate strength for body region) ± occlusion<sup>1</sup>
- ▶ Topical over-the-counter preparations
- ▶ Systemic agents
  - ◊ First-line
    - H1 antihistamines; single agent or combination of antihistamines from different classes<sup>2</sup>
    - Gabapentin<sup>3,4</sup>
  - ◊ Second-line
    - Aprepitant<sup>5-8</sup>
    - Mirtazapine<sup>4</sup>
    - Selective serotonin reuptake inhibitors<sup>9</sup>
  - ◊ Third-line
    - Naltrexone<sup>10</sup>

#### Infections

##### • Active or suspected infections

- ▶ Cutaneous viral infections
  - ◊ High risk for skin dissemination of localized viral infections herpes simplex virus (HSV)/varicella zoster virus (VZV). HSV prophylaxis with acyclovir or equivalent should be considered for patients with frequent recurrence of HSV infection.
- ▶ Erythroderma:
  - ◊ Swab of skin, nares, or other areas for cultures of *Staphylococcus aureus* (*S. aureus*) infection or colonization
  - ◊ Intranasal mupirocin for *S. aureus* carriers
  - ◊ Oral dicloxacillin or cephalexin
  - ◊ Sulfamethoxazole/trimethoprim, doxycycline, minocycline, or clindamycin if suspected methicillin-resistant *staphylococcus aureus* (MRSA)
  - ◊ Vancomycin if no improvement or documented bacteremia
  - ◊ Bleach baths [1/2 cup of regular strength bleach (5%–6%) in full tub of water] or for limited areas, soaks (1 tsp of bleach in a gallon of water). Bleach baths should be taken for 5 to 10 minutes two to three times a week maximum followed by tap water to rinse off the bleach water. Moisturizer should be put on immediately following the bleach bath or soak.
- ▶ Ulcerated and necrotic tumors:
  - ◊ Infection or colonization with Gram-negative rods should be considered in addition to the more common gram-positive organisms.
- Prophylaxis
  - ▶ Optimize skin barrier protection with moisturizing of skin
  - ▶ Consider mupirocin in nares for *S. aureus* carriage
  - ▶ Diluted bleach baths or soaks (if limited area) as noted above
  - ▶ Minimize use of central lines when possible
  - ▶ For patients receiving alemtuzumab, [see PCLYM-C](#)

[Continued](#)

**Note:** All recommendations are category 2A unless otherwise indicated.

**Clinical Trials:** NCCN believes that the best management of any patient with cancer is in a clinical trial. Participation in clinical trials is especially encouraged.



### SUPPORTIVE CARE FOR PATIENTS WITH MF/SS

#### REFERENCES

- <sup>1</sup> Yosipovitch G, Szolar C, Hui XY, Maibach H. High-potency topical corticosteroid rapidly decrease histamine-induced itch but not thermal sensation and pain in human beings. *J Am Acad Dermatol* 1996;35:118-120.
- <sup>2</sup> Eschler D, Klein PA. An evidence-based review of the efficacy of topical antihistamines in the relief of pruritus. *J Drugs Dermatol* 2010;9:992-997.
- <sup>3</sup> Matsuda KM, Sharma D, Schonfeld AR, Kwatra SG. Gabapentin and pregabalin for the treatment of chronic pruritus. *J Am Acad Dermatol* 2018;75:619-625.
- <sup>4</sup> Demierre MF, Taverna J. Mirtazapine and gabapentin for reducing pruritus in cutaneous T-cell lymphoma. *Am Acad Dermatol* 2006;55:543-544.
- <sup>5</sup> Jiménez Gallo D, Albarrán Planelles C, Linares Barrios M, et al. Treatment of pruritus in early-stage hypopigmented mycosis fungoides with aprepitant. *Dermatol Ther* 2014;27:178-182.
- <sup>6</sup> Duval A, Dubertret L. Aprepitant as an antipruritic agent? *N Engl J Med* 2009;361:1415-1416.
- <sup>7</sup> Booken N, Heck M, Nicolay JP, et al. Oral aprepitant in the therapy of refractory pruritus in erythrodermic cutaneous T-cell lymphomas. *Br J Dermatol* 2011;164:665–667.
- <sup>8</sup> Ladizinski B, Bazakas A, Olsen EA. Aprepitant: A novel neurokinin-1 receptor/substance P antagonist as antipruritic therapy in cutaneous T-cell lymphoma. *Am Acad Dermatol* 2012;67:E198-E199.
- <sup>9</sup> Ständer S, Böckenholt B, Schürmeyer-Horst F, et al. Treatment of chronic pruritus with the selective serotonin re-uptake inhibitors paroxetine and fluvoxamine: results of an open-labelled, two-arm proof-of-concept study. *Acta Derm Venereol* 2009;89:45-51.
- <sup>10</sup> Brune A, Metze D, Luger T, Ständer S. Antipruritic therapy with the oral opioid receptor antagonist naltrexone. Open, non-placebo controlled administration in 133 patients. *Hautarzt* 2004;55:1130-1136.

**Note:** All recommendations are category 2A unless otherwise indicated.

**Clinical Trials:** NCCN believes that the best management of any patient with cancer is in a clinical trial. Participation in clinical trials is especially encouraged.

**OVERVIEW & DEFINITION**

- Primary cutaneous CD30+ T-cell lymphoproliferative disorders (LPDs) represent a spectrum that includes primary cutaneous anaplastic large cell lymphoma (ALCL), lymphomatoid papulosis, and “borderline” cases with overlapping clinical and histopathologic features.<sup>a,b,c</sup>
- Clinical correlation with histopathologic features is essential for establishing the diagnosis of primary cutaneous CD30+ T-cell LPDs; diagnosis cannot be made based on pathology review alone.

***Differential Diagnosis***

- It is critical to distinguish CD30+ T-cell LPDs from other CD30+ processes involving the skin that include:
  - ▶ Systemic lymphomas (eg, systemic ALCL, ATLL, PTCL);
  - ▶ Other cutaneous process such as other CD30+ skin lymphomas such as mycosis fungoides (MF), especially transformed MF, cytotoxic T-cell lymphomas; and
  - ▶ Benign disorders such as lymphomatoid drug reactions, arthropod bites, viral infections, and others.
- Lymphomatoid drug reactions have been linked with certain drugs (eg, amlodipine, carbamazepine, cefuroxime, valsartan) and may be associated with CD30+ atypical large cells in histology.
- MF and primary cutaneous CD30+ T-cell LPD can coexist in the same patient.

- Primary cutaneous ALCL (PC-ALCL)
  - ▶ Represents about 8% of cutaneous lymphoma cases.<sup>a</sup>
  - ▶ Unlike systemic ALCL, PC-ALCL typically follows an indolent course and although cutaneous relapses are common an excellent prognosis is usually maintained.<sup>d,e</sup>
  - ▶ Histologically characterized by diffuse, cohesive sheets of large CD30-positive (in >75%) cells with anaplastic, pleomorphic, or immunoblastic appearance.<sup>a</sup>
  - ▶ Clinical features typically include solitary or localized nodules or tumors (often ulcerated); multifocal lesions occur in about 20% of cases. Extracutaneous disease occurs in about 10% of cases, usually involving regional lymph nodes.<sup>a</sup> Patches and plaques may also be present and some degree of spontaneous remittance in lesions may also be seen.
- Lymphomatoid papulosis (LyP)
  - ▶ LyP has been classified (WHO-EORTC) under lymphomas but may be best classified as an LPD as it is a frequently spontaneously regressing process.<sup>a</sup>
  - ▶ LyP has been reported to be associated with other lymphomas such as MF, PC-ALCL, systemic ALCL, or Hodgkin lymphoma.<sup>f,9</sup>
  - ▶ LyP is histologically heterogeneous with large atypical anaplastic, immunoblastic, or Hodgkin-like cells in a marked inflammatory background;<sup>a</sup> several histologic subtypes can be defined based on evolution of skin lesions.<sup>f</sup>
  - ▶ LyP clinical features are characterized by chronic, recurrent, spontaneously regressing papulonodular (grouped or generalized) skin lesions.<sup>a,f</sup>

<sup>a</sup> Swerdlow SH, Harris NL, Jaffe ES, et al. WHO Classification of Tumours of Haematopoietic and Lymphoid Tissues. Revised 4th ed. Lyon, France: IARC; 2017.

<sup>b</sup> Vergier B, et al. Am J Surg Pathol 1998;22:1192-1202.

<sup>c</sup> Liu HL, et al. J Am Acad Dermatol 2003;49:1049-1058.

<sup>d</sup> Benner MF, Willemze R. Arch Dermatol 2009;145:1399-1404.

<sup>e</sup> Woo DK, et al. Arch Dermatol 2009;145:667-674.

<sup>f</sup> Kempf W, et al. Blood 2011;118:4024-4035.

<sup>9</sup> Due to overlapping immunophenotype and morphology, need to use caution to *not* diagnose CD30+ T-cell in lymph nodes as HL (Eberle FC, et al. Amer J Surg Pathol 2012;36:716-725.)

**Note:** All recommendations are category 2A unless otherwise indicated.

**Clinical Trials:** NCCN believes that the best management of any patient with cancer is in a clinical trial. Participation in clinical trials is especially encouraged.

[See Diagnosis  
\(PCTLD-1\)](#)





# NCCN Guidelines Version 2.2021

## Primary Cutaneous CD30+ T-Cell Lymphoproliferative Disorders

### DIAGNOSIS<sup>a</sup>

#### ESSENTIAL:

- Clinical presentation: see Overview and Definition ([PCTLD/INTRO-1](#))
- Clinical pathologic correlation is essential
- Complete skin examination for evidence of MF
- Biopsy of suspicious skin sites
  - Review of all slides with at least one paraffin block representative of the tumor should be done by a pathologist with expertise in the diagnosis of CTCLs. Rebiopsy if consult material in conjunction with the clinical picture is nondiagnostic.
  - Biopsy of all types (punch, incisional, or excisional) of clinical lesions present will aid in final diagnosis.
- Adequate immunophenotyping to establish diagnosis<sup>b,c</sup> on skin biopsy:
  - IHC: CD3, CD4, CD8, CD20, CD30, CD56, ALK<sup>d</sup>

#### USEFUL UNDER CERTAIN CIRCUMSTANCES:

- On skin biopsy, expanded IHC: CD2, CD5, CD7, CD25, TIA1, granzyme B, perforin, GM1, EBER-ISH, IRF4/MUM1, EMA
- Molecular analysis to detect clonal *TCR* gene rearrangements or other assessment of clonality<sup>a,e</sup>
- FISH: *ALK* and *DUSP22* gene rearrangements<sup>a</sup>
- Excisional or incisional biopsy of suspicious lymph nodes
- Assessment of HTLV-1 serology<sup>f</sup> is encouraged as results can impact therapy

• Cutaneous ALCL  
• LyP<sup>g</sup> → [See Workup \(PCTLD-2\)](#)

CD30+ transformed mycosis fungoides → [See NCCN Guidelines for Mycosis Fungoides \(MFSS-1\)](#)

<sup>a</sup> See [Principles of Molecular Analysis in Cutaneous Lymphomas \(PCLYM-B\)](#).

<sup>b</sup> See [Use of Immunophenotyping/Genetic Testing in Differential Diagnosis of Mature B-Cell and NK/T-Cell Neoplasms \(See NCCN Guidelines for B-Cell Lymphomas\)](#).

<sup>c</sup> Typical immunophenotype: CD30+ (>75% cells), CD4+ variable loss of CD2/CD5/CD3, CD8+ (<5%) cytotoxic granule proteins positive.

<sup>d</sup> ALK positivity and t(2;5) translocation is typically absent in PC-ALCL and LyP.

<sup>e</sup> Clonal *TCR* gene rearrangements alone are not sufficient for diagnosis, as these can also be seen in patients with non-malignant conditions. Results should be interpreted in the context of overall presentation. See [Principles of Molecular Analysis in T-Cell Lymphomas \(PCLYM-A\)](#).

<sup>f</sup> See [map](#) for prevalence of HTLV-1/2 by geographic region. HTLV-1 has been described in patients in non-endemic areas.

<sup>g</sup> LyP is not considered a malignant disorder; however, there is an association with other lymphoid malignancy (MF or PC-ALCL). Staging studies are done in LyP only if there is suspicion of systemic involvement by an associated lymphoma.

**Note:** All recommendations are category 2A unless otherwise indicated.

**Clinical Trials:** NCCN believes that the best management of any patient with cancer is in a clinical trial. Participation in clinical trials is especially encouraged.



**WORKUP****ESSENTIAL:**

- History and complete physical examination including complete skin examination;<sup>h</sup> palpation of peripheral lymph node regions; liver or spleen enlargement
- CBC with differential
- Comprehensive metabolic panel
- LDH
- C/A/P CT with contrast or integrated whole body PET/CT (arms/legs included when disease assessment of entire body is needed)<sup>i</sup>
- Biopsy suspicious nodes<sup>j,k,l</sup>: Biopsy of enlarged lymph nodes or suspected extracutaneous sites (if biopsy of skin is not diagnostic). Excisional or incisional biopsy is preferred over core needle biopsy. An FNA alone is not sufficient for the initial diagnosis of lymphoma. A core needle biopsy is not optimal but can be used under certain circumstances. In certain circumstances, when a lymph node is not easily accessible for excisional or incisional biopsy, a combination of core needle biopsy and FNA in conjunction with appropriate ancillary techniques may be sufficient for diagnosis. Rebiopsy if consult material in conjunction with the clinical picture is nondiagnostic.
- Bone marrow aspiration and biopsy (optional for solitary C-ALCL or C-ALCL without extracutaneous involvement on imaging)

**USEFUL IN SELECTED CASES:**

- Pregnancy testing in women of childbearing age<sup>m</sup>
- Discussion of fertility and sperm banking, if fertility-impacting therapy is planned

Cutaneous  
ALCL →Primary  
cutaneous ALCL →Cutaneous  
ALCL with  
regional node →

Systemic ALCL →

[See Primary  
Treatment  
\(PCTLD-3\)](#)[See NCCN  
Guidelines for  
T-Cell  
Lymphomas  
- Peripheral  
T-Cell  
\(TCEL-1\)](#)LyP<sup>g</sup> →**ESSENTIAL:**

- History and complete physical examination including complete skin examination;<sup>h</sup> palpation of peripheral lymph node regions; liver or spleen enlargement
- CBC with differential
- Comprehensive metabolic panel
- LDH

**USEFUL IN SELECTED CASES:**

- Pregnancy testing in women of childbearing age<sup>l</sup>
- Discussion of fertility and sperm banking, if fertility-impacting therapy is planned
- C/A/P CT with contrast or integrated whole body PET/CT (arms/legs included when disease assessment of entire body is needed)<sup>g,i,n</sup> (not done for typical LyP)
- Bone marrow aspiration and biopsy (not done for typical LyP)<sup>g,n</sup>

[See Primary  
Treatment for  
LyP \(PCTLD-4\)](#)

<sup>g</sup> LyP is not considered a malignant disorder; however, there is an association with other lymphoid malignancy (MF or PC-ALCL). Staging studies are done in LyP only if there is suspicion of systemic involvement by an associated lymphoma.

<sup>h</sup> Monitoring the size and number of lesions will assist with response assessment.

<sup>i</sup> Patients with T-cell lymphomas often have extranodal disease, which may be inadequately imaged by CT. PET scan may be preferred in these instances.

<sup>j</sup> Due to overlapping immunophenotype and morphology, need to use caution to *not* diagnose CD30+ T-cell in lymph nodes as HL (Eberle F, et al. Amer J Surg Pathol 2012;36:716-725).

<sup>k</sup> Consider systemic ALCL, regional lymph node involvement with PC-ALCL, or lymph node involvement with transformed MF.

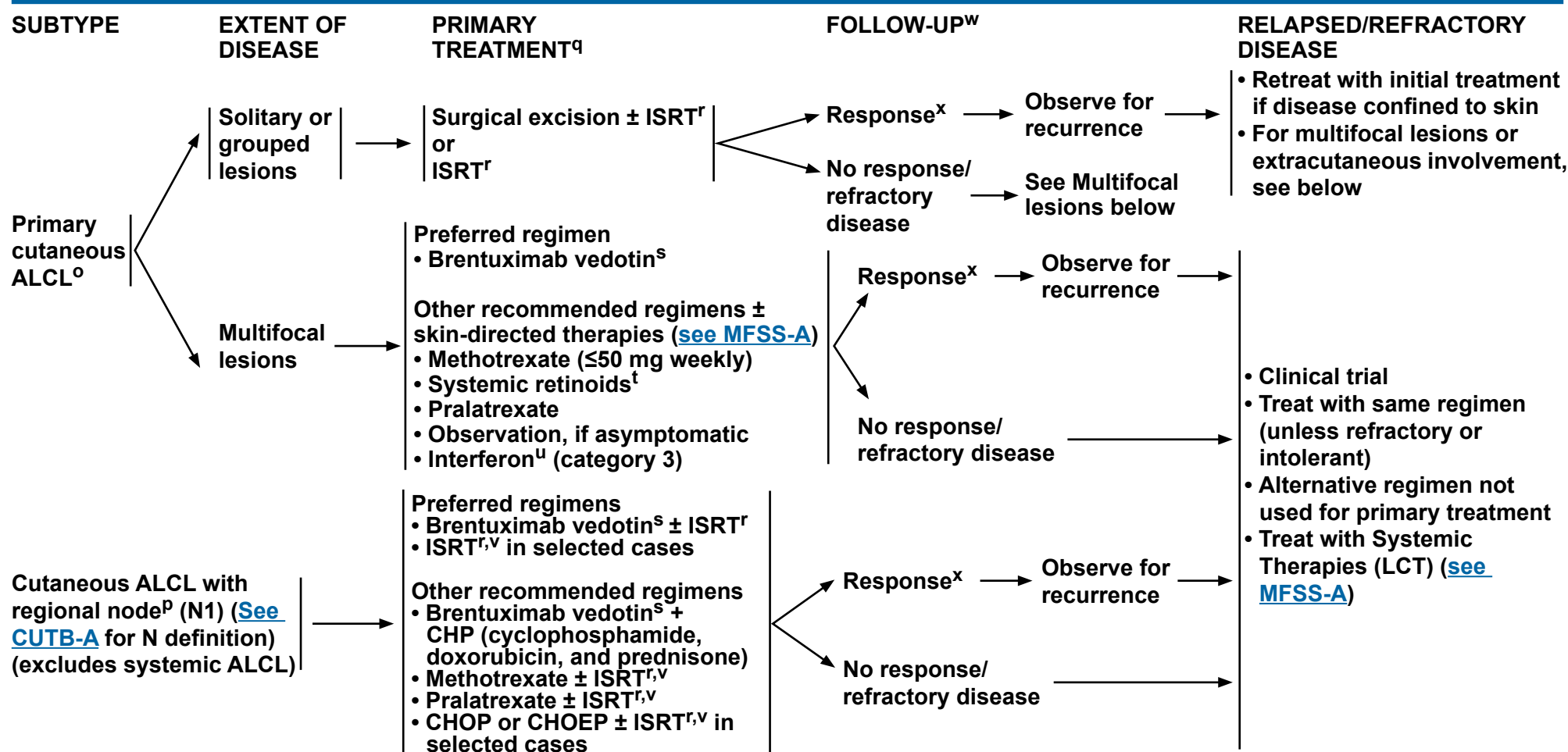
<sup>l</sup> Consider PC-ALCL if in draining lymph nodes only.

<sup>m</sup> Many skin-directed and systemic therapies are contraindicated or of unknown safety in pregnancy. Refer to individual drug information.

<sup>n</sup> Only done to exclude an associated lymphoma.

**Note:** All recommendations are category 2A unless otherwise indicated.

**Clinical Trials:** NCCN believes that the best management of any patient with cancer is in a clinical trial. Participation in clinical trials is especially encouraged.


<sup>o</sup> Regression of lesions may occur in up to 44% of cases.

<sup>p</sup> Biopsy-proven lymphoma in lymph node.

<sup>q</sup> [See Therapy References \(PCTLD-A\).](#)
<sup>r</sup> [See Principles of Radiation Therapy \(PCLYM-A\).](#)
<sup>s</sup> [See Supportive Care for Patients with Cutaneous Lymphomas \(PCLYMP-C\).](#)
<sup>t</sup> Limited data from case reports (eg, bexarotene).

<sup>u</sup> Peginterferon alfa-2a may be substituted for other interferon preparations. Schiller M, et al. J Eur Acad Dermatol Venerol 2017;31:1841-1847.

<sup>v</sup> ISRT to include lymph node(s) ± primary skin lesions.

<sup>w</sup> Mycosis fungoides can develop over time; continue to conduct thorough skin exam during follow-up.

<sup>x</sup> Patients with a clinical benefit and/or those with disease responding to primary treatment should be considered for maintenance or tapering of regimens to optimize response duration. Relapsed disease often responds well to the same treatment. Partial response should be treated with other primary treatment options not received before to improve response before moving onto treatment for refractory disease. Patients with disease relapse or persistent disease after initial primary treatment may be candidates for clinical trials.

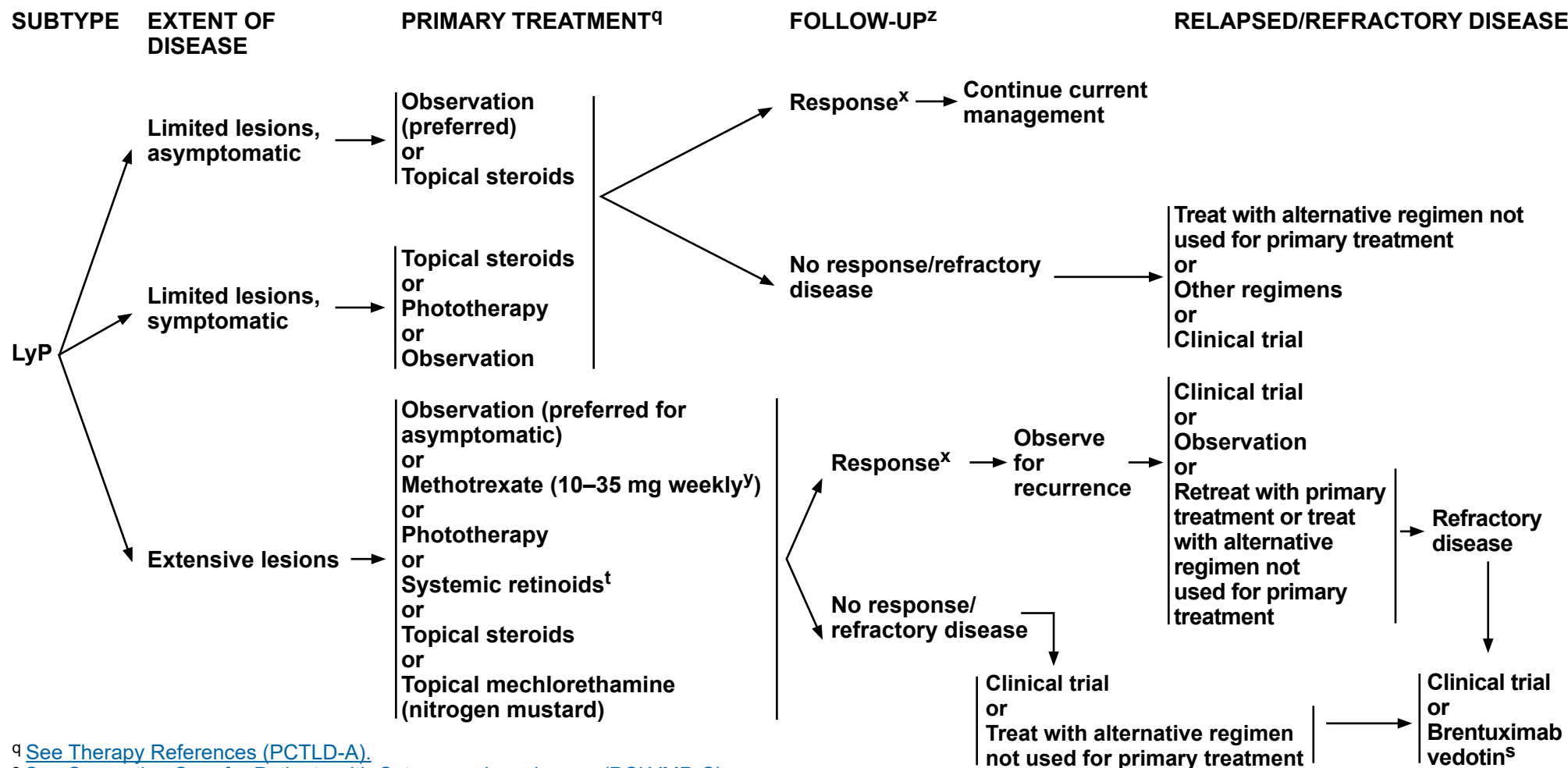
**Note:** All recommendations are category 2A unless otherwise indicated.

**Clinical Trials:** NCCN believes that the best management of any patient with cancer is in a clinical trial. Participation in clinical trials is especially encouraged.



# NCCN Guidelines Version 2.2021

## Primary Cutaneous CD30+ T-Cell Lymphoproliferative Disorders

<sup>q</sup> See Therapy References (PCTLD-A).<sup>s</sup> See Supportive Care for Patients with Cutaneous Lymphomas (PCLYMP-C).<sup>t</sup> Limited data from case reports (eg, bexarotene).<sup>x</sup> Patients with a clinical benefit and/or those with disease responding to primary treatment should be considered for maintenance or tapering of regimens to optimize response duration. Relapsed disease often responds well to the same treatment. Partial response should be treated with the other primary treatment options not received before to improve response before moving onto treatment for refractory disease. Patients with disease relapse or persistent disease after initial primary treatment may be candidates for clinical trials.<sup>y</sup> Kempf W, et al. Blood 2011;118:4024-4035.<sup>z</sup> Life-long follow-up is warranted due to high risk for second lymphoid malignancies; continue to conduct thorough skin exam during follow-up.**Note: All recommendations are category 2A unless otherwise indicated.****Clinical Trials: NCCN believes that the best management of any patient with cancer is in a clinical trial. Participation in clinical trials is especially encouraged.**



# NCCN Guidelines Version 2.2021

## Primary Cutaneous CD30+ T-Cell Lymphoproliferative Disorders

### THERAPY REFERENCES

#### Skin-Directed Therapies

##### **Topical steroids**

Paul MA, Krowchuk DP, Hitchcock MG, et al. Lymphomatoid papulosis: successful weekly pulse superpotent topical corticosteroid therapy in three pediatric patients. *Pediatr Dermatol* 1996;13:501-506.

##### **Phototherapy**

Wantzin GL, Thomsen K. PUVA-treatment in lymphomatoid papulosis. *Br J Dermatol* 1982;107:687-690.

##### **Topical nitrogen mustard**

Vonderheid EC, Tan ET, Kantor AF, et al. Long-term efficacy, curative potential, and carcinogenicity of topical mechloethamine chemotherapy in cutaneous T cell lymphoma. *J Am Acad Dermatol* 1989;20:416-428.

##### **Radiation therapy**

Million L, Yi EJ, Wu F, et al. Radiation therapy for primary cutaneous anaplastic large cell lymphoma: An International Lymphoma Radiation Oncology Group Multiinstitutional Experience. *Int J Radiat Oncol Biol Phys* 2018;95:1454-1459.

Specht L, Dabaja B, Illidge T, et al. Modern radiation therapy for primary cutaneous lymphomas: field and dose guidelines from the International Lymphoma Radiation Oncology Group. *Int J Radiat Oncol Biol Phys* 2015;92:32-39.

Yu JB, McNiff JM, Lund MW, et al. Treatment of primary cutaneous CD30+ anaplastic large cell lymphoma with radiation therapy. *Int J Radiat Oncol Biol Phys* 2008;70:1542-1545.

#### Systemic Therapies

##### **Brentuximab vedotin**

Duvic M, Tetzlaff MT, Gangar P, et al. Results of a phase II trial of brentuximab vedotin for CD30+ cutaneous T-cell lymphoma and lymphomatoid papulosis. *J Clin Oncol* 2015; 33:3759-65.

Broccoli A, Derenzini E, Pellegrini C, et al. Complete response of relapsed systemic and cutaneous anaplastic large cell lymphoma using brentuximab vedotin: 2 case reports. *Clin Lymphoma Myeloma Leuk* 2013;13:493-495.

Mody K, Wallace JS, Stearns DM, et al. CD30+ cutaneous T cell lymphoma and response to brentuximab vedotin: 2 illustrative cases. *Clin Lymphoma Myeloma Leuk* 2014;13:319-323.

Desai A, Telang GH, Olszewski AJ. Remission of primary cutaneous anaplastic large cell lymphoma after a brief course of brentuximab vedotin. *Ann Hematol* 2013;92:567-568.

##### **Brentuximab vedotin + CHP (cyclophosphamide, doxorubicin, and prednisone)**

Horwitz S, O'Connor OA, Pro B, et al. Brentuximab vedotin with chemotherapy for CD30-positive peripheral T-cell lymphoma (ECHELON-2): a global, double-blind, randomised, phase 3 trial. *Lancet*. 2019;393(10168):229-240.

##### **Interferons**

Proctor SJ, Jackson GH, Lennard AL, et al. Lymphomatoid papulosis: response to treatment with recombinant interferon alfa-2b. *J Clin Oncol* 1992;10:170.

Schmuck M, Topar G, Illersperger B, et al. Therapeutic use of interferon-alpha for lymphomatoid papulosis. *Cancer* 2000;89:1603-1610.

##### **Methotrexate**

Everett MA. Treatment of lymphomatoid papulosis with methotrexate. *Br J Dermatol* 1984;111:631.

Vonderheid EC, Sajjadian A, Kaden ME. Methotrexate is effective for lymphomatoid papulosis and other primary cutaneous CD30+ lymphoproliferative disorders. *J Am Acad Dermatol* 1996;34:470-481.

Fujita H, Nagatani T, Miyazawa M et al. Primary cutaneous anaplastic large cell lymphoma successfully treated with low-dose methotrexate. *Eur J Dermatol* 2008;18:360-361.

##### **Pralatrexate**

Horwitz SM, Kim YH, Foss F, et al. Identification of an active, well-tolerated dose of pralatrexate in patients with relapsed or refractory cutaneous T cell lymphoma. *Blood* 2012;119:4115-4122.

##### **Systemic retinoids**

Nakamura S, Hashimoto Y, Nishi K, et al. Primary cutaneous CD30+ lymphoproliferative disorder successfully treated with etretinate. *Eur J Dermatol* 2012;22:709-710.

Krathen RA, Ward S, Duvic M. Bexarotene is a new treatment option for lymphomatoid papulosis. *Dermatology* 2003;206:142-147.

Wyss M, Dummer R, Dommann SN, et al. Lymphomatoid papulosis: treatment with recombinant interferon alfa-2a and etretinate. *Dermatology* 1995;190:288-291.

Sheehy JM, Catherwood M, Pettengeil R, et al. Sustained response of primary cutaneous CD30+ anaplastic large cell lymphoma to bexarotene and photopheresis. *Leuk Lymphoma* 2009;50:1389-1391.

**Note:** All recommendations are category 2A unless otherwise indicated.

**Clinical Trials:** NCCN believes that the best management of any patient with cancer is in a clinical trial. Participation in clinical trials is especially encouraged.



### PRINCIPLES OF RADIATION THERAPY<sup>a</sup>

#### General Principles:

- The general intent of RT is to treat the evident skin disease with adequate margin both circumferentially and in depth.

#### Target Volumes:

- Involved-site radiation therapy (ISRT) for cutaneous lesions:
  - ▶ ISRT is recommended as the appropriate field for treating primary cutaneous lymphomas.
  - ▶ Planning to define the clinical target volume (CTV) may often only require a careful physical exam. However, when the depth of disease is not evident or when disease extends around curved surfaces, treatment planning may be facilitated by ultrasound imaging or CT-based simulation and planning. Incorporating other modern imaging like PET and MRI may enhance treatment volume determination in some cases.
  - ▶ ISRT targets the site of skin involvement. The volume encompasses the clinically evident disease with adequate margins.
  - ▶ The visible or palpable disease defines the gross tumor volume (GTV) and provides the basis for determining the CTV. If using CT-based planning, delineating tumor boundary with wire for CT simulation will guide treatment volumes. Concerns for questionable subclinical disease and uncertainties in original imaging accuracy or localization will lead to expansion of the CTV and are determined individually using clinical judgment but generally include a margin of 1–2 cm both circumferentially and in depth. The CTV need not be expanded into intact bone.
  - ▶ The planning target volume (PTV) is an additional expansion of the CTV that accounts only for setup variations (see ICRU definitions).
  - ▶ The treatment plan is designed using conventional or 3-D conformal techniques using clinical treatment planning considerations of coverage and dose reductions for organs at risk (OARs).
- ISRT for nodal disease:
  - ▶ [See Principles of Radiation Therapy for T-Cell Lymphomas](#) (Target Volumes: ISRT for nodal disease).
  - ▶ [See Principles of Radiation Therapy for B-Cell Lymphomas](#) (Target Volumes: ISRT for nodal disease).

[Continued](#)

<sup>a</sup>See references on [PCLYM-A 3 of 3](#).

**Note:** All recommendations are category 2A unless otherwise indicated.

**Clinical Trials:** NCCN believes that the best management of any patient with cancer is in a clinical trial. Participation in clinical trials is especially encouraged.





### PRINCIPLES OF RADIATION THERAPY<sup>a</sup>

#### General Dose Guidelines: (RT in conventional fraction sizes)

##### • PCMZL and PCFCL:

- ▶ Optimal initial management for solitary/regional disease is with 24–30 Gy external beam radiation therapy (EBRT).
  - ◊ Surface margins beyond area of clinically evident disease will vary depending on lesion size and body site and must take into account dosimetry of the beam being used. Surface margins of 1.0–1.5 cm are generally adequate.
  - ◊ Margins in depth should include the volume at risk for involvement.
  - ◊ Generally, treatment with 6–9 MeV electrons (with surface bolus) provides an adequate depth of treatment. Alternatively, low-energy x-rays (~100 Kv) may be used.
  - ◊ Doses as low as 4 Gy are used occasionally, but data are limited regarding response and duration.
- ▶ RT for relapsed disease: 4 Gy EBRT may be adequate.

##### • MF/SS

- ▶ Treatment of individual plaques or tumors
  - ◊ Optimal management for individual plaque and tumor lesions is with EBRT, 8–12 Gy; 8 Gy may be given in 1–2 fractions.
  - ◊ For unilesional MF, 24–30 Gy.
  - ◊ Surface margins beyond area of clinically evident disease will vary depending on lesion size and body site and must take into account dosimetry of the beam being used. Surface margins of 1.0–1.5 cm are generally adequate.
  - ◊ Margins in depth should include the volume at risk for involvement.
  - ◊ Generally, treatment with 6–9 MeV electrons (with surface bolus) provides an adequate depth of treatment. Alternatively, low-energy x-rays (~100 Kv) may be used.
  - ◊ For certain body surfaces, higher energy photon fields and opposed-field treatment (with bolus) may be required.
- ▶ Total skin electron beam therapy (TSEBT)
  - ◊ A variety of techniques may be utilized to cover the entire cutaneous surface. Patients are generally treated in the standing position on a rotating platform or with multiple body positions to ensure total skin coverage.
  - ◊ The dose range is 12–36 Gy, generally 4–6 Gy per week. The advantage of lower total dose includes fewer short-term complications and better ability to re-treat for relapsed disease.
  - ◊ “Shadowed” areas may need to be supplemented with individual electron fields.
  - ◊ Individual tumors may be boosted with doses of 4–12 Gy.
  - ◊ For patients with recalcitrant sites after generalized skin treatment, additional local treatment may be needed.

##### • Primary cutaneous ALCL:

- ▶ RT for curative treatment: 24–36 Gy
- ▶ Palliative RT: 2 Gy x 2
- ▶ Doses as low as 6 Gy are used occasionally, but data are limited regarding response and duration.

#### Treatment Modalities:

- Treatment with photons or electrons may all be appropriate, depending on clinical circumstances.

<sup>a</sup> See references on [PCLYM-A 3 of 3](#).

**Note:** All recommendations are category 2A unless otherwise indicated.

**Clinical Trials:** NCCN believes that the best management of any patient with cancer is in a clinical trial. Participation in clinical trials is especially encouraged.





### PRINCIPLES OF RADIATION THERAPY REFERENCES

Hoppe RT, Harrison C, Tavallaee M, et al. Low-dose total skin electron beam therapy as an effective modality to reduce disease burden in patients with mycosis fungoides: results of a pooled analysis from 3 phase-II clinical trials. *J Am Acad Dermatol* 2015;72:286-292.

Million L, Yi EJ, Wu F, et al. Radiation therapy for primary cutaneous anaplastic large cell lymphoma: An International Lymphoma Radiation Oncology Group Multiinstitutional Experience. *Int J Radiat Oncol Biol Phys* 2018;95:1454-1459.

Neelis KJ, Schimmel EC, Vermeer MH, et al. Low-dose palliative radiotherapy for cutaneous B- and T-cell lymphomas. *Int J Radiat Oncol Biol Phys* 2009;74:154-158.

Specht L, Dabaja B, Illidge T, et al. Modern radiation therapy for primary cutaneous lymphomas: field and dose guidelines from the International Lymphoma Radiation Oncology Group. *Int J Radiat Oncol Biol Phys* 2015;92:32-39.

Thomas TO, Agrawal P, Guitart J, et al. Outcome of patients treated with a single-fraction dose of palliative radiation for cutaneous T-cell lymphoma. *Int J Radiat Oncol Biol Phys* 2013;85:747-753.

**Note:** All recommendations are category 2A unless otherwise indicated.

**Clinical Trials:** NCCN believes that the best management of any patient with cancer is in a clinical trial. Participation in clinical trials is especially encouraged.



# NCCN Guidelines Version 2.2021

## Primary Cutaneous Lymphomas

### PRINCIPLES OF MOLECULAR ANALYSIS IN CUTANEOUS LYMPHOMAS<sup>a</sup>

- Genetic testing, including high-throughput sequencing (HTS), array-based comparative genomic hybridization (CGH), next-generation sequencing (NGS), karyotype, or FISH to detect somatic mutations or genetic abnormalities are often informative and in some cases essential for an accurate and precise diagnostic and prognostic assessment of T-cell lymphomas.

#### T-Cell Antigen Receptor (TCR) Gene Rearrangements

- TCR gene rearrangement testing is recommended to support a diagnosis of T-cell lymphoma.
- Diseases:
  - PTCLs; MF/SS; primary cutaneous CD30+ T-cell LPDs; T-cell large granular lymphocytic (T-LGL) leukemia; T-cell prolymphocytic leukemia (T-PLL); extranodal NK/T-cell lymphoma, nasal type; and hepatosplenic gamma-delta T-cell lymphoma
- Description:
  - TCR gene rearrangement is indicative of T-cell clonal expansion. The test targets the gamma and/or beta TCR genes using polymerase chain reaction (PCR) methods with capillary or gel electrophoresis detection methods. Alternatively, HTS methods are increasingly utilized. HTS methods are more sensitive, precise, and capable of providing a unique sequence of the T-cell clone, which allows for comparison and confirmation of disease evolution and monitoring during remission. Clonal T-cell expansions can also be detected using V beta families in blood or tissue with flow cytometry methods.
- Diagnostic value:
  - Clonal TCR gene rearrangements without cytologic histopathologic and immunophenotypic evidence of abnormal T-cell population does not constitute a diagnosis of T-cell lymphoma since it can be identified in patients with non-malignant conditions. Conversely, a negative result does not exclude the diagnosis of T-cell lymphoma, which occasionally may fail TCR amplification. Nonetheless, it often provides essential information and increased precision for many of these complex diagnoses.
- Prognostic value:
  - Identification of clonal TCR gene rearrangement has no definitive established prognostic value; however, it could be helpful when used to determine clinical staging or assess relapsed or residual disease.

#### ALK Gene Rearrangement

- A subset of CD30-positive ALCLs expresses anaplastic lymphoma kinase (ALK) by immunohistochemistry. ALK expression is often associated with t(2;5)(p23;q35), leading to the fusion of nucleophosmin (NPM1) to ALK and resulting in a chimeric protein.
- Detection:
  - FISH using probes to ALK (2p23) or mRNA sequencing by HTS technologies
  - Targeted mRNA sequencing
- Diagnostic value:
  - The present WHO classification of ALCLs includes two entities distinguishing ALK-positive and ALK-negative variants.
- Prognostic value:
  - Systemic ALK-positive ALCL with t(2,5) and ALK-negative ALCL with DUSP22 rearrangement (to a lesser extent) have been associated with a favorable prognosis. ALK inhibition can be an effective therapeutic strategy.

<sup>a</sup> See References on PCLYM-B 3 of 3.

Note: All recommendations are category 2A unless otherwise indicated.

Clinical Trials: NCCN believes that the best management of any patient with cancer is in a clinical trial. Participation in clinical trials is especially encouraged.

[Continued](#)



### PRINCIPLES OF MOLECULAR ANALYSIS IN CUTANEOUS LYMPHOMAS<sup>a</sup>

#### ***DUSP22-IRF4* Gene Rearrangement**

- Testing for *DUSP22* rearrangement is considered if CD30-positive ALCL, ALK negative is diagnosed, and considered useful under certain circumstances for the diagnosis of primary cutaneous CD30+ T-cell LPDs.
- Diseases:
  - PTCLs, primary cutaneous CD30+ T-cell LPDs
- Description:
  - *DUSP22* (dual-specificity phosphatase 22) is a tyrosine/threonine/serine phosphatase that may function as a tumor suppressor. *DUSP22* inactivation contributes to the development of PTCLs.
- Detection:
  - FISH using probes to *DUSP22-IRF4* gene region at 6p25.3
- Diagnostic value:
  - *DUSP22* rearrangements are associated with a newly recognized variant of ALK-negative ALCL and a newly reported subtype of lymphomatoid papulosis.
- Prognostic value:
  - ALCL, ALK negative with *DUSP22* rearrangement has preliminarily been associated with a favorable prognosis; however, the impact of this on choice of therapy is not currently known.

#### ***TP63* Rearrangement**

- *TP63* gene rearrangements encoding p63 fusion proteins define a subset of ALK-negative ALCL cases and are associated with aggressive course in systemic ALCL.
- Detection:
  - FISH using probes to *TP63* (3q28) and *TBL1XR1/TP63*
  - Targeted mRNA sequencing
- Disease:
  - ALK-negative ALCL
- Diagnostic value:
  - To identify ALK-negative ALCL cases associated with aggressive course

<sup>a</sup> [See References on PCLYM-B 3 of 3.](#)

**Note:** All recommendations are category 2A unless otherwise indicated.

**Clinical Trials:** NCCN believes that the best management of any patient with cancer is in a clinical trial. Participation in clinical trials is especially encouraged.



### PRINCIPLES OF MOLECULAR ANALYSIS IN CUTANEOUS LYMPHOMAS

#### REFERENCES

Chiarle R, Voena C, Ambrogio C, Piva R, Inghirami G. The anaplastic lymphoma kinase in the pathogenesis of cancer. *Nat Rev Cancer* 2008;8:11-23.

De Schouwer P, Dyer M, Brito-Babapulle V, et al. T-cell prolymphocytic leukemia: antigen receptor gene rearrangement and a novel mode of MTCP1-B1 activation. *Br J Haematol* 2000;110:831-838.

Hu Z, Medeiros L, Fang L, et al. Prognostic significance of cytogenetic abnormalities in T-cell prolymphocytic leukemia. *Am J Hematol* 2017;92:441-447.

Morris SW, Kirstein M, Valentine M, et al. Fusion of a kinase gene, ALK, to a nucleolar protein gene, NPM, in non-Hodgkin's Lymphoma. *Science* 1994;263:1281-1284.

Odejide O, Weigert O, Lane A, et al. A targeted mutational landscape of angioimmunoblastic T-cell lymphoma. *Blood* 2014;123:1293-1296.

Pedersen M, Hamilton-Dutoit S, Bendix K, et al. *DUSP22* and *TP63* rearrangements predict outcome of ALK-negative anaplastic large cell lymphoma: a Danish cohort study. *Blood* 2017;130:554-557.

Wada D, Law M, Hsi E, et al. Specificity of IRF4 translocations for primary cutaneous anaplastic large cell lymphoma: a multicenter study of 204 skin biopsies. *Mod Pathol* 2011;24:596-605.

**Note:** All recommendations are category 2A unless otherwise indicated.

**Clinical Trials:** NCCN believes that the best management of any patient with cancer is in a clinical trial. Participation in clinical trials is especially encouraged.



# NCCN Guidelines Version 2.2021

## Primary Cutaneous Lymphomas

### SUPPORTIVE CARE FOR PATIENTS WITH CUTANEOUS LYMPHOMAS

For other immunosuppressive situations, [see NCCN Guidelines for Prevention and Treatment of Cancer-Related Infections](#).

#### Monoclonal Antibody Therapy and Viral Reactivation

- **Brentuximab vedotin (anti-CD30 antibody-drug conjugate)**
  - **Progressive multifocal leukoencephalopathy (PML):**
    - ◊ Caused by reactivation of the JC virus (JCV) and is usually fatal.
    - ◊ Diagnosis made by PCR of cerebrospinal fluid (CSF) and in some cases brain biopsy.
    - ◊ Clinical indications may include changes in behavior such as confusion, dizziness or loss of balance, difficulty talking or walking, and vision problems.
    - ◊ No known effective treatment.
- **Alemtuzumab (anti-CD52 antibody therapy)**
  - **Cytomegalovirus (CMV) reactivation:**
    - ◊ The current appropriate management is controversial; some NCCN Member Institutions use ganciclovir (PO or IV) preemptively if viremia is present, others only if viral load is rising.
    - ◊ Herpes simplex virus (HSV) prophylaxis with acyclovir or equivalent.
    - ◊ PJP prophylaxis with sulfamethoxazole/trimethoprim or equivalent.
    - ◊ Consider antifungal prophylaxis.
    - ◊ CMV viremia should be measured by quantitative PCR at least every 2 to 3 weeks.
    - ◊ Consultation with an infectious disease expert may be necessary. [See NCCN Guidelines for Prevention and Treatment of Cancer-Related Infections](#).

#### Mogamulizumab and Graft-Versus-Host Disease (GVHD)

- A retrospective study showed a particularly high risk of developing GVHD in patients proceeding to allogeneic HCT within 50 days of mogamulizumab (Fuji S, et al. J Clin Oncol 2016;34:3426-3433).

#### Prevention of Pralatrexate-Induced Mucositis<sup>a,b,c</sup>

- **Vitamin B12 (cyanocobalamin)** at a dose of 1,000 mcg intramuscular to be started no more than 10 weeks prior to starting therapy with pralatrexate and then every 8 to 10 weeks.
- **Oral folic acid** 1 to 1.25 mg daily to be started within 10 days of starting therapy and continuing for 30 days after the last dose of pralatrexate.
- Consider use of oral leucovorin 25 mg three times daily for two consecutive days (total of 6 doses), starting 24 hours after each dose of pralatrexate.

<sup>a</sup> Mould DR, Sweeney K, Duffull SB, et al. A population pharmacokinetic and pharmacodynamic evaluation of pralatrexate in patients with relapsed or refractory non-Hodgkin's or Hodgkin's lymphoma. Clin Pharmacol Ther 2009;86:190-196.

<sup>b</sup> Shustov AR, Shinohara MM, Dakhil SR, et al. Management of mucositis with the use of leucovorin as adjunct to pralatrexate in treatment of peripheral T-cell lymphomas (PTCL) – Results from a prospective multicenter phase 2 clinical trial. Blood 2018;132:2910.

<sup>c</sup> Koch E, Story SK, Geskin LJ. Preemptive leucovorin administration minimizes pralatrexate toxicity without sacrificing efficacy. Leuk Lymphoma 2013;54:2448-2451.

**Note:** All recommendations are category 2A unless otherwise indicated.

**Clinical Trials:** NCCN believes that the best management of any patient with cancer is in a clinical trial. Participation in clinical trials is especially encouraged.



## Classification

### WHO-EORTC Classification for Primary Cutaneous Lymphomas (2018)

#### *Cutaneous T-Cell Lymphomas*

- Mycosis fungoides
  - Folliculotropic MF
  - Pagetoid reticulosis
  - Granulomatous slack skin
- Sézary syndrome
- Adult T-cell leukemia/lymphoma
- Primary cutaneous CD30+ T-cell lymphoproliferative disorders
  - Cutaneous anaplastic large cell lymphoma
  - Lymphomatoid papulosis
- Subcutaneous panniculitis-like T-cell lymphoma
- Extranodal NK/T-cell lymphoma, nasal type
- Chronic active EBV infection
- Primary cutaneous peripheral T-cell lymphoma, rare subtypes
  - Primary cutaneous gamma-delta T-cell lymphoma
  - CD8+ AECTCL (primary cutaneous aggressive epidermotropic CD8+ cytotoxic T-cell lymphoma) (provisional)
  - Primary cutaneous CD4+ small/medium T-cell lymphoproliferative disorder (provisional)
  - Primary cutaneous acral CD8+ T-cell lymphoma (provisional)
- Primary cutaneous peripheral T-cell lymphoma, NOS

#### *Cutaneous B-Cell Lymphomas*

- Primary cutaneous marginal zone lymphoma
- Primary cutaneous follicle center lymphoma
- Primary cutaneous DLBCL, leg type
- EBV+ mucocutaneous ulcer (provisional)
- Intravascular large B-cell lymphoma

With permission, Willemze R, Cerroni L, Kempf W, et al. The 2018 update of the WHO-EORTC classification for primary cutaneous lymphomas. *Blood* 2019;133:1703-1714.





# NCCN Guidelines Version 2.2021

## Primary Cutaneous Lymphomas

### NCCN Categories of Evidence and Consensus

<b>Category 1</b>	Based upon high-level evidence, there is uniform NCCN consensus that the intervention is appropriate.
<b>Category 2A</b>	Based upon lower-level evidence, there is uniform NCCN consensus that the intervention is appropriate.
<b>Category 2B</b>	Based upon lower-level evidence, there is NCCN consensus that the intervention is appropriate.
<b>Category 3</b>	Based upon any level of evidence, there is major NCCN disagreement that the intervention is appropriate.

All recommendations are category 2A unless otherwise indicated.

### NCCN Categories of Preference

<b>Preferred intervention</b>	Interventions that are based on superior efficacy, safety, and evidence; and, when appropriate, affordability.
<b>Other recommended intervention</b>	Other interventions that may be somewhat less efficacious, more toxic, or based on less mature data; or significantly less affordable for similar outcomes.
<b>Useful in certain circumstances</b>	Other interventions that may be used for selected patient populations (defined with recommendation).

All recommendations are considered appropriate.



National  
Comprehensive  
Cancer  
Network®

# NCCN Guidelines Version 2.2021

## Primary Cutaneous Lymphomas

### Discussion

This discussion corresponds to the NCCN Guidelines for Primary Cutaneous Lymphomas. Last updated: March 4, 2021.

### Table of Contents

Overview .....	2
Primary Cutaneous B-Cell Lymphomas.....	2
Mycosis Fungoides and Sézary Syndrome.....	14
Primary Cutaneous CD30+ T-Cell Lymphoproliferative Disorders.....	43



# NCCN Guidelines Version 2.2021

## Primary Cutaneous Lymphomas

### Overview

Primary cutaneous lymphomas (PCL) are a heterogeneous group of extranodal B-cell and T-cell non-Hodgkin lymphomas (NHL) originating in and usually confined to the skin.<sup>1,2</sup> In the SEER database population-based analysis of 3,884 cases of PCL diagnosed in the United States from 2001 to 2005, the incidence of cutaneous B-cell lymphomas (CBCL) and cutaneous T-cell lymphomas (CTCL) accounted for 29% and 71%, respectively.<sup>3</sup>

The WHO-EORTC classification for cutaneous lymphomas was first published in 2005 and was subsequently updated in 2018.<sup>1,2,4</sup> The most common subtypes of PCL that are covered in the NCCN Guidelines are listed below:

- Cutaneous B-Cell Lymphomas
  - Primary cutaneous marginal zone lymphoma (PCMZL);
  - Primary cutaneous follicle center lymphoma (PCFCL); and
  - Primary cutaneous diffuse large B-cell lymphoma, leg type (PCDLBCL, leg type)
- Cutaneous T-Cell Lymphomas
  - Mycosis fungoides (MF) and Sézary syndrome (SS)
  - Primary cutaneous CD30+ T-cell lymphoproliferative disorders (PCTLD)

### Primary Cutaneous B-Cell Lymphomas

Primary cutaneous B-cell lymphomas (PCBCL) are divided into three main types: PCMZL, PCFCL, and PCDLBCL, leg type.<sup>1,4</sup>

Gene expression profiling studies have shown that PCFCL has a germinal center B-cell (GCB) phenotype and PCDLBCL, leg type has an activated B-cell (ABC) phenotype.<sup>5,6</sup> In nodal DLBCL, the GCB phenotype is associated with a better prognosis than the ABC phenotype. Thus, a

germinal (or follicle) center phenotype and large cells in a skin lesion is not equivalent to DLBCL but is consistent with PCFCL with a GCB phenotype. Recent studies suggest that PCMZL can be divided into two subgroups based on the immunoglobulin (Ig) heavy chain usage, with the vast majority being CXCR3-negative and Ig class-switched subtype (IgG, IgA and IgE) and a small subset being CXCR3-positive and IgM-positive.<sup>7-10</sup> Emerging data suggest that Ig class-switched subtype may be categorized as a clonal chronic lymphoproliferative disorder due to its indolent disease course.<sup>10,11</sup>

PCFCL and PCMZL are generally indolent or slow growing. PCFCL is more prevalent in the scalp, face and the forehead, whereas the trunk and extremities are the most common sites for PCMZL. PCDLBCL, leg type is usually aggressive, associated with a generally poorer prognosis (mainly due to the higher frequency of extracutaneous relapses), and most commonly arises on the leg although it can arise at other sites.<sup>12,13</sup>

In retrospective series, PCFCL is the most common subtype diagnosed in 57% of patients followed by PCMZL (24%–31%) and PCDLBCL, leg type (11%–19%).<sup>12,13</sup> In the Italian series of 467 patients with PCBCL, extracutaneous involvement eventually developed in 6% of patients with PCMZL, 11% with PCFCL, and 17% with PCDLBCL, leg type.<sup>12</sup> The 5-year overall survival (OS) rate was significantly higher for patients with PCMZL and PCFCL than for patients with PCDLBCL, leg type (97%, 96%, and 73%, respectively;  $P < .0001$ ).<sup>12</sup> In patients with PCMZL and PCFCL, the disease-free survival (DFS) and OS rates were significantly higher for patients with single lesions compared with those with regional or disseminated lesions (5-year DFS, 62% vs. 44%; 5-year OS, 97% vs. 85%), whereas the difference in outcomes between single and regional or disseminated lesions was not significant in patients with PCDLBCL, leg type (5-year DFS rate 55% vs. 44%; 5-year OS rate 79% vs. 67% for single and regional or disseminated lesions, respectively).<sup>12</sup> In the report



# NCCN Guidelines Version 2.2021

## Primary Cutaneous Lymphomas

from the Dutch Cutaneous Lymphoma Registry that included 300 patients with PCBCL, the incidence of extracutaneous relapse was 47% among patients with PCDLBCL, leg type compared to 11% and 9%, respectively, for patients with PCFCL and PCMZL.<sup>13</sup> The 5-year disease-specific survival rates in this series were 95%, 98%, and 50%, respectively.

In addition to the aforementioned subtypes, PCDLBCL, not otherwise specified (PCDLBCL-NOS) with clinicopathologic features intermediate between PCFCL and PCDLBCL, leg type has also been described.<sup>14,15</sup> In the 2005 WHO-EORTC classification, the term PCDLBCL, other was introduced to include rare cases of CBCL that could not be classified as either PCDLBCL, leg type or PCFCL.<sup>4</sup> The revised 2018 WHO-EORTC classification does not contain this separate category of PCDLBCL, other and rare cases that cannot be classified as either PCDLBCL, leg type or PCFCL should be given a diagnosis of PCDLBCL-NOS.<sup>1</sup>

### Literature Search Criteria and Guidelines Update Methodology

Prior to the update of this version of the NCCN Guidelines® for Primary Cutaneous Lymphomas, a literature search was performed to obtain key literature on PCBCL published since the previous Guidelines update, using the following search terms: cutaneous diffuse large B-cell lymphoma, cutaneous follicle center lymphoma, and cutaneous marginal zone lymphoma. The PubMed database was chosen as it remains the most widely used resource for medical literature and indexes peer-reviewed biomedical literature.<sup>16</sup>

The search results were narrowed by selecting studies in humans published in English. Results were confined to the following article types: Clinical Trial, Phase II; Clinical Trial, Phase III; Clinical Trial, Phase IV; Guideline; Randomized Controlled Trial; Meta-Analysis; Systematic Reviews; and Validation Studies.

The data from key PubMed articles deemed as relevant to these guidelines have been included in this version of the Discussion section. Recommendations for which high-level evidence is lacking are based on the panel's review of lower-level evidence and expert opinion.

The complete details of the Development and Update of the NCCN Guidelines are available at [www.NCCN.org](http://www.NCCN.org).

### Diagnosis

While the diagnosis of PCMZL is generally straightforward and reproducible among pathologists, it is more difficult to distinguish between PCFCL and PCDLBCL, leg type, partly because the cell size (large vs. small) is not a defining feature as it is in nodal B-cell lymphomas.

PCMZL are always negative for BCL6 and CD10, but are often BCL2-positive.<sup>17</sup> PCFCL is consistently BCL6-positive, whereas CD10 and BCL2 are expressed in only a few cases with a follicular growth pattern and the detection of *BCL2* rearrangement is associated with extracutaneous spread.<sup>18-20</sup>

PCDLBCL, leg type tumors express CD20, IRF4/MUM1, FOXP1, and BCL2; many cases express BCL6 and lack expression of CD10.<sup>5,6,13,21-23</sup> PCDLBCL, leg type also has a high incidence of *MYC* rearrangements and *MYC* rearrangements are not detected in PCFCL.<sup>24</sup> In addition, PCFCL is usually IRF4/MUM1-negative while PCDLBCL, leg type is usually IRF4/MUM1-positive and shows strong expression of FOXP1.<sup>22,23</sup> Assessment of FOXP1 expression is helpful to distinguish PCDLBCL, leg type from PCFCL since all cases of PCFCL are FOXP1-negative.<sup>23</sup> Modified Hans immunohistochemical algorithm including CD10 and MUM1 has also been shown to be useful to distinguish PCFCL from PCDLBCL, leg type with optimal diagnostic value without the need for BCL-6.<sup>6</sup>



# NCCN Guidelines Version 2.2021

## Primary Cutaneous Lymphomas

The diagnosis of PCBCL is established by adequate biopsy of skin lesions. Incisional, excisional, or punch biopsy is preferred to shave biopsy, as PCBCL have primarily dermal infiltrates, often deep, which are less well-sampled and can be missed by a shave biopsy. Review of the slides by a pathologist with expertise in the diagnosis of PCBCL is recommended. Adequate immunophenotyping of the biopsy sample is essential for the diagnosis of the exact subtype of PCBCL. In addition, immunophenotyping is also useful to rule out cutaneous lymphoid hyperplasia (also known as pseudolymphoma or lymphocytoma cutis)<sup>25-27</sup> and in the differential diagnosis of intravascular large B-cell lymphoma, which often manifests in skin and is associated with a poor prognosis.<sup>28</sup>

The initial immunohistochemistry (IHC) panel should include CD20, CD3, CD5, CD10, BCL2, BCL6, and IRF4/MUM1. Under certain circumstances, evaluation of additional immunohistochemical markers such as Ki-67, CD43, CD21, CD23, cyclin D1, and kappa/lambda may be useful to further establish the lymphoma subtype. Additionally, assessment of surface IgM IgD and FOXP1 expression may also be helpful in distinguishing PCDLBCL, leg type from PCFCL.<sup>22,23,29</sup> Epstein-Barr virus (EBV)-positive mucocutaneous ulcer is also included as a new provisional entity in the updated WHO-EORTC classification and IHC for EBV-encoded nuclear RNA (EBER) may be useful under selected circumstances.<sup>1</sup>

A high prevalence of *MYD88* L265P mutation has been reported in patients with PCDLBCL, leg type and is associated with inferior clinical outcomes.<sup>6,30</sup> In a retrospective analysis of 61 patients (58 patients with interpretable results) diagnosed with PCDLBCL, leg type, *MYD88* L265P mutation was detected in 59% of patients.<sup>30</sup> It was also associated with shorter disease-specific survival and was an independent adverse prognostic factor for OS. The 3-year and 5-year disease-specific survival rates for those with *MYD88* L265P mutation were 66% and 60%, respectively, compared to 85% and 72%, respectively, for patients with the

wild-type allele. In the aforementioned report that evaluated the clinicopathologic and molecular characteristics of patients with PCFCL (25 patients) and PCDLBCL, leg type (32 patients), *MYD88* L265P mutation was detected only in patients with PCDLBCL, leg type (n = 22; 69%).<sup>6</sup> These findings suggest that determination of *MYD88* L265P mutation status could be helpful to further distinguish PCDLBCL, leg type from PCFCL.

The t(14;18) translocation on FISH analysis has been observed only in a small number of cases with PCFCL and the detection of a t(14;18) translocation suggests the presence of systemic follicular lymphoma (FL).<sup>20,31</sup> Cytogenetics or FISH to detect t(14;18) may be useful if systemic FL is suspected. The feasibility of flow cytometric immunophenotyping of skin biopsies for the assessment of B-cell clonality has been reported, although it has not been widely used.<sup>27</sup> If adequate biopsy material is available, *IGH* gene rearrangement studies or flow cytometry could be useful in determining B-cell clonality.

Mantle cell lymphoma (MCL) is not a primary cutaneous lymphoma and finding it in the skin requires a careful search for extracutaneous disease. Clinical presentation on the leg and blastoid cytology along with high proliferative index and expression of BCL2, IRF4/MUM1, and IgM would often represent MCL with skin involvement.<sup>32</sup> The use of cyclin D1 may be useful to differentiate PCMZL (negative for CD5 and cyclin D1) from MCL (positive for CD5 and cyclin D1).

### Workup

The absence of extracutaneous disease at diagnosis is part of the definition of primary CBCL. The initial workup is geared toward evaluating extent of disease on the skin and seeking extracutaneous disease.<sup>33</sup>

The initial workup should include a complete physical examination, a comprehensive skin examination, complete blood cell (CBC) count with





# NCCN Guidelines Version 2.2021

## Primary Cutaneous Lymphomas

differential, comprehensive metabolic panel and CT and/or PET/CT of the chest, abdomen, and pelvis. Peripheral blood flow cytometry will be useful in selected cases, if CBC demonstrates lymphocytosis. Imaging is effective in identifying systemic involvement in patients with indolent CBCL.<sup>34</sup> However, it can be omitted if clinically indicated in patients with low-grade indolent CBCL.<sup>35</sup> PET/CT may have higher sensitivity in the detection of both local and distant metastases than CT.<sup>36</sup> However, this is not validated and the higher rates of false-positive findings can create confusion.

Bone marrow biopsy is essential for PCDLBCL, leg type, since this is an aggressive lymphoma that will probably require systemic treatment; however, it appears to have a more limited value in PCFCL and PCMZL, and may be considered only in selected patients.<sup>33,35,37</sup> The International Society for Cutaneous Lymphomas (ISCL) and the EORTC Task Force recommend that bone marrow biopsy be obtained for cutaneous lymphomas with intermediate to aggressive behaviors and should be considered for cutaneous lymphomas with indolent behavior and when there is any evidence of extracutaneous disease, as indicated by other staging assessments (eg, radiographic evidence or serologic clues such as elevated monoclonal or polyclonal immunoglobulins).<sup>33</sup> Senff et al evaluated 275 patients with histologic features consistent with marginal zone lymphoma (MZL; n = 82) or follicle center lymphoma (FCL; n = 193) first presenting in the skin.<sup>37</sup> Bone marrow involvement was seen in about 11% of patients in the FCL group compared with 2% in the MZL group. Among patients with FCL, a positive bone marrow was associated with significantly worse prognosis compared with those with skin lesions only; the 5-year OS rate was 44% and 84%, respectively.<sup>37</sup> The guidelines recommend considering bone marrow biopsy for patients with unexplained cytopenias or if there is a clinical suspicion of PCDLBCL, leg type.

### Treatment Options

Involved-site radiation therapy (ISRT) is very effective when used as initial therapy as well as for cutaneous relapses in most patients with indolent PCBCL.<sup>38-42</sup>

In a retrospective study of 34 patients with PCBCL treated with RT, 5-year relapse-free survival (RFS) rates ranged from 62% to 73% for PCFCL and PCMZL but were only 33% for patients with PCDLBCL, leg type.<sup>39</sup> The 5-year OS rate was 100% for PCFCL and PCMZL but was 67% for PCDLBCL, leg type. Senff et al evaluated the outcome of 153 patients with PCBCL (25 with PCMZL; 101 with PCFCL; and 27 with PCDLBCL) who were initially treated with RT with a curative intent.<sup>40</sup> Overall, 45% of patients had single lesions while localized or disseminated lesions were seen in 43% and 12% of patients, respectively. Complete response (CR) was obtained in 151 of 153 patients (99%). Relapse rates for PCMZL, PCFCL, and PCDLBCL, leg type were 60%, 29%, and 64%, and the 5-year disease-specific survival rates were 95%, 97%, and 59%, respectively. The PCFCLs presenting on the legs also had a higher relapse rate (63%) and a lower 5-year disease-specific survival (44%) compared with PCFCLs occurring at other sites (25% and 99%, respectively).<sup>40</sup>

In another retrospective study of 42 patients with biopsy-proven PCFCL and PCMZL, RT resulted in CR in all patients.<sup>42</sup> The 10-year RFS and OS rates were 71% and 87%, respectively, for the entire cohort, after a median follow-up of 9.5 years. The 5-year RFS rate was higher for patients with trunk lesions and single lesions (89% and 84%, respectively) compared to those with extra-trunk lesions and multiple lesions (67% and 57%, respectively). Low-dose ISRT (4 Gy in two fractions) is an effective treatment option for palliation of symptoms in patients with persistent (initial) lesions or recurrent symptomatic disease.<sup>43</sup> The results of a more recent retrospective study also showed that RT ≤12





# NCCN Guidelines Version 2.2021

## Primary Cutaneous Lymphomas

Gy (4 Gy for relapsed disease) was equally effective as RT >12 Gy in patients with indolent PCBCL (42 patients; 16 patients had PCFCL).<sup>44</sup>

ISRT and excision were also associated with higher response rates compared to chemotherapy in patients with indolent histologies, but were generally used for those with more limited disease; therefore, a direct comparison cannot be made.<sup>12,45-47</sup> In a large retrospective analysis by the Italian Study Group for Cutaneous Lymphomas involving 467 patients with PCBCL, the CR rate and the 5- and 10-year OS rates for all patients with PCFCL and PCMZL who received first-line treatment (RT in 53%, with total dose of 35–45 Gy; chemotherapy in 25%, mainly with CHOP; surgery in 23%) were 92% to 95%, 96% to 97%, and 89% to 91%, respectively.<sup>12</sup> The relapse rate was 44% to 47% and extracutaneous spread was observed in 6% to 11% of patients. Relapse rate did not vary by the type of initial therapy. In patients with PCDLBCL, leg type, the CR rate and 5- and 10-year OS rates were 82%, 73%, and 47%, respectively. PCDLBCL, leg type was associated with higher relapse rates (55%) and higher incidences of extracutaneous spread (17%) — a higher relapse rate was confirmed both for patients with single or regional lesions treated with RT and for patients with disseminated cutaneous involvement treated with chemotherapy.<sup>12</sup> In a retrospective analysis of 137 patients with PCMZL, initial treatment with surgical excision, RT, or a combination of both resulted in a CR rate of 88% (93% for patients with solitary or localized disease and 71% for those with multifocal lesions).<sup>47</sup> Although there were no significant differences in the rate of recurrences between the treatment modalities, surgery alone was associated with more recurrences at the initial site.

Rituximab monotherapy (intravenous<sup>48-52</sup> and intralesional<sup>53-55</sup>) has been shown to be effective for PCMZL and PCFCL. Intravenous rituximab may be more effective for patients with multiple lesions that cannot be managed effectively with local therapy.<sup>48-52</sup> In a retrospective analysis of

15 patients with indolent PCBCL, rituximab resulted in an overall response rate (ORR) of 87% (60% CR). The ORR was 100% for patients with PCFCL and 60% for PCMZL. With a median follow-up of 36 months, the median duration of response was 24 months.<sup>51</sup> In another series of 16 patients with PCBCL, 14 patients (88%) achieved a CR with rituximab monotherapy; 35% of these patients with CR eventually relapsed between 6 and 37 months.<sup>52</sup> In an observational multicenter study conducted by the Spanish Working Group on Cutaneous Lymphoma (17 patients with PCMZL and 18 patients with PCFCL), intralesional rituximab induced CR and partial response (PR) in 71% and 23% of patients, respectively, with a median DFS of 114 weeks.<sup>53</sup> The response rates were similar among patients with PCMZL and PCFCL. In a small series that evaluated the efficacy of intravenous and intralesional rituximab in treatment of patients with PCMZL and PCFCL, although intralesional rituximab resulted in response rates similar to that of intravenous rituximab, within a 12-month follow-up period, relapses were more frequent among patients treated with intralesional rituximab.<sup>56</sup>

Chemotherapy is effective for multifocal skin lesions in patients with PCFCL or PCMZL.<sup>57-59</sup>

### Primary Cutaneous Marginal Zone Lymphoma And Primary Cutaneous Follicle Center Cell Lymphoma

Because there are no data from randomized clinical trials, the treatment recommendations included in the NCCN Guidelines are derived from the management practices of patients with PCBCL at NCCN Member Institutions based on the limited data from retrospective analyses and studies involving a small cohort of patients.

Local therapy (excision, ISRT, or skin-directed therapy) is suitable for PCFCL and PCMZL in patients with solitary/regional lesions (T1–T2). Several case reports have shown the effectiveness of skin-directed therapy (steroids, imiquimod, and nitrogen mustard or bexarotene gel) for



# NCCN Guidelines Version 2.2021

## Primary Cutaneous Lymphomas

patients with multifocal lesions.<sup>57,60-63</sup> Interlesional steroids have also been used in the management of PCFCL or PCMZL, although only limited data are available.<sup>45,64,65</sup> Systemic therapy (rituximab monotherapy<sup>45-49</sup> or combination chemoimmunotherapy<sup>54-56</sup>) is often more appropriate for those with generalized disease (skin only; T3).<sup>48-52,57-59</sup>

In a retrospective analysis that assessed the efficacy of various treatment modalities (55 patients; majority of patients had indolent PCBCL; 25 patients with PCMZL and 24 patients with PCFCL), the type of treatment modality (skin-directed vs. definitive RT with or without systemic therapy) did not affect the time to first recurrence among patients with T1 and T2/T3 lesions.<sup>66</sup> The rates of recurrence were higher for T2/T3 lesions compared to T1 lesions (58% and 31%, respectively). The time to first recurrence for T1 lesions was 33% and 29%, respectively, for patients with PCMZL and PCFCL; however, the difference was not significant. Among patients with T2/T3 lesions, there was a non-significant trend toward higher rate of recurrence for PCMZL than PCFCL (73% and 38%, respectively).

Additional imaging studies during the course of treatment are not needed after negative initial staging for systemic involvement and clinical follow-up without routine imaging may be appropriate for patients with PCMZL.<sup>34</sup> PET/CT (preferred) or CT with contrast may be repeated at the end of treatment for assessment of response and can be repeated if there is clinical suspicion of progressive disease. Extracutaneous disease should be managed according to FL as outlined in the NCCN Guidelines for B-Cell Lymphomas.

While PCMZL and PCFCL respond to initial therapy, disease relapse is common in the majority of patients with regional or generalized disease, regardless of type of initial treatment. However, relapses are generally confined to the skin in which case survival does not appear to be affected.

### ***Solitary or Regional Disease (T1–T2)***

#### ***Initial Treatment***

ISRT (24–30 Gy; alone or in combination with excision) or excision alone is recommended as the initial treatment.<sup>38-40,44,46,47,67</sup> Local ISRT is the preferred initial treatment. Observation is an option when RT or excision is neither desired nor feasible (eg, lesions on the scalp where hair loss is a major concern). Skin-directed therapy (steroids, imiquimod, or nitrogen mustard or bexarotene gel) or intralesional steroids may be considered for selected patients.

Observation is recommended for patients with disease responding to initial therapy, and those with refractory disease should be managed as described for generalized disease below.

#### ***Treatment for Relapsed or Progressive Disease***

Patients with regional relapse should be treated with an alternate initial treatment option and those with generalized disease relapse confined to the skin should receive treatment options recommended for generalized disease at presentation. Low-dose RT (4 Gy) may be adequate for relapsed or refractory disease.<sup>43,44</sup>

Patients with extracutaneous relapse or those with cutaneous relapse that is not responding to any of the initial treatment options should be managed according to the FL as outlined in the NCCN Guidelines for B-Cell Lymphomas.

### ***Generalized Disease (skin only; T3)***

#### ***Initial Treatment***

Observation, skin-directed therapy, local ISRT (24–30 Gy) for palliation of symptoms, and intralesional steroids or rituximab are included as treatment options. In patients with very extensive or symptomatic disease,



# NCCN Guidelines Version 2.2021

## Primary Cutaneous Lymphomas

other combination chemotherapy regimens recommended for FL may be used.<sup>57-59</sup>

Observation is recommended for patients with disease responding to initial therapy, and those with refractory disease should be treated with an alternate initial treatment option.

### *Treatment for Relapsed or Refractory Disease*

Patients with relapse localized to skin should be treated with an alternate initial treatment option.

Patients with extracutaneous relapse or those with cutaneous relapse that is not responding to any of the initial treatment options should be managed according to the FL as outlined in the NCCN Guidelines for B-Cell Lymphomas.

### **Primary Cutaneous Diffuse Large B-Cell Lymphoma, Leg Type**

RT alone is less often effective in patients with PCDLBCL. While these lesions do respond to RT, remissions are often short-lived and higher rates of dissemination to extracutaneous sites occur.

The potential utility of chemotherapy in combination with rituximab for the management of patients with PCDLBCL, leg type has been described in retrospectively analyses and case reports.<sup>68-72</sup> In a retrospective multicenter study from the French Study Group on 60 patients with PCDLBCL, leg type, patients treated with anthracycline-containing chemotherapy and rituximab had a more favorable short-term outcome, although no particular therapy (RT or multiagent chemotherapy with or without rituximab) was significantly associated with improved survival outcomes.<sup>68</sup> Among 12 patients treated with anthracycline-based chemotherapy with rituximab, the CR rate was 92% compared to 62% for patients who received other therapies. The 2-year OS rate for these two groups was 81% and 59%, respectively. In a more recent report from the

French study group (115 patients), the 3- and 5-year survival rates were 80% and 74%, respectively, for patients who received multiagent chemotherapy with rituximab compared to 48% and 38%, respectively, for patients who received less-intensive therapies.<sup>71</sup> A more recent retrospective analysis involving 21 patients with PCBCL treated in a single center also reported excellent outcomes with anthracycline-based chemotherapy, including R-CHOP or R-CVP irrespective of staging and pathologic subtype.<sup>72</sup> Eighteen of 21 patients received treatment for PCBCL (12 chemotherapy alone, 3 RT alone, and 3 chemotherapy and RT) and CR was observed in 17 patients.

PCDLBCL, leg type has a poorer prognosis than other types of PCBCL and is generally treated with more aggressive chemotherapy regimens used for systemic DLBCL as outlined in the NCCN Guidelines for B-Cell Lymphomas.



# NCCN Guidelines Version 2.2021

## Primary Cutaneous Lymphomas

### References

1. Elder DE, Massi D, Scolyer RA, Willemze R. WHO Classification of Skin Tumours. 4th edition. Lyon, France: IARC Press; 2018.
2. Willemze R, Cerroni L, Kempf W, et al. The 2018 update of the WHO-EORTC classification for primary cutaneous lymphomas. *Blood* 2019;133:1703-1714. Available at: <https://www.ncbi.nlm.nih.gov/pubmed/30635287>.
3. Bradford PT, Devesa SS, Anderson WF, Toro JR. Cutaneous lymphoma incidence patterns in the United States: a population-based study of 3884 cases. *Blood* 2009;113:5064-5073. Available at: <https://www.ncbi.nlm.nih.gov/pubmed/19279331>.
4. Willemze R, Jaffe ES, Burg G, et al. WHO-EORTC classification for cutaneous lymphomas. *Blood* 2005;105:3768-3785. Available at: <https://www.ncbi.nlm.nih.gov/pubmed/15692063>.
5. Hoefnagel JJ, Dijkman R, Basso K, et al. Distinct types of primary cutaneous large B-cell lymphoma identified by gene expression profiling. *Blood* 2005;105:3671-3678. Available at: <https://www.ncbi.nlm.nih.gov/pubmed/15308563>.
6. Menguy S, Beylot-Barry M, Parrens M, et al. Primary cutaneous large B-cell lymphomas: relevance of the 2017 World Health Organization classification: clinicopathological and molecular analyses of 64 cases. *Histopathology* 2019;74:1067-1080. Available at: <https://www.ncbi.nlm.nih.gov/pubmed/30715765>.
7. van Maldegem F, van Dijk R, Wormhoudt TA, et al. The majority of cutaneous marginal zone B-cell lymphomas expresses class-switched immunoglobulins and develops in a T-helper type 2 inflammatory environment. *Blood* 2008;112:3355-3361. Available at: <https://www.ncbi.nlm.nih.gov/pubmed/18687986>.
8. Edinger JT, Kant JA, Swerdlow SH. Cutaneous marginal zone lymphomas have distinctive features and include 2 subsets. *Am J Surg Pathol* 2010;34:1830-1841. Available at: <https://www.ncbi.nlm.nih.gov/pubmed/21107089>.
9. Kogame T, Takegami T, Sakai TR, et al. Immunohistochemical analysis of class-switched subtype of primary cutaneous marginal zone lymphoma in terms of inducible skin-associated lymphoid tissue. *J Eur Acad Dermatol Venereol* 2019;33:e401-e403. Available at: <https://www.ncbi.nlm.nih.gov/pubmed/31124191>.
10. Carlsen ED, Swerdlow SH, Cook JR, Gibson SE. Class-switched Primary Cutaneous Marginal Zone Lymphomas Are Frequently IgG4-positive and Have Features Distinct From IgM-positive Cases. *Am J Surg Pathol* 2019;43:1403-1412. Available at: <https://www.ncbi.nlm.nih.gov/pubmed/31464711>.
11. Gibson SE, Swerdlow SH. How I Diagnose Primary Cutaneous Marginal Zone Lymphoma. *Am J Clin Pathol* 2020;154:428-449. Available at: <https://www.ncbi.nlm.nih.gov/pubmed/32808967>.
12. Zinzani PL, Quaglino P, Pimpinelli N, et al. Prognostic factors in primary cutaneous B-cell lymphoma: the Italian Study Group for Cutaneous Lymphomas. *J Clin Oncol* 2006;24:1376-1382. Available at: <https://www.ncbi.nlm.nih.gov/pubmed/16492713>.
13. Senff NJ, Hoefnagel JJ, Jansen PM, et al. Reclassification of 300 primary cutaneous B-Cell lymphomas according to the new WHO-EORTC classification for cutaneous lymphomas: comparison with previous classifications and identification of prognostic markers. *J Clin Oncol* 2007;25:1581-1587. Available at: <https://www.ncbi.nlm.nih.gov/pubmed/17353548>.
14. Lucioni M, Berti E, Arcaini L, et al. Primary cutaneous B-cell lymphoma other than marginal zone: clinicopathologic analysis of 161 cases: Comparison with current classification and definition of prognostic markers. *Cancer Med* 2016;5:2740-2755. Available at: <https://www.ncbi.nlm.nih.gov/pubmed/27665744>.
15. Felcht M, Klemke CD, Nicolay JP, et al. Primary cutaneous diffuse large B-cell lymphoma, NOS and leg type: Clinical, morphologic and





# NCCN Guidelines Version 2.2021

## Primary Cutaneous Lymphomas

prognostic differences. *J Dtsch Dermatol Ges* 2019;17:275-285. Available at: <https://www.ncbi.nlm.nih.gov/pubmed/30851152>.

16. U.S. National Library of Medicine Key MEDLINE® Indicators Available at: [http://www.nlm.nih.gov/bsd/bsd\\_key.html](http://www.nlm.nih.gov/bsd/bsd_key.html).

17. Hoefnagel JJ, Vermeer MH, Jansen PM, et al. Bcl-2, Bcl-6 and CD10 expression in cutaneous B-cell lymphoma: further support for a follicle centre cell origin and differential diagnostic significance. *Br J Dermatol* 2003;149:1183-1191. Available at: <http://www.ncbi.nlm.nih.gov/pubmed/14674895>.

18. de Leval L, Harris NL, Longtine J, et al. Cutaneous b-cell lymphomas of follicular and marginal zone types: use of Bcl-6, CD10, Bcl-2, and CD21 in differential diagnosis and classification. *Am J Surg Pathol* 2001;25:732-741. Available at: <https://www.ncbi.nlm.nih.gov/pubmed/11395550>.

19. Pham-Ledard A, Cowppli-Bony A, Doussau A, et al. Diagnostic and prognostic value of BCL2 rearrangement in 53 patients with follicular lymphoma presenting as primary skin lesions. *Am J Clin Pathol* 2015;143:362-373. Available at: <https://www.ncbi.nlm.nih.gov/pubmed/25696794>.

20. Servitje O, Climent F, Colomo L, et al. Primary cutaneous vs secondary cutaneous follicular lymphomas: A comparative study focused on BCL2, CD10, and t(14;18) expression. *J Cutan Pathol* 2019;46:182-189. Available at: <https://www.ncbi.nlm.nih.gov/pubmed/30511443>.

21. Kodama K, Massone C, Chott A, et al. Primary cutaneous large B-cell lymphomas: clinicopathologic features, classification, and prognostic factors in a large series of patients. *Blood* 2005;106:2491-2497. Available at: <https://www.ncbi.nlm.nih.gov/pubmed/15947086>.

22. Hoefnagel JJ, Mulder MM, Dreef E, et al. Expression of B-cell transcription factors in primary cutaneous B-cell lymphoma. *Mod Pathol* 2006;19:1270-1276. Available at: <https://www.ncbi.nlm.nih.gov/pubmed/16778825>.

23. Espinet B, Garcia-Herrera A, Gallardo F, et al. FOXP1 molecular cytogenetics and protein expression analyses in primary cutaneous large B cell lymphoma, leg-type. *Histol Histopathol* 2011;26:213-221. Available at: <https://www.ncbi.nlm.nih.gov/pubmed/21154235>.

24. Schrader AMR, Jansen PM, Vermeer MH, et al. High Incidence and Clinical Significance of MYC Rearrangements in Primary Cutaneous Diffuse Large B-Cell Lymphoma, Leg Type. *Am J Surg Pathol* 2018;42:1488-1494. Available at: <https://www.ncbi.nlm.nih.gov/pubmed/30113335>.

25. Baldassano MF, Bailey EM, Ferry JA, et al. Cutaneous lymphoid hyperplasia and cutaneous marginal zone lymphoma: comparison of morphologic and immunophenotypic features. *Am J Surg Pathol* 1999;23:88-96. Available at: <https://www.ncbi.nlm.nih.gov/pubmed/9888708>.

26. Leinweber B, Colli C, Chott A, et al. Differential diagnosis of cutaneous infiltrates of B lymphocytes with follicular growth pattern. *Am J Dermatopathol* 2004;26:4-13. Available at: <https://www.ncbi.nlm.nih.gov/pubmed/14726817>.

27. Schafernack KT, Variakojis D, Goolsby CL, et al. Clonality assessment of cutaneous B-cell lymphoid proliferations: a comparison of flow cytometry immunophenotyping, molecular studies, and immunohistochemistry/in situ hybridization and review of the literature. *Am J Dermatopathol* 2014;36:781-795. Available at: <https://www.ncbi.nlm.nih.gov/pubmed/24335516>.

28. Murase T, Yamaguchi M, Suzuki R, et al. Intravascular large B-cell lymphoma (IVLBCL): a clinicopathologic study of 96 cases with special reference to the immunophenotypic heterogeneity of CD5. *Blood* 2007;109:478-485. Available at: <https://www.ncbi.nlm.nih.gov/pubmed/16985183>.

29. Koens L, Vermeer MH, Willemze R, Jansen PM. IgM expression on paraffin sections distinguishes primary cutaneous large B-cell lymphoma, leg type from primary cutaneous follicle center lymphoma. *Am J Surg*



# NCCN Guidelines Version 2.2021

## Primary Cutaneous Lymphomas

Pathol 2010;34:1043-1048. Available at:  
<https://www.ncbi.nlm.nih.gov/pubmed/20551823>.

30. Pham-Ledard A, Beylot-Barry M, Barbe C, et al. High frequency and clinical prognostic value of MYD88 L265P mutation in primary cutaneous diffuse large B-cell lymphoma, leg-type. *JAMA Dermatol* 2014;150:1173-1179. Available at:  
<https://www.ncbi.nlm.nih.gov/pubmed/25055137>.

31. Child FJ, Russell-Jones R, Woolford AJ, et al. Absence of the t(14;18) chromosomal translocation in primary cutaneous B-cell lymphoma. *Br J Dermatol* 2001;144:735-744. Available at:  
<https://www.ncbi.nlm.nih.gov/pubmed/11298531>.

32. Wehkamp U, Pott C, Unterhalt M, et al. Skin Involvement of Mantle Cell Lymphoma May Mimic Primary Cutaneous Diffuse Large B-cell Lymphoma, Leg Type. *Am J Surg Pathol* 2015;39:1093-1101. Available at:  
<https://www.ncbi.nlm.nih.gov/pubmed/26034867>.

33. Kim YH, Willemze R, Pimpinelli N, et al. TNM classification system for primary cutaneous lymphomas other than mycosis fungoides and Sezary syndrome: a proposal of the International Society for Cutaneous Lymphomas (ISCL) and the Cutaneous Lymphoma Task Force of the European Organization of Research and Treatment of Cancer (EORTC). *Blood* 2007;110:479-484. Available at:  
<https://www.ncbi.nlm.nih.gov/pubmed/17339420>.

34. Kheterpal MK, Dai J, Geller S, et al. Role of imaging in low-grade cutaneous B-cell lymphoma presenting in the skin. *J Am Acad Dermatol* 2019;81:970-976. Available at:  
<https://www.ncbi.nlm.nih.gov/pubmed/30703460>.

35. Vachhani P, Neppalli VT, Cancino CJ, et al. Radiological imaging and bone marrow biopsy in staging of cutaneous B-cell lymphoma. *Br J Haematol* 2019;184:674-676. Available at:  
<https://www.ncbi.nlm.nih.gov/pubmed/29468663>.

36. Kumar R, Xiu Y, Zhuang HM, Alavi A.  
18F-fluorodeoxyglucose-positron emission tomography in evaluation of

primary cutaneous lymphoma. *Br J Dermatol* 2006;155:357-363. Available at:  
<https://www.ncbi.nlm.nih.gov/pubmed/16882175>.

37. Senff NJ, Kluin-Nelemans HC, Willemze R. Results of bone marrow examination in 275 patients with histological features that suggest an indolent type of cutaneous B-cell lymphoma. *Br J Haematol* 2008;142:52-56. Available at:  
<https://www.ncbi.nlm.nih.gov/pubmed/18422781>.

38. Eich HT, Eich D, Micke O, et al. Long-term efficacy, curative potential, and prognostic factors of radiotherapy in primary cutaneous B-cell lymphoma. *Int J Radiat Oncol Biol Phys* 2003;55:899-906. Available at:  
<https://www.ncbi.nlm.nih.gov/pubmed/12605967>.

39. Smith BD, Glusac EJ, McNiff JM, et al. Primary cutaneous B-cell lymphoma treated with radiotherapy: a comparison of the European Organization for Research and Treatment of Cancer and the WHO classification systems. *J Clin Oncol* 2004;22:634-639. Available at:  
<https://www.ncbi.nlm.nih.gov/pubmed/14966086>.

40. Senff NJ, Hoefnagel JJ, Neelis KJ, et al. Results of radiotherapy in 153 primary cutaneous B-Cell lymphomas classified according to the WHO-EORTC classification. *Arch Dermatol* 2007;143:1520-1526. Available at:  
<https://www.ncbi.nlm.nih.gov/pubmed/18087001>.

41. Pedretti S, Urpis M, Leali C, et al. Primary cutaneous non-Hodgkin lymphoma: results of a retrospective analysis in the light of the recent ILROG guidelines. *Tumori* 2018;104:394-400. Available at:  
<https://www.ncbi.nlm.nih.gov/pubmed/28218382>.

42. De Felice F, Grapulin L, Pieroni A, et al. Radiation therapy in indolent primary cutaneous B cell lymphoma: a single institute experience. *Ann Hematol* 2018;97:2411-2416. Available at:  
<https://www.ncbi.nlm.nih.gov/pubmed/30094511>.

43. Neelis KJ, Schimmel EC, Vermeer MH, et al. Low-dose palliative radiotherapy for cutaneous B- and T-cell lymphomas. *Int J Radiat Oncol Biol Phys* 2009;74:154-158. Available at:  
<https://www.ncbi.nlm.nih.gov/pubmed/18834672>.





# NCCN Guidelines Version 2.2021

## Primary Cutaneous Lymphomas

44. Akhtari M, Reddy JP, Pinnix CC, et al. Primary cutaneous B-cell lymphoma (non-leg type) has excellent outcomes even after very low dose radiation as single-modality therapy. *Leuk Lymphoma* 2016;57:34-38. Available at: <https://www.ncbi.nlm.nih.gov/pubmed/25860237>.

45. Senff NJ, Noordijk EM, Kim YH, et al. European Organization for Research and Treatment of Cancer and International Society for Cutaneous Lymphoma consensus recommendations for the management of cutaneous B-cell lymphomas. *Blood* 2008;112:1600-1609. Available at: <https://www.ncbi.nlm.nih.gov/pubmed/18567836>.

46. Pashtan I, Mauch PM, Chen YH, et al. Radiotherapy in the management of localized primary cutaneous B-cell lymphoma. *Leuk Lymphoma* 2013;54:726-730. Available at: <https://www.ncbi.nlm.nih.gov/pubmed/22916994>.

47. Servitje O, Muniesa C, Benavente Y, et al. Primary cutaneous marginal zone B-cell lymphoma: response to treatment and disease-free survival in a series of 137 patients. *J Am Acad Dermatol* 2013;69:357-365. Available at: <https://www.ncbi.nlm.nih.gov/pubmed/23796549>.

48. Heinzerling LM, Urbanek M, Funk JO, et al. Reduction of tumor burden and stabilization of disease by systemic therapy with anti-CD20 antibody (rituximab) in patients with primary cutaneous B-cell lymphoma. *Cancer* 2000;89:1835-1844. Available at: <https://www.ncbi.nlm.nih.gov/pubmed/11042581>.

49. Heinzerling L, Dummer R, Kempf W, et al. Intralesional therapy with anti-CD20 monoclonal antibody rituximab in primary cutaneous B-cell lymphoma. *Arch Dermatol* 2000;136:374-378. Available at: <https://www.ncbi.nlm.nih.gov/pubmed/10724200>.

50. Gellrich S, Muche JM, Wilks A, et al. Systemic eight-cycle anti-CD20 monoclonal antibody (rituximab) therapy in primary cutaneous B-cell lymphomas--an applicational observation. *Br J Dermatol* 2005;153:167-173. Available at: <http://www.ncbi.nlm.nih.gov/pubmed/16029344>.

51. Morales AV, Advani R, Horwitz SM, et al. Indolent primary cutaneous B-cell lymphoma: experience using systemic rituximab. *J Am Acad Dermatol* 2008;59:953-957. Available at: <http://www.ncbi.nlm.nih.gov/pubmed/18817999>.

52. Valencak J, Weihsenruber F, Rappersberger K, et al. Rituximab monotherapy for primary cutaneous B-cell lymphoma: response and follow-up in 16 patients. *Ann Oncol* 2009;20:326-330. Available at: <https://www.ncbi.nlm.nih.gov/pubmed/18836086>.

53. Penate Y, Hernandez-Machin B, Perez-Mendez LI, et al. Intralesional rituximab in the treatment of indolent primary cutaneous B-cell lymphomas: an epidemiological observational multicentre study. The Spanish Working Group on Cutaneous Lymphoma. *Br J Dermatol* 2012;167:174-179. Available at: <https://www.ncbi.nlm.nih.gov/pubmed/22356294>.

54. Vakeva L, Ranki A, Malkonen T. Intralesional Rituximab Treatment for Primary Cutaneous B-cell Lymphoma: Nine Finnish Cases. *Acta Derm Venereol* 2016;96:396-397. Available at: <https://www.ncbi.nlm.nih.gov/pubmed/26525093>.

55. Eberle FC, Holstein J, Scheu A, et al. Intralesional anti-CD20 antibody for low-grade primary cutaneous B-cell lymphoma: Adverse reactions correlate with favorable clinical outcome. *J Dtsch Dermatol Ges* 2017;15:319-323. Available at: <https://www.ncbi.nlm.nih.gov/pubmed/28177583>.

56. Kerl K, Prins C, Saurat JH, French LE. Intralesional and intravenous treatment of cutaneous B-cell lymphomas with the monoclonal anti-CD20 antibody rituximab: report and follow-up of eight cases. *Br J Dermatol* 2006;155:1197-1200. Available at: <https://www.ncbi.nlm.nih.gov/pubmed/17107389>.

57. Bekkenk MW, Vermeer MH, Geerts ML, et al. Treatment of multifocal primary cutaneous B-cell lymphoma: a clinical follow-up study of 29 patients. *J Clin Oncol* 1999;17:2471-2478. Available at: <https://www.ncbi.nlm.nih.gov/pubmed/10561311>.



# NCCN Guidelines Version 2.2021

## Primary Cutaneous Lymphomas

58. Rijlaarsdam JU, Toonstra J, Meijer OW, et al. Treatment of primary cutaneous B-cell lymphomas of follicle center cell origin: a clinical follow-up study of 55 patients treated with radiotherapy or polychemotherapy. *J Clin Oncol* 1996;14:549-555. Available at: <https://www.ncbi.nlm.nih.gov/pubmed/8636770>.

59. Brice P, Cazals D, Mounier N, et al. Primary cutaneous large-cell lymphoma: analysis of 49 patients included in the LNH87 prospective trial of polychemotherapy for high-grade lymphomas. *Groupe d'Etude des Lymphomes de l'Adulte. Leukemia* 1998;12:213-219. Available at: <https://www.ncbi.nlm.nih.gov/pubmed/9519784>.

60. Trent JT, Romanelli P, Kerdel FA. Topical targretin and intralesional interferon alfa for cutaneous lymphoma of the scalp. *Arch Dermatol* 2002;138:1421-1423. Available at: <https://www.ncbi.nlm.nih.gov/pubmed/12437444>.

61. Bachmeyer C, Orlandini V, Aractingi S. Topical mechlorethamine and clobetasol in multifocal primary cutaneous marginal zone-B cell lymphoma. *Br J Dermatol* 2006;154:1207-1209. Available at: <https://www.ncbi.nlm.nih.gov/pubmed/16704661>.

62. Coors EA, Schuler G, Von Den Driesch P. Topical imiquimod as treatment for different kinds of cutaneous lymphoma. *Eur J Dermatol* 2006;16:391-393. Available at: <https://www.ncbi.nlm.nih.gov/pubmed/16935796>.

63. Stavrakoglou A, Brown VL, Coutts I. Successful treatment of primary cutaneous follicle centre lymphoma with topical 5% imiquimod. *Br J Dermatol* 2007;157:620-622. Available at: <https://www.ncbi.nlm.nih.gov/pubmed/17553050>.

64. Perry A, Vincent BJ, Parker SR. Intralesional corticosteroid therapy for primary cutaneous B-cell lymphoma. *Br J Dermatol* 2010;163:223-225. Available at: <https://www.ncbi.nlm.nih.gov/pubmed/20394622>.

65. Kollipara R, Hans A, Hall J, Lisle A. A case report of primary cutaneous marginal zone lymphoma treated with intralesional steroids.

*Dermatol Online J* 2015;21. Available at: <https://www.ncbi.nlm.nih.gov/pubmed/26437162>.

66. Haverkos B, Tyler K, Gru AA, et al. Primary Cutaneous B-Cell Lymphoma: Management and Patterns of Recurrence at the Multimodality Cutaneous Lymphoma Clinic of The Ohio State University. *Oncologist* 2015;20:1161-1166. Available at: <https://www.ncbi.nlm.nih.gov/pubmed/26306900>.

67. Specht L, Dabaja B, Illidge T, et al. Modern radiation therapy for primary cutaneous lymphomas: field and dose guidelines from the International Lymphoma Radiation Oncology Group. *Int J Radiat Oncol Biol Phys* 2015;92:32-39. Available at: <https://www.ncbi.nlm.nih.gov/pubmed/25863751>.

68. Grange F, Beylot-Barry M, Courville P, et al. Primary cutaneous diffuse large B-cell lymphoma, leg type: clinicopathologic features and prognostic analysis in 60 cases. *Arch Dermatol* 2007;143:1144-1150. Available at: <https://www.ncbi.nlm.nih.gov/pubmed/17875875>.

69. Posada Garcia C, Florez A, Pardavila R, et al. Primary cutaneous large B-cell lymphoma, leg type, successfully treated with rituximab plus chemotherapy. *Eur J Dermatol* 2009;19:394-395. Available at: <https://www.ncbi.nlm.nih.gov/pubmed/19467966>.

70. Grange F, Maubec E, Bagot M, et al. Treatment of cutaneous B-cell lymphoma, leg type, with age-adapted combinations of chemotherapies and rituximab. *Arch Dermatol* 2009;145:329-330. Available at: <https://www.ncbi.nlm.nih.gov/pubmed/19289772>.

71. Grange F, Joly P, Barbe C, et al. Improvement of survival in patients with primary cutaneous diffuse large B-cell lymphoma, leg type, in France. *JAMA Dermatol* 2014;150:535-541. Available at: <https://www.ncbi.nlm.nih.gov/pubmed/24647650>.

72. Kim MJ, Hong ME, Maeng CH, et al. Clinical features and treatment outcomes of primary cutaneous B-cell lymphoma: a single-center analysis in South Korea. *Int J Hematol* 2015;101:273-278. Available at: <https://www.ncbi.nlm.nih.gov/pubmed/25552248>.



# NCCN Guidelines Version 2.2021

## Primary Cutaneous Lymphomas

### Mycosis Fungoides and Sézary Syndrome

#### Overview

Cutaneous T cell lymphomas (CTCL) are a group of non-Hodgkin lymphomas (NHL) that primarily present in the skin, and at times progress to involve lymph nodes, blood, and visceral organs.<sup>1-3</sup> Mycosis fungoides (MF) is the most common subtype and is usually associated with an indolent clinical course with intermittent, stable, or slow progression of the lesions.<sup>4</sup> Extracutaneous involvement (lymph nodes, blood, or less commonly other organs) or large cell transformation (LCT) may be seen in advanced-stage disease. Sézary syndrome (SS) is a rare erythrodermic, leukemic variant characterized by significant blood involvement, erythroderma, and often lymphadenopathy.<sup>5,6</sup> MF is caused by the malignant transformation of skin-resident effector memory T cells while SS is thought to arise from thymic memory T cells, supporting the contention that SS is a process distinct from MF.<sup>5</sup> Cases presenting as an overlap of these two conditions also exist.

Folliculotropic MF (FMF), granulomatous slack skin, and pagetoid reticulosis are recognized as distinct clinicopathologic variants of MF in the WHO-EORTC classification.<sup>2</sup> FMF and LCT are histologic features that can occur irrespective of stage, but the incidence of LCT is higher in patients with advanced-stage disease.<sup>7-9</sup> Expert dermatopathology and/or hematopathology review is needed to confirm the diagnosis. This is especially true for the less common variants of the disease, which can be difficult to distinguish from other lymphoproliferative disorders. Genomic studies have demonstrated further biologic diversity within MF.<sup>10</sup>

Due to the rarity and diversity of the condition and the need for an individualized approach, the NCCN Guidelines Panel recommends that patients diagnosed with MF and SS be treated at specialized centers with expertise in the management of this disease.<sup>11</sup>

#### Literature Search Criteria and Guidelines Update Methodology

Prior to the update of this version of the NCCN Guidelines® for Primary Cutaneous Lymphomas, an electronic search of the PubMed database was performed to obtain key literature in MF and SS published since the previous Guidelines update using the following search terms: cutaneous T-cell lymphomas, mycosis fungoides, and Sézary syndrome. The PubMed database was chosen as it remains the most widely used resource for medical literature and indexes peer-reviewed biomedical literature.<sup>12</sup>

The search results were narrowed by selecting studies in humans published in English. Results were confined to the following article types: Clinical Trial, Phase II; Clinical Trial, Phase III; Clinical Trial, Phase IV; Guideline; Randomized Controlled Trial; Meta-Analysis; Systematic Reviews; and Validation Studies.

The data from key PubMed articles deemed as relevant to these guidelines have been included in this version of the Discussion section. Recommendations for which high-level evidence is lacking are based on the panel's review of lower-level evidence and expert opinion.

The complete details of the Development and Update of the NCCN Guidelines are available at [www.NCCN.org](http://www.NCCN.org).

#### Staging

The T (skin), N (node), M (visceral), and B (blood involvement) classification and clinical staging developed by the International Society for Cutaneous Lymphomas (ISCL) and EORTC<sup>13</sup> are outlined on [MFSS-3](#) and [MFSS-4](#).

The extent of skin involvement is based on the percentage of body surface area (BSA) where the patient's palm (without digits) is equivalent to 0.5% BSA and the palm with all 5 digits is approximately 1% BSA.<sup>13</sup> In the



# NCCN Guidelines Version 2.2021

## Primary Cutaneous Lymphomas

revised staging system, T1 disease (limited skin involvement) is defined as patches, papules, and/or plaques covering less than 10% BSA. T2 (skin-only disease) is defined as patches, papules, and/or plaques covering 10% or greater BSA. Patch diagnosis is noted as T1a or T2a and plaque diagnosis is noted as T1b or T2b. T3 (tumor-stage disease) is defined by the presence of 1 or more tumors ( $\geq 1$  cm in diameter with nodular quality). T4 (erythrodermic disease) is defined as confluence of erythroderma covering 80% or greater BSA. However, this criterion of 80% is subjective and the BSA can fluctuate in patients with erythrodermic MF or SS. Thus, other features including keratoderma, ectropion, or leg edema should also be evaluated in patients with erythrodermic MF or SS.

Lymph node biopsy for staging is recommended only for clinically abnormal nodes ( $>1.5$  cm in longest diameter). Lymphadenopathy can be clinically reactive or dermatopathic; thus, not all enlarged lymph nodes are sampled. The designation “Nx” may be used for abnormal lymph nodes without histologic evaluation. The designation “Mx” can be used for presence of abnormal visceral sites without histologic evaluation. Visceral disease with the involvement of an organ (eg, spleen, liver) other than the skin, nodes, or blood should be documented using imaging studies.

Blood involvement is classified into three groups: B0, B1, and B2 based on the number of immunophenotypically abnormal T cells in the blood (MFSS-3). B1 or B2 is best characterized by both flow cytometry and the presence of clonally related neoplastic T cells as in the skin by T-cell receptor (*TCR*) gene rearrangement analysis. A diagnosis of SS requires B2 level of blood involvement.<sup>13</sup>

### Prognosis

Age at presentation, overall stage, extent and type of skin involvement (T classification), presence of extracutaneous disease, extent of peripheral blood involvement (as defined by flow cytometric measurements of Sézary

cell counts), elevated lactate dehydrogenase (LDH), and presence of LCT have been identified as the most significant factors for disease progression and/or survival in patients with MF.<sup>14-20</sup> In a retrospective cohort study of 525 patients with MF or SS, patient age, T classification, and presence of extracutaneous disease retained independent prognostic value in a multivariate analysis.<sup>15</sup> The risk of disease progression, development of extracutaneous disease, or death due to MF correlated with initial T classification. Limited patch or plaque disease has an excellent prognosis compared to patients with widespread plaque-type or tumor-type skin disease or erythrodermic skin involvement, and extracutaneous disease is associated with a poor prognosis.<sup>17,18</sup>

In the Cutaneous Lymphoma International Consortium (CLIC) study that evaluated the relevance of prognostic markers on overall survival (OS) in 1275 patients with advanced-stage MF and SS, stage IV disease, aged 60 years, LCT and LDH levels were identified as independent prognostic markers that could be used together in a prognostic model to identify three risk groups with significantly different survival outcomes.<sup>20</sup> The 5-year survival rates were 68%, 44%, and 28%, respectively, for low-risk, intermediate-risk, and high-risk groups. A prospective international study by CLIC (Prospective Cutaneous Lymphoma International Prognostic Index [PROCLIP] international study) is underway to identify any new prognostic markers and validate the refined prognostic index model to optimize risk-stratified management in patients with MF or SS.<sup>21-23</sup>

### Diagnosis

Biopsy of suspicious skin sites along with immunohistochemistry (IHC) of biopsy specimen are essential to confirm the diagnosis. Biopsy of enlarged lymph nodes (ie, palpable nodes  $>1.5$  cm in diameter and/or firm, irregular, clustered, or fixed nodes) or extracutaneous sites is recommended. Excisional or incisional biopsy is preferred over core needle biopsy. Fine-needle aspiration (FNA) alone is not sufficient for the





# NCCN Guidelines Version 2.2021

## Primary Cutaneous Lymphomas

initial diagnosis. Bone marrow biopsy is not required for disease staging, but may be helpful in those with an unexplained hematologic abnormality.<sup>13</sup>

MF and SS cells are typically characterized by the following immunophenotype: CD2+, CD3+, CD5+, CD4+, CD8-, CCR4+, TCR-beta+, and CD45RO+ and they lack certain T-cell markers, CD7 and CD26.<sup>24</sup> However, there are subtypes of MF that are CD8+ (especially the hypopigmented variant) or CD4/CD8 dual negative (in those with LCT), although rare. The T cells also express cutaneous lymphocyte antigen (CLA) and TH2 cytokines. They are also associated with a loss of TH1 and IL-12 cytokines. The IHC panel of skin biopsy should include CD2, CD3, CD4, CD5, CD7, CD8, CD20, and CD30. Additional immunohistochemical markers such as CD25, CD56, TIA1, granzyme B, TCR beta, and TCR delta, may be useful in selected circumstances.

Primary cutaneous follicular helper T-cell (TFH) lymphoma is a recently described variant of peripheral T-cell lymphoma (PTCL)-not otherwise specified. This variant usually presents as a sudden onset of multiple plaques and nodules characterized by the expression TFH markers such as CXCL13, ICOS, and PD-1.<sup>25,26</sup> Identification of these markers along with other clinical and histopathologic features would be useful to distinguish MFSS from CTCL of TFH origin.<sup>27,28</sup>

Molecular analysis to detect clonal *TCR* gene rearrangements is useful to support the diagnosis of MF and SS as well as to distinguish MF from inflammatory dermatoses, especially if identical clones are demonstrated in more than one skin site.<sup>29,30</sup> However, results showing clonal *TCR* gene rearrangements should not be interpreted as the sole and defining test for malignancy since clonal *TCR* rearrangements can at times be seen in non-malignant conditions or may not be demonstrated in all cases of MF and SS. *TCR* rearrangement analysis by high throughput sequencing (or next generation sequencing) is a more sensitive and

specific test of clonality that can identify the clones by the genetic sequence of the *TCR*.<sup>31,32</sup> Demonstration of identical clones in the skin, blood, and/or lymph nodes may be helpful both for diagnosis and differentiating MF and SS from benign inflammatory skin diseases.

Assessment of peripheral blood involvement optimally by flow cytometry is important for staging and is also useful to differentiate CTCL with peripheral blood involvement from other forms of leukemic T-cell lymphomas (eg, T-cell prolymphocytic leukemia, lymphocytic variant of hypereosinophilic syndrome, adult T-cell leukemia/lymphoma [ATLL]). Flow cytometry allows for the assessment and quantitation of an expanded population of CD4+ cells with abnormal immunophenotype (CD4+/CD26- or CD4+/CD7- or other aberrantly expressed phenotype).<sup>33</sup> HTLV-1 status, assessed either by HTLV-1 serology or other methods, may be useful in at-risk populations to exclude the diagnosis of ATLL (which is usually HTLV-1-positive).

### Workup

The initial workup of patients diagnosed with MF or SS involves a history and complete skin examination (assessment of the extent of disease [ie, percent of BSA] and type of skin lesion [eg, patch/plaque, tumor, erythroderma]), palpation of peripheral lymph nodes and palpation for organomegaly.<sup>13</sup>

Laboratory studies should include a complete blood count (CBC), Sézary flow cytometric study (optional for T1 disease), comprehensive metabolic panel, and assessment of LDH levels. Analysis of clonal *TCR* gene arrangement of peripheral blood lymphocytes is recommended if blood involvement is suspected.

CT with contrast of the chest, abdomen, and pelvis or integrated whole body PET/CT scan is recommended for patients with T3 or T4 disease and should be considered for patients with T2a (patch disease with ≥10%



# NCCN Guidelines Version 2.2021

## Primary Cutaneous Lymphomas

BSA), T2b (widespread plaque-type skin disease), FMF or LCT, palpable adenopathy, or abnormal laboratory studies. In an analysis of 375 patients with stage T1/T2 MF enrolled in the PROCLIP international study, the presence of plaques was associated with a significant increase in the identification of radiologically enlarged or involved lymph nodes in patients with early-stage MF.<sup>22</sup>

A CT scan of the neck may be useful in some circumstances. Integrated PET/CT was found to be more sensitive for the detection of lymph node involvement than CT alone and can help direct biopsies.<sup>34</sup> PET scan may also be preferred in patients with extranodal disease that may be inadequately imaged by CT. Many skin-directed and systemic therapies are contraindicated or are of unknown safety in pregnancy. Therefore, pregnancy testing is recommended for women of childbearing age.

### Treatment Considerations

While MF and SS are treatable, they are not curable with conventional systemic therapy and the symptoms of the disease have significant impact on the quality of life. Patients with MF, particularly those with early-stage disease, can have very good prognosis and may live with the disease for decades.<sup>17,18</sup>

The optimal treatment for any patient at any given time should be individualized based on overall goals of therapy (improve the disease burden and quality of life, attain adequate response to reduce/control symptoms, and minimize the risk of progression), route of administration, and toxicity profile. Discussions regarding cumulative toxicity of therapy, impact of therapy on quality of life, and supportive care for symptom control are a key part of the management of patients with MF and SS. Most of the treatment options do not result in durable remissions and are often given in an ongoing or maintenance fashion to achieve disease control with as little impact on quality of life as possible.

Patients with a clinical benefit and/or those with disease responding to primary treatment can be considered for maintenance or tapering of regimens to optimize response duration. Patients with disease that does not have adequate response to a systemic therapy regimen are generally treated with an alternative regimen recommended for primary treatment before moving on to treatment for refractory disease. This supports the therapeutic principle of initial treatment with less toxic regimens before moving on to treatment options that carry a higher risk of cumulative toxicity and/or immunosuppression. Along these lines, the NCCN Guidelines have categorized systemic therapies with lower toxicity as SYST-CAT A and therapies that are often used later in the disease course as SYST-CAT B. Disease relapse (with the same stage) after discontinuation of therapy often responds well to re-treatment with previous therapy.

### Selection of Therapy Based on Clinical and Pathologic Features

Skin-directed therapies (topical therapy, phototherapy, radiation therapy [RT], or total skin electronic beam therapy [TSEBT]) that can provide disease control without major cumulative toxicities are recommended for patients with early-stage disease and limited skin involvement (stage IA or stage IB–IIA). While stage IB–IIA patch/plaque disease can be effectively treated predominantly with skin-directed therapies, systemic therapy can be considered for stage IB–IIA with higher skin disease burden, concerning pathologic features (eg, LCT or FMF), predominantly plaque disease, and/or inadequate response to skin-directed therapy. Systemic therapy is recommended for advanced-stage disease (≥stage IIB). On the other hand, stage IIB patients with single or few T3 lesions can be treated with external beam RT (EBRT) with further delay of systemic therapy and TSEBT may be used for patients with stage IB–IIB disease, with excellent response expected.





# NCCN Guidelines Version 2.2021

## Primary Cutaneous Lymphomas

In the PROCLIP study, the use of systemic therapy was significantly associated with higher clinical stage, presence of plaques, and FMF.<sup>23</sup> In multivariate analysis, the presence of plaques and FMF were significantly associated with the use of systemic therapy and skin-directed therapy was superior to systemic therapy even in patients with these disease characteristics. The overall response rate (ORR) to first-line skin-directed therapy was 73% compared to 57% for systemic therapy.

Systemic therapy can be and often is combined with skin-directed therapy to maximize clinical responses in the skin compartment and also to provide additive efficacy without cumulative toxicities. For those who require systemic therapy, due to either advanced-stage disease or inadequate disease control on skin-directed therapy, there are many options; however, given the rare nature of this disease, only a few have been evaluated in randomized studies, as discussed in the section “Systemic Therapies.” Therefore, a clinical trial should be considered when appropriate and available.

Data from clinical trials that have evaluated various treatment strategies (skin-directed therapy, systemic therapy, and combination therapies) are discussed below.

### Skin-Directed Therapies

Topical therapy with corticosteroids, mechlorethamine (nitrogen mustard), topical retinoids or topical imiquimod, or RT are indicated for patients with localized disease.

Phototherapy and TSEBT are indicated for patients with widespread skin involvement. Topical retinoids are not recommended for generalized skin involvement because these treatments can cause substantial irritation.

### Topical Corticosteroids

Topical corticosteroids are effective for early-stage MF (especially for the treatment of patch-stage MF) resulting in measurable improvement in BSA involvement and high ORR (94%; 63% complete response [CR]; 13% partial response [PR]) and 82% (25% CR; 57% PR), respectively, in patients with stage T1 and T2 disease).<sup>35-37</sup> However, long-term use of a topical steroid may lead to skin atrophy or striae formation and the risk becomes greater with increased potency of the steroid. Moreover, high-potency steroids used on large skin surfaces may lead to systemic absorption.

### Topical Mechlorethamine (nitrogen mustard)

Topical mechlorethamine has been used for the management of MF for many decades resulting in an ORR of 83% (50% CR). Patients with T1 disease had a higher ORR (93% vs. 72%), CR rate (65% vs. 34%), longer median OS (21 months vs. 15 months), and higher 5-year OS rate (97% vs. 72%) than those with T2 disease.<sup>38</sup> The efficacy was similar for aqueous and ointment preparations, although the ointment was associated with reduced hypersensitivity reactions.

A topical gel formulation of mechlorethamine was approved by the FDA in 2013 based on the results of a multicenter randomized phase II trial that demonstrated the non-inferiority of topical gel formulation compared to the compounded ointment formulation for the treatment of stage IA or IIA MF in patients (n = 260) who had not been treated with topical mechlorethamine within 2 years of study enrollment and had not received prior therapy with topical mechlorethamine.<sup>39</sup> Response rate based on Composite Assessment of Index Lesion Severity was 59% for the topical gel formulation compared to 48% for the ointment formulation. No study treatment-related serious adverse events were reported, and no systemic absorption was detected.



# NCCN Guidelines Version 2.2021

## Primary Cutaneous Lymphomas

### **Topical Retinoids**

Bexarotene gel is the only FDA-approved synthetic topical retinoid for the treatment of MF and SS. In the phase I–II trial of 67 patients with early-stage MF, the ORR was 63% (21% CR) and the estimated median response duration was 99 weeks.<sup>40</sup> Response rates were higher among the patients who had had no prior therapy compared with those who had received prior topical therapies (75% vs. 67%). In the phase III multicenter study of 50 patients with early-stage refractory MF, the ORR was 44% (8% CR).<sup>41</sup>

Tazarotene 0.1% topical gel/cream was reported to be a well-tolerated and active adjuvant therapy by clinical and histologic assessments in a small series of patients with early patch or plaque MF lesions (stable or refractory to therapy).<sup>42,43</sup>

### **Topical Imiquimod**

Imiquimod has also demonstrated activity in a small number of patients with early-stage MF refractory to other therapies.<sup>44–47</sup> Given the common skin irritation toxicity observed with topical retinoids and imiquimod, these agents are best for treatment of localized, limited areas.

### **Topical Carmustine**

Topical carmustine is an effective treatment for patch/plaque early-stage MF resulting in high response rates of 92% and 64% in patients with T1 and T2 disease, respectively, at 36 months.<sup>48,49</sup> Topical carmustine is included with a category 2B recommendation.

### **Radiation Therapy**

MF is extremely radiosensitive and patients with unilesional or stage IA MF may be managed effectively with local RT alone (without adjuvant therapy), resulting in an ORR of 97% to 100%.<sup>50,51</sup> Recent studies have shown that low-dose involved-field RT (IFRT) also results in high response rates without any toxicity in patients with MF.<sup>51–53</sup> In a study that included

31 patients with MF, low-dose RT (4 Gy in 2 fractions) resulted in a CR rate of only 30%, whereas increasing the dose to 8 Gy in 2 fractions yielded a CR rate of 92%.<sup>52</sup> Patients in whom low-dose RT failed were retreated with 20 Gy in 8 fractions. In a large series of 58 patients treated with 8 Gy in a single fraction, the CR rate was 94% for individual lesions after a median follow-up of 41 months.<sup>53</sup>

Optimal management of individual plaque and tumor lesions is with EBRT (8–12 Gy, 8 Gy may be given in a single-fraction; 24–30 Gy is recommended for more durable duration of response or for unilesional presentation).<sup>51,53</sup>

### **Total Skin Electron Beam Therapy**

TSEBT (conventional dose [30–36 Gy] or low dose [<30 Gy]) either alone or in combination with adjuvant therapy has been shown to be effective for the treatment of early-stage MF.<sup>54–57</sup> TSEBT at a conventional dose of ≥30 Gy was associated with a non-significant trend towards better clinical benefit and was also associated with better outcomes in patients with T2 disease compared to those with T3 disease.<sup>56,57</sup> In a retrospective study that evaluated low-dose TSEBT in 102 patients with T2 to T4 disease (excluding those with extracutaneous disease), TSEBT doses of 10 Gy to <20 Gy and 20 Gy to <30 Gy resulted in ORRs of 98% and 97%, respectively, which were comparable to the ORRs achieved with standard-dose TSEBT (≥30 Gy).<sup>55</sup> The OS and progression-free survival (PFS) rates were not significantly different by dose groups and were comparable to that of standard-dose TSEBT (≥30 Gy).

Recent studies suggest that lower-dose TSEBT (10–12 Gy over a period of 2–3 weeks) is sufficiently active and may also be associated with fewer short-term complications and better ability to re-treat progressive disease (PD) or cutaneous relapses.<sup>58–63</sup> A pooled analysis of 3 phase II clinical trials that evaluated low-dose TSEBT (12 Gy; 1 Gy per fraction over 3 weeks) in 33 patients with MF reported an ORR of 88% (including 9



# NCCN Guidelines Version 2.2021

## Primary Cutaneous Lymphomas

patients with a CR).<sup>59</sup> The median time to response and median duration of clinical benefit were 8 weeks and 71 weeks. In a cohort of 103 patients with MF treated with low-dose TSEBT (12 Gy in 8 fractions for 2 weeks; the majority of patients had stage IB or IIB disease), after a median follow-up of 21 months, the ORR was 87% (18% CR and 69% PR) and the median PFS was 13 months.<sup>62</sup> The median PFS was significantly longer for patients with stage IB disease (27 months) compared to 11 months and 10 months, respectively, for those with stage IIB or stage III disease. Low-dose TSEBT (12 Gy in 6–7 fractions) was also associated with favorable outcomes and significantly fewer grade 2 acute toxicities compared with conventional-dose TSEBT (30 Gy).<sup>61,64,65</sup> Further studies are warranted to confirm these findings and the use of low-dose TSEBT in combined modality regimens.

The recommended dose range for TSEBT is 12–36 Gy (generally 4–6 Gy per week). Lower total dose is associated with fewer short-term complications and better ability to re-treat relapsed disease. It is common practice to follow TSEBT with systemic therapies such as interferon (IFN) or bexarotene to maintain response, for patients with stage IB–IIA disease with higher skin disease burden. Adjuvant systemic therapy with systemic therapies listed under SYST-CAT A can be considered to improve response duration in patients with stage IIB (tumor stage) disease receiving TSEBT.<sup>66</sup>

TSEBT may not be well tolerated in patients with erythrodermic disease and should be used with caution. In these patients, TSEBT may be used with lower doses and slower fractionation. Antibiotic therapy should be considered since patients with erythrodermic disease are at increased risk of developing secondary infections.

### Phototherapy

Ultraviolet B (UVB including narrowband-UVB)<sup>67-71</sup> and psoralen plus ultraviolet A1 (PUVA/UVA-1)<sup>72-75</sup> are effective treatment options for

patients with early-stage MF. Narrowband UVB is the most common phototherapy approach and less skin damaging than PUVA/UVA-1. While some retrospective studies have reported that PUVA results in better responses and improved disease-free survival (DFS),<sup>76-78</sup> others have reported that UVB is as effective as PUVA for the treatment of early-stage MF.<sup>79,80</sup> However, these modalities have not been compared in randomized clinical trials.

It may be more beneficial to start with narrowband UVB than PUVA in patients with early patch-stage or thin-plaque disease, since narrowband UVB has less skin toxicity than broadband UVB and PUVA.<sup>81</sup> It should be noted that cumulative doses of UV radiation are associated with increased risk of UV radiation-associated skin malignancies.<sup>82</sup> Thus, phototherapy may not be appropriate for patients with a history of squamous or basal cell carcinoma or melanoma.

### Systemic Therapies

The NCCN Guidelines are structured with systemic therapy regimens categorized into two groups: SYST-CAT A and SYST-CAT B. The selection of SYST-CAT A versus SYST-CAT B regimens is dependent on clinical (eg, extent of patch/plaques; disease burden profile in the skin, lymph nodes, and blood; prior therapies; and comorbidities) and pathologic features (eg, LCT or FMF) and IHC data (eg, CD30 positivity). In general, SYST-CAT A regimens should be considered first before proceeding to treatment with SYST-CAT B regimens.

SYST-CAT A includes regimens that can often be tolerated for longer periods of time with less cumulative toxicity, less immunosuppression, and/or higher efficacy. SYST-CAT A regimens (often following initial RT) can be considered for a patient with stage IIB disease with limited tumor lesions or stage IIB generalized tumor-stage disease. SYST-CAT B includes regimens that can have more significant cumulative toxicity and



# NCCN Guidelines Version 2.2021

## Primary Cutaneous Lymphomas

are more effective for stage IIB generalized tumor disease, stage III erythrodermic disease, or stage IV disease.

Brentuximab vedotin, bexarotene, histone deacetylase (HDAC) inhibitors (vorinostat and romidepsin), methotrexate, pralatrexate, mogamulizumab, alemtuzumab, and pembrolizumab are effective systemic therapy options for patients with advanced MF and SS. Bexarotene, brentuximab vedotin, mogamulizumab, vorinostat, and romidepsin are approved by the U.S. Food and Drug Administration (FDA) for the treatment of MF and SS. The efficacy of brentuximab vedotin and mogamulizumab compared to standard therapy has been demonstrated in phase III randomized trials (ALCANZA and MAVORIC, respectively).<sup>83,84</sup> Bexarotene,<sup>85,86</sup> vorinostat,<sup>87-89</sup> romidepsin,<sup>90-92</sup> and other systemic therapies such as pralatrexate,<sup>93-95</sup> alemtuzumab,<sup>96-101</sup> and pembrolizumab<sup>102</sup> have been evaluated only in phase II studies. IFNs (alfa and gamma) and methotrexate also offer clinical benefit but have not been studied in phase II studies in the era of modern staging of MF and SS.<sup>103-105</sup>

Extracorporeal photopheresis (ECP) is an immunomodulatory therapy in which patient's leukocytes are removed by leukapheresis, treated extracorporeally with 8-methoxypsoralen and UVA, and then returned to the patient.<sup>106-108</sup> ECP may be a more appropriate systemic therapy for patients with some level of blood involvement (B1 or B2).

Gemcitabine<sup>109-112</sup> and pegylated liposomal doxorubicin<sup>113-115</sup> also have substantial activity in patients with advanced MF and SS. Multiagent chemotherapy regimens used for the treatment of systemic PTCLs have activity but are associated with greater toxicity and a potentially higher risk of death when used in earlier lines of treatment.<sup>116,117</sup> Therefore, multiagent chemotherapy regimens are generally reserved only for refractory disease to multiple prior therapies or bulky lymph node or solid organ disease, and/or as a bridge to allogeneic hematopoietic cell transplant (HCT).

Data supporting the use of systemic therapies in patients with MF and SS are discussed below.

### ***Brentuximab Vedotin***

In a phase III randomized study (ALCANZA), brentuximab vedotin (anti-CD30 antibody drug conjugate) resulted in superior clinical outcomes compared to physician's choice of methotrexate or bexarotene in patients with previously treated CD30-expressing MF. In this study, 131 patients with previously treated CD30-expressing MF and primary cutaneous anaplastic large cell lymphoma (PC-ALCL) (97 patients with MF) were randomized to receive either brentuximab vedotin or physician's choice (methotrexate or bexarotene).<sup>83</sup> At a median follow-up of 23 months, the primary endpoint, ORR lasting for  $\geq 4$  months was significantly higher for brentuximab vedotin compared to physician's choice of methotrexate or bexarotene in the intent-to-treat population (56% [16% CR] vs. 13% [2% CR];  $P < .0001$ ). Peripheral neuropathy was the most common adverse event reported in 67% of patients treated with brentuximab vedotin compared to 6% of patients in the physician's choice group.

Patients with SS were excluded from this trial and CD30 positivity was defined as CD30 expression in  $\geq 10\%$  of total lymphoid cells. However, in other phase II studies, clinical responses with brentuximab vedotin were observed across all CD30 expression levels (including negligible CD30 expression) and in patients with high blood Sézary cell count.<sup>118,119</sup> Lesions with  $< 5\%$  CD30 expression had a lower likelihood of global response than those with  $\geq 5\%$  CD30 expression ( $P < .005$ ), but responses are still seen in those with CD30 positivity of  $\geq 1\%$ .<sup>118,119</sup> While responses were observed in patients with very low or absent CD30 expression, the likelihood and/or depth of response may be lower in these situations and further studies are needed to define the activity of brentuximab in this setting. Brentuximab vedotin is a more effective treatment option than methotrexate or bexarotene for patients with CD30-positive MF but carries greater risk, particularly a cumulative risk of peripheral neuropathy.<sup>120</sup>





# NCCN Guidelines Version 2.2021

## Primary Cutaneous Lymphomas

### Systemic Retinoids

Bexarotene, an oral retinoid, can have prolonged disease control without cumulative toxicity and can often be considered for patients with higher skin burden with plaque disease.<sup>85,86</sup> In patients with stage IA–IIA disease refractory to prior treatment, bexarotene (300 mg/m<sup>2</sup>/day) was well tolerated and induced an ORR of 54%.<sup>86</sup> The rate of disease progression was 21%, and the median duration of response had not been reached at the time of the report. In patients with stages IIB–IVB disease refractory to prior treatments, bexarotene (300 mg/m<sup>2</sup>/day) induced clinical CR and PR in 45% of patients. At doses greater than 300 mg/m<sup>2</sup>/day, the ORR was 55%, including a 13% clinical CR.<sup>86</sup> It is important to note that bexarotene is associated with hypertriglyceridemia and central hypothyroidism, which necessitates laboratory monitoring for triglycerides, and free thyroxine (T4), often requiring additional management.

Retinoic-acid receptor (RAR) agonists such as all-trans retinoic acid (ATRA), acitretin, and isotretinoin (13-cis-retinoic acid) have also been shown to be effective for the treatment of early-stage MF.<sup>121-124</sup> In a retrospective comparison study, ATRA induced similar outcomes with modest single-agent activity compared to bexarotene in the treatment of patients with relapsed MF and SS.<sup>121</sup> In a small cohort of 35 patients with early-stage MF, acitretin and isotretinoin resulted in ORRs of 64% and 80%, respectively (although the CR rates were low at 4% and 8%, respectively).<sup>123</sup>

### Histone Deacetylase Inhibitors

Vorinostat was the first HDAC inhibitor to be approved for the treatment of MF and SS.<sup>88,89</sup> In the initial phase IIB registration study of 74 patients with persistent, progressive, or refractory stage IB to IVA MF and SS, vorinostat resulted in an ORR of 30% and a median time to progression (TTP) of 5 months.<sup>88</sup> Median TTP was greater than 10 months in responders with advanced disease (≥ stage IIB).<sup>88</sup> The response rates and median response durations appeared to be comparable to those obtained

with bexarotene capsules. A *post-hoc* subset analysis of patients who experienced clinical benefit with 2 or more years of vorinostat therapy in the phase IIB study provided some evidence for the long-term safety and efficacy of vorinostat in patients with heavily pretreated MF and SS, regardless of previous treatment failures.<sup>89</sup> While cumulative toxicities were rare with vorinostat, patients need to be monitored for gastrointestinal toxicity, including nausea, diarrhea, and resultant dehydration, that could be more detrimental for elderly patients.

Romidepsin has demonstrated clinical activity across all disease compartments.<sup>90-92,125</sup> In the pivotal phase IIB study of 96 patients with refractory stage IB to IVA MF and SS (71% had advanced-stage disease ≥ stage IIB), romidepsin resulted in an ORR of 34% (6% CR). Among patients with advanced stages of disease, 38% achieved an objective response (7% CR).<sup>91</sup> The median time to response was 2 months and the median duration of response was 15 months. Importantly, romidepsin was associated with a high rate of reduction in pruritus score irrespective of clinical objective response.<sup>91</sup> An updated subanalysis from this pivotal trial confirmed that romidepsin has clinical activity across all disease compartments (skin, lymph nodes, and blood; no patient with visceral involvement was enrolled in the trial).<sup>92</sup> The compartment-specific ORRs were 40%, 35%, 32%, and 27%, respectively, for skin involvement, erythroderma, blood involvement, and lymphadenopathy. It is important to initially monitor for QTc prolongation when administering romidepsin, particularly with the concomitant use of antiemetics that also prolong QTc. Romidepsin is included as a preferred regimen for patients with SS with high Sézary cell burden.

### Mogamulizumab

Mogamulizumab, a humanized anti-CCR4 monoclonal antibody, was recently approved by the FDA for the treatment of relapsed or refractory MF and SS after at least one prior systemic therapy. The approval was based on the results of a phase III randomized, open-label, multicenter



# NCCN Guidelines Version 2.2021

## Primary Cutaneous Lymphomas

trial (MAVORIC).<sup>84</sup> In this trial, 372 eligible patients with relapsed or refractory MF and SS were randomized to either mogamulizumab (n = 186) or vorinostat (n = 186). Crossover to mogamulizumab was allowed for patients with disease progression or intolerance despite dose reduction and appropriate management of side effects after at least two cycles of treatment with vorinostat. Patients could continue treatment with mogamulizumab until disease progression, drug intolerance, unacceptable toxicity, or any other criteria for treatment discontinuation were met. Mogamulizumab resulted in significantly higher investigator-assessed ORR (28% vs. 5%;  $P < .0001$ ) and superior investigator-assessed median PFS (8 months vs. 3 months;  $P < .0001$ ) compared with vorinostat, after a median follow-up of 17 months. The ORR was higher in patients with SS than in those with MF (37% vs. 21%). Among the 186 patients randomly assigned to vorinostat, 136 patients (109 patients with disease progression and 27 patients after intolerable toxicity) crossed over to mogamulizumab. The ORR was 31% for the 133 patients who crossed over from vorinostat to mogamulizumab and subsequently received mogamulizumab.

In the post-hoc subgroup analysis by clinical stage, the ORRs for mogamulizumab were higher for patients with stage III (23%) or stage IV disease (36%) than those with stage IIB (16%) or stage IB/IIA disease (19%). Mogamulizumab also resulted in higher ORR than vorinostat across all disease compartments. The compartment-specific ORRs for mogamulizumab were 42%, 68%, and 17%, respectively, for skin, blood involvement, and lymph nodes. The corresponding ORRs for vorinostat were 16%, 19%, and 4%, respectively. This trial, however, was not powered to detect OS differences between the two groups within the defined follow-up period. The most common adverse events associated with mogamulizumab were mostly grade 1–2 and manageable (infusion-related reactions [37%], skin eruptions [25%], and diarrhea [14%]). Pyrexia (4%) and cellulitis (3%) were the most common grade 3

adverse events in the mogamulizumab group. Patients with the greatest symptom burden and functional impairment derived the most benefit from mogamulizumab in terms of quality of life.<sup>126</sup>

### ***Alemtuzumab***

Alemtuzumab (a humanized anti-CD52 monoclonal antibody) has significant clinical activity in patients with previously treated advanced MF and SS.<sup>96,97,99-101</sup> The ORR with alemtuzumab (30 mg IV) was higher in patients with erythroderma or SS than those with advanced MF; however, it was associated with myelotoxicities and infectious complications.<sup>97,101</sup> Reduced-dose subcutaneous alemtuzumab (3–15 mg per administration) given for a shorter duration was equally effective with lower incidence of infectious complications in patients with SS.<sup>98</sup> While alemtuzumab is no longer commercially available, it may be obtained for compassionate use for patients with CTCL and other hematologic malignancies.

### ***Pembrolizumab***

In a phase II study of 24 patients with MF and SS (stage IIB–IV) treated with at least one prior systemic therapy, at a median follow-up of 40 weeks, pembrolizumab, an immune checkpoint inhibitor, resulted in an ORR of 38% (the ORR was slightly higher in patients with MF [56% vs. 27% for SS]) and a one-year PFS rate of 65%.<sup>102</sup> Pembrolizumab was associated with a skin flare reaction, occurring exclusively in patients with SS. The flare reaction correlated with high PD-1 expression on Sézary cells and should be distinguished from disease progression.

### ***Pralatrexate***

Pralatrexate is a folate analog with demonstrated activity in patients with heavily pretreated MF and SS.<sup>93-95</sup> In a multicenter dose-finding study that evaluated pralatrexate (10 mg/m<sup>2</sup> to 30 mg/m<sup>2</sup> given weekly for 2 of 3 weeks or 3 of 4 weeks) in 54 patients with relapsed or refractory MF and SS, the ORR for all evaluable patients was 41% (6% CR).<sup>93</sup> Among the 29 patients who received the recommended dose (15 mg/m<sup>2</sup> weekly for 3





# NCCN Guidelines Version 2.2021

## Primary Cutaneous Lymphomas

weeks of a 4-week cycle), the ORR was 45% (3% CR).<sup>93</sup> In the subgroup of patients with relapsed/refractory LCT of MF treated on the PROPEL trial, pralatrexate (30 mg/m<sup>2</sup>) resulted in an ORR of 58% (25% by independent review).<sup>94</sup> The median PFS and OS were 5 months and 13 months, respectively.

### **Gemcitabine**

Gemcitabine monotherapy is an effective treatment option resulting in an ORR of 48% to 71% in patients with heavily pretreated advanced-stage MF and SS.<sup>109-112</sup> In a retrospective observational study of 25 patients with advanced MF and SS, after a long-term follow-up of 15 years, the estimated OS, PFS, and DFS rates were 47%, 9%, and 40%, respectively.<sup>112</sup> Gemcitabine monotherapy also has demonstrated activity as front-line therapy in patients with untreated MF and SS.<sup>127</sup>

### **Liposomal Doxorubicin**

Pegylated liposomal doxorubicin has shown single-agent activity in patients with pretreated, advanced, or refractory MF and SS.<sup>113-115</sup> In a phase II EORTC multicenter trial of 49 patients with relapsed/refractory advanced MF (stage IIB, IVA, IVB) after at least two prior systemic therapies, liposomal doxorubicin resulted in an ORR of 41% (6% CR).<sup>115</sup> The median TTP was 7 months, and the median duration of response was 6 months. Pegylated liposomal doxorubicin was well tolerated with no grade 3 or 4 hematologic toxicities; the most common grade 3 or 4 toxicities included dermatologic toxicity other than hand and foot reaction (6%), constitutional symptoms (4%), gastrointestinal toxicities (4%), and infection (4%).<sup>115</sup>

### **Extracorporeal Photopheresis**

ECP has been demonstrated as an effective treatment option in many retrospective studies, resulting in an ORR of 42% to 74%.<sup>107,128-135</sup> In a meta-analysis involving more than 400 patients with MF and SS, ECP as monotherapy resulted in a 56% ORR with a 15% CR.<sup>129</sup> The

corresponding response rates were 58% (15% CR) for erythrodermic disease (T4) and 43% (10% CR) for SS. In one retrospective study of 39 patients with MF and SS (31 patients with T4 disease and 8 patients with T2 disease), ECP resulted in a skin ORR of 74% (33% of patients achieved ≥50% partial skin response and 41% of patients achieved ≥90% improvement).<sup>132</sup> After a median follow-up of 72 months, the median OS was 9 years from diagnosis and 7 years from the initiation of treatment with ECP. A more recent retrospective study of 50 patients with MF reported an ORR of 42% and an OS of 72 months with no statistically significant differences in OS among patients with early-stage and late-stage disease [77 months and 69 months, respectively;  $P = .077$ ].<sup>134</sup>

The degree of blood involvement, CD4/CD8 ratio, and amount of circulating CD3+CD8+ cells or CD4(+)CD7(-) lymphocytes have been identified as predictors of clinical response.<sup>106,107,136</sup> ECP is generally given for at least 6 months and may be more appropriate as systemic therapy for patients with or at risk of blood involvement (B1 or B2; erythrodermic stage III disease or IVA with SS).<sup>129,135</sup>

## **Combination Therapies**

### **Skin-Directed + Systemic Therapies**

Phototherapy is most commonly used in combination with either IFN<sup>137-140</sup> or systemic retinoid.<sup>124,141-144</sup>

In a prospective randomized study that evaluated IFN combined with PUVA versus IFN combined with retinoids in patients with stage I or II CTCL (n = 82 evaluable), the combination of IFN with PUVA resulted in significantly higher CR rates in this patient population (70% vs. 38%).<sup>137</sup> In another prospective phase II trial in patients with early-stage MF (stages IA–IIA; n = 89), the combination of low-dose IFN alfa with PUVA resulted in an ORR of 98% (84% CR).<sup>139</sup>



# NCCN Guidelines Version 2.2021

## Primary Cutaneous Lymphomas

In a phase III randomized study from the EORTC that evaluated the combination of bexarotene with PUVA compared with PUVA alone in patients with early-stage MF (stage IB and IIA;  $n = 93$ ), the ORR for the combination of bexarotene with PUVA was 77% (31% CR) compared to 71% (22% CR) for PUVA alone; the median duration of response was 6 months and 10 months, respectively.<sup>141</sup> A trend towards fewer PUVA sessions and lower UVA doses to achieve CR was observed with the combination arm, although the differences were not significant.<sup>141</sup> This trial was closed prematurely due to low patient accrual.

A small prospective study evaluated the combination of low-dose bexarotene in combination with PUVA maintenance in 21 patients with MF and SS (stages IB–IV) resistant or intolerant to previous therapies.<sup>142</sup> The ORR was 86% after induction therapy with bexarotene (93% for early-stage disease and 66.6% for advanced disease). At the end of maintenance, the ORR was 76% (33% CR) and the median event-free survival (EFS) for the whole group was 31 months.

In a retrospective analysis of 128 patients with MF (118 patients had early stage disease; stage  $\leq$ IIA), acitretin (either as monotherapy or in combination with phototherapy or topical steroids) resulted in an ORR of 77% (44% CR and 33% PR) with a trend towards better response rate in the combination arm compared to monotherapy.<sup>124</sup> The median duration of response was 24 months.

ECP used in combination with TSEBT or phototherapy (narrowband UVB or PUVA) has also resulted in high durable clinical response in patients with erythrodermic MF and SS.<sup>145,146</sup> In a retrospective study of 44 patients with erythrodermic MF, the combination of TSEBT with ECP (concurrent or sequential following TSEBT) significantly improved PFS compared with TSEBT alone.<sup>145</sup> The 2-year PFS and OS rates were 36% and 63%, respectively, for patients treated with TSEBT alone compared with 66% and 88% for those treated with TSEBT + ECP.

Safety of combining TSEBT with systemic retinoids or HDAC inhibitors (vorinostat or romidepsin), or combining phototherapy with vorinostat or romidepsin is unknown.

### **Systemic Combination Therapies**

The combination of ECP with IFN<sup>147-150</sup> or systemic retinoids<sup>150-152</sup> has been shown to improve response rates in patients with early-stage disease with inadequate response to single-agent therapy or for those with advanced-stage CTCL.

In a retrospective study of 47 patients with advanced CTCL, the combination of ECP with IFN and/or systemic retinoids resulted in improved response rates (84% vs. 75%) and median OS (74 months vs. 66 months) compared with ECP alone despite poor prognostic features among patients treated with combined modality therapy; however, these differences in outcomes were not statistically significant.<sup>148</sup> The median OS in the subgroup of patients with stage III or IV disease with blood involvement was 55 months. In a retrospective cohort study of patients with SS ( $n = 98$ ) who received at least 3 months of ECP combined with 1 or more biologic agents (ie, IFN alfa, systemic retinoid, IFN gamma, granulocyte-macrophage colony-stimulating factor [GM-CSF]), the ORR was 75% (30% CR) and the 5-year OS rate from time of diagnosis was 55%.<sup>149</sup> A higher monocyte percentage at baseline was significantly associated with CR rates. Most patients in this study received ECP in combination with IFN alfa (89%) and/or systemic retinoids (86%); 30% of these patients were treated with ECP combined with both IFN alfa and systemic retinoids. The 5-year OS rates for the subgroups of patients with stage IIIB, IVA1, IVA2, and IVB were 80%, 80%, 76%, and 0%, respectively.

In a study of 95 patients with MF (stages IA–IIA,  $n = 50$ ; stages IIB–IVB,  $n = 45$ ), the combination of oral isotretinoin and IFN alfa (followed by TSEBT and long-term maintenance therapy with topical mechlorethamine and IFN



# NCCN Guidelines Version 2.2021

## Primary Cutaneous Lymphomas

alfa) resulted in an ORR of 85% (60% CR).<sup>151</sup> The CR rate was 76% among patients with early-stage MF (remission duration >5 years in 24% of responders) and 40% among those with advanced-stage disease (remission duration >5 years in 17%). The median DFS and OS rates for patients with early-stage disease were 62 months and 145 months, respectively. The corresponding endpoints for patients with advanced-stage disease were 7 months and 36 months, respectively. The 5-year estimated OS rate was 94% for patients with early-stage and 35% for advanced-stage MF. Disease stage was the only independent prognostic factor for survival based on multivariate analysis.

In a phase II study of 22 patients with CTCL, oral bexarotene in combination with IFN alfa (added in cases of <CR after 8 weeks of bexarotene alone) resulted in an ORR of 39% (6% CR). Although the regimen was well tolerated, response rates were not improved relative to the ORR expected with bexarotene alone.<sup>152</sup>

In another phase II study that evaluated pegylated liposomal doxorubicin followed sequentially by oral bexarotene in 37 patients with advanced-stage or refractory MF and SS, treatment with 8 doses (16 weeks) of liposomal doxorubicin resulted in an ORR of 41% including clinical CR in 2 patients with a median PFS of 5 months.<sup>153</sup> The maximum response was observed after 16 weeks of treatment with liposomal doxorubicin; sequential bexarotene did not improve the response rate or duration.

### Additional Therapy Based on Response to Primary Treatment

Historically, the response criteria for MF and SS were poorly defined and validated response assessments were lacking. Response criteria for MF and SS have not been demonstrated to correlate with prognosis, and responses can vary between the different disease compartments (ie, skin, blood, lymph nodes).

More recent studies have incorporated consensus response assessments and newer FDA-approved agents have undergone central review for efficacy outcomes. A proposal for the standardization of definition of response in skin, nodes, blood, and viscera has been published.<sup>154</sup> The decisions to continue with or switch treatment regimens are often made based on clinical parameters. Imaging with the same modalities used in workup is indicated when there is suspicion of disease progression or extracutaneous disease.

All patients (stage IA–IV) with a clinical benefit and/or those with disease responding to primary treatment should be considered for maintenance or tapering of regimens to optimize response duration. Disease relapse (with the same stage) after discontinuation of therapy often responds well to re-treatment with previous therapy. Patients with persistent disease following completion of primary treatment should be treated with the other primary treatment options not received before to improve response before moving onto treatment for refractory disease.

Currently there is no definitive treatment for refractory disease that can produce reliable durable remissions or curative results. Participation in a clinical trial is recommended for all patients with refractory disease. Multiagent chemotherapy regimens recommended for PTCL are appropriate for the management of refractory disease to multiple prior therapies.

### Special Considerations for Clinical Situations with Specific Pathologic Features

#### *Folliculotropic Mycosis Fungoides*

FMF is characterized by the infiltration of hair follicles by atypical T lymphocytes and resultant alopecia. Disease typically presents as plaques and tumors mainly on the head/neck and the risk profile varies with stage of the disease.<sup>20,155–158</sup> Recent studies have reported that FMF presents with two distinct patterns of clinicopathologic features with different



# NCCN Guidelines Version 2.2021

## Primary Cutaneous Lymphomas

prognostic implications (early stage and advanced stage); in a subgroup of patients with early skin-limited disease, FMF has an indolent disease course and a favorable prognosis, with early-stage cutaneous disease associated with significantly higher disease-specific survival compared to advanced-stage cutaneous disease.<sup>159-161</sup>

In a report from the Dutch Cutaneous Lymphoma Group that evaluated the treatment outcomes in patients with FMF (203 patients; 84 patients with early-stage FMF, 102 patients with advanced-stage FMF, and 17 patients with extracutaneous FMF), treatment with topical steroids and phototherapy with UVB or PUVA were more effective in patients with early-stage FMF resulting in an ORR of 83% (28% CR), 83%, and 88%, respectively.<sup>162</sup> Local RT, TSEBT, and PUVA combined with RT were more effective in patients with advanced-stage FMF resulting in an ORR of 100% (63% CR), 100% (59% CR), and 75% (5% CR), respectively.

Patients with early-stage FMF may benefit from standard skin-directed therapies used for the treatment of early-stage MF, and those with generalized indolent/plaque FMF (without evidence of LCT) should initially be considered for options under SYST-CAT A before proceeding to options listed under SYST-CAT B.

### ***Large-Cell Transformed Mycosis Fungoides***

LCT is diagnosed when large cells are present in greater than 25% of lymphoid/tumor cell infiltrates in a skin lesion biopsy, and the incidence of LCT is strongly dependent on the disease stage at diagnosis (1% for early-stage disease, compared with 27% for stage IIB disease and 56%–67% for stage IV disease).<sup>7-9</sup> LCT is often, but not always, aggressive. CD30 expression is associated with LCT in MF or SS in 30% to 50% of cases, and this finding may have potential implications for CD30-directed therapies.<sup>7-9,163</sup> However, it should be noted that CD30 expression is variable in MF and SS, with the leukemic Sézary cells typically being CD30-negative.

Systemic therapy (brentuximab vedotin, gemcitabine, liposomal doxorubicin, pralatrexate, or romidepsin) with or without skin-directed therapies is the initial treatment for generalized cutaneous or extracutaneous lesions with LCT. In addition, concurrent management of coexisting disease based on clinical stage is recommended. Selected patients with localized LCT (ie, restricted to one or few T3 lesions or stage IA–IIA plaque disease) could be treated with EBRT alone, with continuation of other treatment modalities used prior to transformation. Depending on the goals of treatment, multiagent chemotherapy regimens recommended for PTCL may be appropriate for the management of LCT that is refractory to multiple prior therapies or when significant extracutaneous disease is present.

### **Role of Allogeneic Hematopoietic Cell Transplant in MFSS**

Allogeneic HCT has a role in a subset of patients with advanced-stage MF and SS who have received multiple lines of therapy as shown in retrospective studies and small prospective series of patients with advanced MF and SS.<sup>164-168</sup>

In a multicenter retrospective analysis of 37 patients with advanced-stage primary CTCL treated with allogeneic HCT (24 patients [65%] had stage IV MFSS or disseminated nodal or visceral involvement), after a median follow-up of 29 months, the incidence of relapse was 56% and the estimated 2-year OS and PFS rates were 57% and 31%, respectively.<sup>164</sup>

In a retrospective analysis of patients with advanced-stage MF and SS in the European Group for Blood and Marrow Transplantation (EBMT) database (n = 60) treated with allogeneic HCT, the 5-year PFS and OS rates were 32% and 46%, respectively. The corresponding 7-year survival rates were 44% and 30%, respectively.<sup>165</sup> The non-relapse mortality (NRM) rate at 7 years was 22%. Outcomes were not significantly different between histology types. However, patients with advanced-stage disease





# NCCN Guidelines Version 2.2021

## Primary Cutaneous Lymphomas

had an increased risk of relapse or progression as well as lower PFS, and myeloablative conditioning was associated with poorer NRM and OS. In addition, transplants from unrelated donors had a statistically borderline impact on NRM and a significantly lower PFS as well as OS. In a case series of 47 patients with advanced-stage MF and SS who underwent allogeneic HCT after failure of standard therapy, the estimated 4-year OS and PFS rates were 51% and 26%, respectively.<sup>167</sup> While there was no statistical difference in the OS in patients who had MF without LCT, SS, MF with LCT, or SS with LCT, the 4-year PFS rate was superior in patients who had SS versus those who did not (52% vs. 10%;  $P = .02$ ). Recent systematic review and meta-analysis have reported pooled PFS and OS rates of 36% and 59%, respectively.<sup>169,170</sup> Autologous HCT is not recommended for patients with CTCL, due to short duration of response despite its toxicity, thus limiting its utility.<sup>171</sup>

While the majority of the deaths among patients undergoing autologous HCT may be attributable to PD, deaths associated with allogeneic HCT may be more due to NRM. The incidence of 1-year NRM in published reports with allogeneic HCT is about 11% to 25%.<sup>164-168</sup> The use of TSEBT with non-myeloablative allogeneic HCT has also been evaluated in patients with advanced MF and SS.<sup>172-175</sup> In a study of 19 patients with advanced CTCL, the use of TSEBT prior to allogeneic HCT provided improved disease control with an ORR of 68% (58% CR) with median OS not reached at the time of the report; the treatment related mortality (TRM) rate was 21%.<sup>172</sup> The most recent data comes from a prospective clinical study that evaluated a non-myeloablative conditioning regimen consisting of TSEBT, total lymphoid irradiation (TLI) + anti-thymocyte globulin (ATG) in 35 patients with advanced stage disease (13 patients with MF and 22 patients with SS). This regimen was associated with 1-year and 2-year NRM of 3% and 14%, respectively. The 2-year incidence of moderate/severe chronic GVHD was 32%. With a median posttransplant follow-up of 5 years, the 2-year, 3-year, and 5-year OS rates were 68%,

62%, and 56%, respectively. The 5-year PFS rate was 41%. Patients aged >65 years at the time of transplant had similar clinical outcomes compared with younger patients. This study also evaluated the utilization of HTS to monitor minimal residual disease (MRD) and molecular remission after allogeneic HCT (achieved in 43% of patients) was associated with a lower incidence of progressive disease or relapse.

Allogeneic HCT may be considered for appropriate patients with stage IIB–IV disease that is refractory to multiple primary treatment options. Based on the limited evidence, patients with erythrodermic MF and SS appear to receive the most benefit from allogeneic HCT, despite high post-transplant relapse rate. Allogeneic HCT is generally reserved for patients with systemic disease and/or extensive skin involvement that is refractory to or progressive after multiple lines of systemic therapy options. When appropriate, TSEBT may be considered as cytoreductive therapy before transplant.<sup>172,173</sup> Novel conditioning regimens are being explored to provide improved disease control while limiting transplant-related complications.

The ideal timing for allogeneic HCT is when the disease is well controlled with induction therapy and before the disease has progressed to a state where the chance of response or survival with allogeneic HCT is low.<sup>176</sup> A transplant decision requires careful counseling to weigh the significant risks of this procedure versus the likelihood of long-term benefits and availability of alternate treatments.

### Supportive Care

#### *Management of Pruritus*

Symptoms of pruritus can be present in a large majority (nearly 90%) of patients with CTCL, and may be associated with decreased quality of life for patients.<sup>177-179</sup> Patients should be evaluated for pruritus at each visit. Other potential causes of pruritus (eg, contact dermatitis, atopic dermatitis, psoriasis, other inflammatory skin conditions) should be ruled out. The





# NCCN Guidelines Version 2.2021

## Primary Cutaneous Lymphomas

extent of pruritus (localized vs. generalized) and potential correlation between disease site and localization of pruritus should be noted.

The treatment of pruritus requires optimizing skin-directed and systemic treatments. Daily use of moisturizers and emollients are helpful in maintaining and protecting the skin barrier. Topical steroids (with or without occlusion) can be effective in managing the disease and accompanying pruritus in early-stage disease.<sup>179,180</sup> First-line options include H1 antihistamines (single-agent or combination of antihistamines from different classes) or the anticonvulsant gabapentin.<sup>177,181,182</sup> Neurokinin-1 (NK-1) receptor antagonist aprepitant,<sup>183-185</sup> the tetracyclic antidepressant mirtazapine, or selective serotonin reuptake inhibitors (SSRIs) may be considered in the second-line setting.<sup>186,187</sup> Treatment with the oral opioid receptor antagonist naltrexone may be considered if symptoms of pruritus do not resolve with the above agents.<sup>188</sup>

### **Prevention and Treatment of Infections**

Infectious complications are frequent among patients with MF and SS, particularly cutaneous bacterial infections and cutaneous herpes viral infections (eg, herpes simplex virus [HSV] or herpes zoster virus [HZV] infections).<sup>189</sup> Bacteremia/sepsis and bacterial pneumonia were reported as the major cause of death due to infections in a retrospective cohort study of patients with MF and SS.<sup>189</sup> Several preventive measures such as maintaining/protecting the skin barrier (routine use of skin moisturizers and/or emollients), bleach baths or soaks (for limited areas only), avoidance of central lines (particularly for erythrodermic patients), and prophylactic use of mupirocin in cases of *Staphylococcus aureus* (*S. aureus*) colonization can be incorporated to minimize infectious complications. HSV prophylaxis with acyclovir or equivalent should be

considered for patients with frequent recurrence of HSV infection. Patients undergoing treatment with alemtuzumab-containing regimens should be closely monitored for cytomegalovirus (CMV) reactivation and preemptively treated with antivirals to avoid overt CMV disease.

Cultures from skin swab and nares (nostrils) should be taken to evaluate for *S. aureus* colonization/infection in patients with erythroderma and an active or suspected infection. Antimicrobial treatments may include intranasal mupirocin and/or oral dicloxacillin or cephalexin. Bleach baths or soaks may be helpful if the affected area is limited. Doxycycline or trimethoprim/sulfamethoxazole (TMP/SMX) should be considered for patients with suspected methicillin-resistant *Staphylococcus aureus* (MRSA) infection. If no improvements in infection status are observed with the above agents, or if bacteremia is suspected, vancomycin should be initiated.

Infection with Gram-negative rods is common in necrotic tumors, and may lead to serious complications such as bacteremia/sepsis. For active or suspected infections in patients with ulcerated and necrotic tumors, blood cultures should be obtained and empiric therapy with antibacterials should be considered even in the absence of a fever. An antimicrobial agent with broad-spectrum coverage (including coverage for both Gram-negative rods and Gram-positive cocci) should be chosen initially. The role of skin/wound culture is not clear in this setting.

Further information on empiric therapy in cancer patients at risk for infections is included in the NCCN Guidelines for the Prevention and Treatment of Cancer-Related Infections (available at [www.NCCN.org](http://www.NCCN.org)).



# NCCN Guidelines Version 2.2021

## Primary Cutaneous Lymphomas

### References

1. Bradford PT, Devesa SS, Anderson WF, Toro JR. Cutaneous lymphoma incidence patterns in the United States: a population-based study of 3884 cases. *Blood* 2009;113:5064-5073. Available at: <https://www.ncbi.nlm.nih.gov/pubmed/19279331>.
2. Willemze R, Cerroni L, Kempf W, et al. The 2018 update of the WHO-EORTC classification for primary cutaneous lymphomas. *Blood* 2019;133:1703-1714. Available at: <https://www.ncbi.nlm.nih.gov/pubmed/30635287>.
3. Teras LR, DeSantis CE, Cerhan JR, et al. 2016 US lymphoid malignancy statistics by World Health Organization subtypes. *CA Cancer J Clin* 2016;66:443-459. Available at: <https://www.ncbi.nlm.nih.gov/pubmed/27618563>.
4. Pimpinelli N, Olsen EA, Santucci M, et al. Defining early mycosis fungoides. *J Am Acad Dermatol* 2005;53:1053-1063. Available at: <https://www.ncbi.nlm.nih.gov/pubmed/16310068>.
5. Campbell JJ, Clark RA, Watanabe R, Kupper TS. Sezary syndrome and mycosis fungoides arise from distinct T-cell subsets: a biologic rationale for their distinct clinical behaviors. *Blood* 2010;116:767-771. Available at: <https://www.ncbi.nlm.nih.gov/pubmed/20484084>.
6. Olsen EA, Rook AH, Zic J, et al. Sezary syndrome: immunopathogenesis, literature review of therapeutic options, and recommendations for therapy by the United States Cutaneous Lymphoma Consortium (USCLC). *J Am Acad Dermatol* 2011;64:352-404. Available at: <https://www.ncbi.nlm.nih.gov/pubmed/21145619>.
7. Diamandidou E, Colome-Grimmer M, Fayad L, et al. Transformation of mycosis fungoides/Sezary syndrome: clinical characteristics and prognosis. *Blood* 1998;92:1150-1159. Available at: <https://www.ncbi.nlm.nih.gov/pubmed/9694702>.
8. Vergier B, de Muret A, Beylot-Barry M, et al. Transformation of mycosis fungoides: clinicopathological and prognostic features of 45 cases. *French Study Group of Cutaneous Lymphomas. Blood* 2000;95:2212-2218. Available at: <https://www.ncbi.nlm.nih.gov/pubmed/10733487>.
9. Arulogun SO, Prince HM, Ng J, et al. Long-term outcomes of patients with advanced-stage cutaneous T-cell lymphoma and large cell transformation. *Blood* 2008;112:3082-3087. Available at: <https://www.ncbi.nlm.nih.gov/pubmed/18647960>.
10. Choi J, Goh G, Walradt T, et al. Genomic landscape of cutaneous T cell lymphoma. *Nat Genet* 2015;47:1011-1019. Available at: <https://www.ncbi.nlm.nih.gov/pubmed/26192916>.
11. Kann BH, Park HS, Yeboa DN, et al. Annual Facility Treatment Volume and Patient Survival for Mycosis Fungoides and Sezary Syndrome. *Clin Lymphoma Myeloma Leuk* 2017;17:520-526 e522. Available at: <https://www.ncbi.nlm.nih.gov/pubmed/28655598>.
12. U.S. National Library of Medicine Key MEDLINE® Indicators Available at: [http://www.nlm.nih.gov/bsd/bsd\\_key.html](http://www.nlm.nih.gov/bsd/bsd_key.html).
13. Olsen E, Vonderheid E, Pimpinelli N, et al. Revisions to the staging and classification of mycosis fungoides and Sezary syndrome: a proposal of the International Society for Cutaneous Lymphomas (ISCL) and the cutaneous lymphoma task force of the European Organization of Research and Treatment of Cancer (EORTC). *Blood* 2007;110:1713-1722. Available at: <https://www.ncbi.nlm.nih.gov/pubmed/17540844>.
14. de Coninck EC, Kim YH, Varghese A, Hoppe RT. Clinical characteristics and outcome of patients with extracutaneous mycosis fungoides. *J Clin Oncol* 2001;19:779-784. Available at: <https://www.ncbi.nlm.nih.gov/pubmed/11157031>.
15. Kim YH, Liu HL, Mraz-Gernhard S, et al. Long-term outcome of 525 patients with mycosis fungoides and Sezary syndrome: clinical prognostic factors and risk for disease progression. *Arch Dermatol* 2003;139:857-866. Available at: <https://www.ncbi.nlm.nih.gov/pubmed/12873880>.



# NCCN Guidelines Version 2.2021

## Primary Cutaneous Lymphomas

16. Vidulich KA, Talpur R, Bassett RL, Duvic M. Overall survival in erythrodermic cutaneous T-cell lymphoma: an analysis of prognostic factors in a cohort of patients with erythrodermic cutaneous T-cell lymphoma. *Int J Dermatol* 2009;48:243-252. Available at: <https://www.ncbi.nlm.nih.gov/pubmed/19261011>.

17. Agar NS, Wedgeworth E, Crichton S, et al. Survival outcomes and prognostic factors in mycosis fungoides/Sezary syndrome: validation of the revised International Society for Cutaneous Lymphomas/European Organisation for Research and Treatment of Cancer staging proposal. *J Clin Oncol* 2010;28:4730-4739. Available at: <https://www.ncbi.nlm.nih.gov/pubmed/20855822>.

18. Talpur R, Singh L, Daulat S, et al. Long-term outcomes of 1,263 patients with mycosis fungoides and Sezary syndrome from 1982 to 2009. *Clin Cancer Res* 2012;18:5051-5060. Available at: <https://www.ncbi.nlm.nih.gov/pubmed/22850569>.

19. Alberti-Violetti S, Talpur R, Schlichte M, et al. Advanced-stage mycosis fungoides and Sezary syndrome: survival and response to treatment. *Clin Lymphoma Myeloma Leuk* 2015;15:e105-112. Available at: <https://www.ncbi.nlm.nih.gov/pubmed/25817937>.

20. Scarisbrick JJ, Prince HM, Vermeer MH, et al. Cutaneous Lymphoma International Consortium Study of Outcome in Advanced Stages of Mycosis Fungoides and Sezary Syndrome: Effect of Specific Prognostic Markers on Survival and Development of a Prognostic Model. *J Clin Oncol* 2015;33:3766-3773. Available at: <https://www.ncbi.nlm.nih.gov/pubmed/26438120>.

21. Scarisbrick JJ, Quaglino P, Prince HM, et al. The PROCLIP international registry of early-stage mycosis fungoides identifies substantial diagnostic delay in most patients. *Br J Dermatol* 2019;181:350-357. Available at: <https://www.ncbi.nlm.nih.gov/pubmed/30267549>.

22. Hodak E, Sherman S, Papadavid E, et al. Should we be imaging lymph nodes at initial diagnosis of early-stage mycosis fungoides? Results from the PROSpective Cutaneous Lymphoma International Prognostic

Index (PROCLIP) international study. *Br J Dermatol* 2020. Available at: <https://www.ncbi.nlm.nih.gov/pubmed/32574377>.

23. Quaglino P, Prince HM, Cowan R, et al. Treatment of early-stage mycosis fungoides: results from the PROSpective Cutaneous Lymphoma International Prognostic Index (PROCLIP) study. *Br J Dermatol* 2020. Available at: <https://www.ncbi.nlm.nih.gov/pubmed/32479678>.

24. Kim EJ, Hess S, Richardson SK, et al. Immunopathogenesis and therapy of cutaneous T cell lymphoma. *J Clin Invest* 2005;115:798-812. Available at: <https://www.ncbi.nlm.nih.gov/pubmed/15841167>.

25. Battistella M, Beylot-Barry M, Bachelez H, et al. Primary cutaneous follicular helper T-cell lymphoma: a new subtype of cutaneous T-cell lymphoma reported in a series of 5 cases. *Arch Dermatol* 2012;148:832-839. Available at: <https://www.ncbi.nlm.nih.gov/pubmed/22508770>.

26. Wang JY, Nguyen GH, Ruan J, Magro CM. Primary Cutaneous Follicular Helper T-Cell Lymphoma: A Case Series and Review of the Literature. *Am J Dermatopathol* 2017;39:374-383. Available at: <https://www.ncbi.nlm.nih.gov/pubmed/28375859>.

27. Bosisio FM, Cerroni L. Expression of T-follicular helper markers in sequential biopsies of progressive mycosis fungoides and other primary cutaneous T-cell lymphomas. *Am J Dermatopathol* 2015;37:115-121. Available at: <https://www.ncbi.nlm.nih.gov/pubmed/25406852>.

28. Park JH, Han JH, Kang HY, et al. Expression of follicular helper T-cell markers in primary cutaneous T-cell lymphoma. *Am J Dermatopathol* 2014;36:465-470. Available at: <https://www.ncbi.nlm.nih.gov/pubmed/24162385>.

29. Thurber SE, Zhang B, Kim YH, et al. T-cell clonality analysis in biopsy specimens from two different skin sites shows high specificity in the diagnosis of patients with suggested mycosis fungoides. *J Am Acad Dermatol* 2007;57:782-790. Available at: <https://www.ncbi.nlm.nih.gov/pubmed/17646032>.



# NCCN Guidelines Version 2.2021

## Primary Cutaneous Lymphomas

30. Zhang B, Beck AH, Taube JM, et al. Combined use of PCR-based TCRG and TCRB clonality tests on paraffin-embedded skin tissue in the differential diagnosis of mycosis fungoides and inflammatory dermatoses. *J Mol Diagn* 2010;12:320-327. Available at: <https://www.ncbi.nlm.nih.gov/pubmed/20203005>.

31. Kirsch IR, Watanabe R, O'Malley JT, et al. TCR sequencing facilitates diagnosis and identifies mature T cells as the cell of origin in CTCL. *Sci Transl Med* 2015;7:308ra158. Available at: <https://www.ncbi.nlm.nih.gov/pubmed/26446955>.

32. de Masson A, O'Malley JT, Elco CP, et al. High-throughput sequencing of the T cell receptor beta gene identifies aggressive early-stage mycosis fungoides. *Sci Transl Med* 2018;10. Available at: <https://www.ncbi.nlm.nih.gov/pubmed/29743350>.

33. Horna P, Wang SA, Wolniak KL, et al. Flow cytometric evaluation of peripheral blood for suspected Sezary syndrome or mycosis fungoides: International guidelines for assay characteristics. *Cytometry B Clin Cytom* 2020. Available at: <https://www.ncbi.nlm.nih.gov/pubmed/32319723>.

34. Tsai EY, Taur A, Espinosa L, et al. Staging accuracy in mycosis fungoides and sezary syndrome using integrated positron emission tomography and computed tomography. *Arch Dermatol* 2006;142:577-584. Available at: <https://www.ncbi.nlm.nih.gov/pubmed/16702495>.

35. Zackheim HS, Kashani-Sabet M, Amin S. Topical corticosteroids for mycosis fungoides. Experience in 79 patients. *Arch Dermatol* 1998;134:949-954. Available at: <https://www.ncbi.nlm.nih.gov/pubmed/9722724>.

36. Zackheim HS. Treatment of patch-stage mycosis fungoides with topical corticosteroids. *Dermatol Ther* 2003;16:283-287. Available at: <https://www.ncbi.nlm.nih.gov/pubmed/14686970>.

37. Kartan S, Shalabi D, O'Donnell M, et al. Response to topical corticosteroid monotherapy in mycosis fungoides. *J Am Acad Dermatol*

2021;84:615-623. Available at: <https://www.ncbi.nlm.nih.gov/pubmed/32428610>.

38. Kim YH, Martinez G, Varghese A, Hoppe RT. Topical nitrogen mustard in the management of mycosis fungoides: update of the Stanford experience. *Arch Dermatol* 2003;139:165-173. Available at: <https://www.ncbi.nlm.nih.gov/pubmed/12588222>.

39. Lessin SR, Duvic M, Guitart J, et al. Topical chemotherapy in cutaneous T-cell lymphoma: positive results of a randomized, controlled, multicenter trial testing the efficacy and safety of a novel mechlorethamine, 0.02%, gel in mycosis fungoides. *JAMA Dermatol* 2013;149:25-32. Available at: <https://www.ncbi.nlm.nih.gov/pubmed/23069814>.

40. Breneman D, Duvic M, Kuzel T, et al. Phase 1 and 2 trial of bexarotene gel for skin-directed treatment of patients with cutaneous T-cell lymphoma. *Arch Dermatol* 2002;138:325-332. Available at: <https://www.ncbi.nlm.nih.gov/pubmed/11902983>.

41. Heald P, Mehlmauer M, Martin AG, et al. Topical bexarotene therapy for patients with refractory or persistent early-stage cutaneous T-cell lymphoma: results of the phase III clinical trial. *J Am Acad Dermatol* 2003;49:801-815. Available at: <https://www.ncbi.nlm.nih.gov/pubmed/14576658>.

42. Apisarnthanarax N, Talpur R, Ward S, et al. Tazarotene 0.1% gel for refractory mycosis fungoides lesions: an open-label pilot study. *J Am Acad Dermatol* 2004;50:600-607. Available at: <https://www.ncbi.nlm.nih.gov/pubmed/15034511>.

43. Besner Morin C, Roberge D, Turchin I, et al. Tazarotene 0.1% Cream as Monotherapy for Early-Stage Cutaneous T-Cell Lymphoma. *J Cutan Med Surg* 2016;20:244-248. Available at: <https://www.ncbi.nlm.nih.gov/pubmed/26742957>.

44. Deeths MJ, Chapman JT, Dellavalle RP, et al. Treatment of patch and plaque stage mycosis fungoides with imiquimod 5% cream. *J Am Acad*





# NCCN Guidelines Version 2.2021

## Primary Cutaneous Lymphomas

Dermatol 2005;52:275-280. Available at:  
<https://www.ncbi.nlm.nih.gov/pubmed/15692473>.

45. Coors EA, Schuler G, Von Den Driesch P. Topical imiquimod as treatment for different kinds of cutaneous lymphoma. Eur J Dermatol 2006;16:391-393. Available at:  
<https://www.ncbi.nlm.nih.gov/pubmed/16935796>.

46. Martinez-Gonzalez MC, Vereas-Hernando MM, Yebra-Pimentel MT, et al. Imiquimod in mycosis fungoides. Eur J Dermatol 2008;18:148-152. Available at: <https://www.ncbi.nlm.nih.gov/pubmed/18424373>.

47. Lewis DJ, Byekova YA, Emge DA, Duvic M. Complete resolution of mycosis fungoides tumors with imiquimod 5% cream: a case series. J Dermatol Treat 2017;28:567-569. Available at:  
<https://www.ncbi.nlm.nih.gov/pubmed/28635518>.

48. Zackheim HS. Topical carmustine (BCNU) for patch/plaque mycosis fungoides. Semin Dermatol 1994;13:202-206. Available at:  
<https://www.ncbi.nlm.nih.gov/pubmed/7986689>.

49. Zackheim HS. Topical carmustine (BCNU) in the treatment of mycosis fungoides. Dermatol Ther 2003;16:299-302. Available at:  
<https://www.ncbi.nlm.nih.gov/pubmed/14686972>.

50. Piccinno R, Caccialanza M, Cuka E, Recalcati S. Localized conventional radiotherapy in the treatment of Mycosis Fungoides: our experience in 100 patients. J Eur Acad Dermatol Venereol 2014;28:1040-1044. Available at:  
<https://www.ncbi.nlm.nih.gov/pubmed/23998331>.

51. Specht L, Dabaja B, Illidge T, et al. Modern radiation therapy for primary cutaneous lymphomas: field and dose guidelines from the International Lymphoma Radiation Oncology Group. Int J Radiat Oncol Biol Phys 2015;92:32-39. Available at:  
<https://www.ncbi.nlm.nih.gov/pubmed/25863751>.

52. Neelis KJ, Schimmel EC, Vermeer MH, et al. Low-dose palliative radiotherapy for cutaneous B- and T-cell lymphomas. Int J Radiat Oncol

Biol Phys 2009;74:154-158. Available at:  
<https://www.ncbi.nlm.nih.gov/pubmed/18834672>.

53. Thomas TO, Agrawal P, Guitart J, et al. Outcome of patients treated with a single-fraction dose of palliative radiation for cutaneous T-cell lymphoma. Int J Radiat Oncol Biol Phys 2013;85:747-753. Available at:  
<https://www.ncbi.nlm.nih.gov/pubmed/22818412>.

54. Ysebaert L, Truc G, Dalac S, et al. Ultimate results of radiation therapy for T1-T2 mycosis fungoides (including reirradiation). Int J Radiat Oncol Biol Phys 2004;58:1128-1134. Available at:  
<https://www.ncbi.nlm.nih.gov/pubmed/15001254>.

55. Harrison C, Young J, Navi D, et al. Revisiting low-dose total skin electron beam therapy in mycosis fungoides. Int J Radiat Oncol Biol Phys 2011;81:e651-657. Available at:  
<https://www.ncbi.nlm.nih.gov/pubmed/21489711>.

56. Navi D, Riaz N, Levin YS, et al. The Stanford University experience with conventional-dose, total skin electron-beam therapy in the treatment of generalized patch or plaque (T2) and tumor (T3) mycosis fungoides. Arch Dermatol 2011;147:561-567. Available at:  
<https://www.ncbi.nlm.nih.gov/pubmed/21576575>.

57. Elsayad K, Kriz J, Moustakis C, et al. Total Skin Electron Beam for Primary Cutaneous T-cell Lymphoma. Int J Radiat Oncol Biol Phys 2015;93:1077-1086. Available at:  
<https://www.ncbi.nlm.nih.gov/pubmed/26581145>.

58. Kamstrup MR, Lindahl LM, Gniadecki R, et al. Low-dose total skin electron beam therapy as a debulking agent for cutaneous T-cell lymphoma: an open-label prospective phase II study. Br J Dermatol 2012;166:399-404. Available at:  
<https://www.ncbi.nlm.nih.gov/pubmed/21967035>.

59. Hoppe RT, Harrison C, Tavallaei M, et al. Low-dose total skin electron beam therapy as an effective modality to reduce disease burden in patients with mycosis fungoides: results of a pooled analysis from 3





# NCCN Guidelines Version 2.2021

## Primary Cutaneous Lymphomas

phase-II clinical trials. J Am Acad Dermatol 2015;72:286-292. Available at: <https://www.ncbi.nlm.nih.gov/pubmed/25476993>.

60. Kamstrup MR, Gniadecki R, Iversen L, et al. Low-dose (10-Gy) total skin electron beam therapy for cutaneous T-cell lymphoma: an open clinical study and pooled data analysis. Int J Radiat Oncol Biol Phys 2015;92:138-143. Available at: <https://www.ncbi.nlm.nih.gov/pubmed/25863761>.

61. Kroeger K, Elsayad K, Moustakis C, et al. Low-dose total skin electron beam therapy for cutaneous lymphoma : Minimal risk of acute toxicities. Strahlenther Onkol 2017;193:1024-1030. Available at: <https://www.ncbi.nlm.nih.gov/pubmed/28785772>.

62. Morris S, Scarisbrick J, Frew J, et al. The Results of Low-Dose Total Skin Electron Beam Radiation Therapy (TSEB) in Patients With Mycosis Fungoides From the UK Cutaneous Lymphoma Group. Int J Radiat Oncol Biol Phys 2017;99:627-633. Available at: <https://www.ncbi.nlm.nih.gov/pubmed/28843374>.

63. Georgakopoulos I, Papadavid E, Platoni K, et al. Low dose total skin electron beam therapy for the management of T cell cutaneous lymphomas. Dermatol Ther 2020;33:e13478. Available at: <https://www.ncbi.nlm.nih.gov/pubmed/32391976>.

64. Song A, Gochoco A, Zhan T, et al. A prospective cohort study of condensed low-dose total skin electron beam therapy for mycosis fungoides: Reduction of disease burden and improvement in quality of life. J Am Acad Dermatol 2020;83:78-85. Available at: <https://www.ncbi.nlm.nih.gov/pubmed/32004646>.

65. Elsayad K, Kroeger K, Greve B, et al. Low-dose total skin electron beam therapy: Quality of life improvement and clinical impact of maintenance and adjuvant treatment in patients with mycosis fungoides or Sezary syndrome. Strahlenther Onkol 2020;196:77-84. Available at: <https://www.ncbi.nlm.nih.gov/pubmed/31591658>.

66. Kudelka MR, Switchenko JM, Lechowicz MJ, et al. Maintenance Therapy for Cutaneous T-cell Lymphoma After Total Skin Electron

Irradiation: Evidence for Improved Overall Survival With Ultraviolet Therapy. Clin Lymphoma Myeloma Leuk 2020;20:757-767 e753. Available at: <https://www.ncbi.nlm.nih.gov/pubmed/32703750>.

67. Gathers RC, Scherschun L, Malick F, et al. Narrowband UVB phototherapy for early-stage mycosis fungoides. J Am Acad Dermatol 2002;47:191-197. Available at: <https://www.ncbi.nlm.nih.gov/pubmed/12140464>.

68. Dereure O, Picot E, Comte C, et al. Treatment of early stages of mycosis fungoides with narrowband ultraviolet B. A clinical, histological and molecular evaluation of results. Dermatology 2009;218:1-6. Available at: <https://www.ncbi.nlm.nih.gov/pubmed/18832806>.

69. Gokdemir G, Barutcuoglu B, Sakiz D, Koslu A. Narrowband UVB phototherapy for early-stage mycosis fungoides: evaluation of clinical and histopathological changes. J Eur Acad Dermatol Venereol 2006;20:804-809. Available at: <https://www.ncbi.nlm.nih.gov/pubmed/16898902>.

70. Drucker AM, Baibergenova A, Rosen CF, Shear NH. Narrowband UVB as an effective substitute for psoralen plus UVA: lessons from a psoralen shortage. Photodermatol Photoimmunol Photomed 2012;28:267-268. Available at: <https://www.ncbi.nlm.nih.gov/pubmed/22971194>.

71. Elcin G, Duman N, Karahan S, et al. Long-term follow-up of early mycosis fungoides patients treated with narrowband ultraviolet B phototherapy. J Dermatolog Treat 2014;25:268-273. Available at: <https://www.ncbi.nlm.nih.gov/pubmed/23030414>.

72. Querfeld C, Rosen ST, Kuzel TM, et al. Long-term follow-up of patients with early-stage cutaneous T-cell lymphoma who achieved complete remission with psoralen plus UV-A monotherapy. Arch Dermatol 2005;141:305-311. Available at: <https://www.ncbi.nlm.nih.gov/pubmed/15781671>.

73. Pavlotsky F, Hodak E, Ben Amitay D, Barzilai A. Role of bath psoralen plus ultraviolet A in early-stage mycosis fungoides. J Am Acad Dermatol



# NCCN Guidelines Version 2.2021

## Primary Cutaneous Lymphomas

2014;71:536-541. Available at:  
<https://www.ncbi.nlm.nih.gov/pubmed/24836546>.

74. Amitay-Laish I, Prag-Naveh H, Dalal A, et al. Treatment of Early Folliculotropic Mycosis Fungoides with Special Focus on Psoralen plus Ultraviolet A. *Acta Derm Venereol* 2018;98:951-955. Available at:  
<https://www.ncbi.nlm.nih.gov/pubmed/30085321>.

75. Vieyra-Garcia P, Fink-Puches R, Porkert S, et al. Evaluation of Low-Dose, Low-Frequency Oral Psoralen-UV-A Treatment With or Without Maintenance on Early-Stage Mycosis Fungoides: A Randomized Clinical Trial. *JAMA Dermatol* 2019;155:538-547. Available at:  
<https://www.ncbi.nlm.nih.gov/pubmed/30892603>.

76. Almohideb M, Walsh S, Walsh S, et al. Bath Psoralen-ultraviolet A and Narrowband Ultraviolet B Phototherapy as Initial Therapy for Early-stage Mycosis Fungoides: A Retrospective Cohort of 267 Cases at the University of Toronto. *Clin Lymphoma Myeloma Leuk* 2017;17:604-612. Available at: <https://www.ncbi.nlm.nih.gov/pubmed/28711574>.

77. Nikolaou V, Sachlas A, Papadavid E, et al. Phototherapy as a first-line treatment for early-stage mycosis fungoides: The results of a large retrospective analysis. *Photodermatol Photoimmunol Photomed* 2018;34:307-313. Available at:  
<https://www.ncbi.nlm.nih.gov/pubmed/29533478>.

78. Phan K, Ramachandran V, Fassihi H, Sebaratnam DF. Comparison of Narrowband UV-B With Psoralen-UV-A Phototherapy for Patients With Early-Stage Mycosis Fungoides: A Systematic Review and Meta-analysis. *JAMA Dermatol* 2019;155:335-341. Available at:  
<https://www.ncbi.nlm.nih.gov/pubmed/30698622>.

79. Ahmad K, Rogers S, McNicholas PD, Collins P. Narrowband UVB and PUVA in the treatment of mycosis fungoides: a retrospective study. *Acta Derm Venereol* 2007;87:413-417. Available at:  
<https://www.ncbi.nlm.nih.gov/pubmed/17721648>.

80. Ponte P, Serrao V, Apetato M. Efficacy of narrowband UVB vs. PUVA in patients with early-stage mycosis fungoides. *J Eur Acad Dermatol*

*Venereol* 2010;24:716-721. Available at:  
<https://www.ncbi.nlm.nih.gov/pubmed/19929938>.

81. Diederer PV, van Weelden H, Sanders CJ, et al. Narrowband UVB and psoralen-UVA in the treatment of early-stage mycosis fungoides: a retrospective study. *J Am Acad Dermatol* 2003;48:215-219. Available at:  
<https://www.ncbi.nlm.nih.gov/pubmed/12582391>.

82. Olsen EA, Hodak E, Anderson T, et al. Guidelines for phototherapy of mycosis fungoides and Sezary syndrome: A consensus statement of the United States Cutaneous Lymphoma Consortium. *J Am Acad Dermatol* 2016;74:27-58. Available at:  
<https://www.ncbi.nlm.nih.gov/pubmed/26547257>.

83. Prince HM, Kim YH, Horwitz SM, et al. Brentuximab vedotin or physician's choice in CD30-positive cutaneous T-cell lymphoma (ALCANZA): an international, open-label, randomised, phase 3, multicentre trial. *Lancet* 2017;390:555-566. Available at:  
<https://www.ncbi.nlm.nih.gov/pubmed/28600132>.

84. Kim YH, Bagot M, Pinter-Brown L, et al. Mogamulizumab versus vorinostat in previously treated cutaneous T-cell lymphoma (MAVORIC): an international, open-label, randomised, controlled phase 3 trial. *Lancet Oncol* 2018;19:1192-1204. Available at:  
<https://www.ncbi.nlm.nih.gov/pubmed/30100375>.

85. Duvic M, Martin AG, Kim Y, et al. Phase 2 and 3 clinical trial of oral bexarotene (Targretin capsules) for the treatment of refractory or persistent early-stage cutaneous T-cell lymphoma. *Arch Dermatol* 2001;137:581-593. Available at:  
<https://www.ncbi.nlm.nih.gov/pubmed/11346336>.

86. Duvic M, Hymes K, Heald P, et al. Bexarotene is effective and safe for treatment of refractory advanced-stage cutaneous T-cell lymphoma: multinational phase II-III trial results. *J Clin Oncol* 2001;19:2456-2471. Available at: <https://www.ncbi.nlm.nih.gov/pubmed/11331325>.

87. Duvic M, Talpur R, Ni X, et al. Phase 2 trial of oral vorinostat (suberoylanilide hydroxamic acid, SAHA) for refractory cutaneous T-cell



# NCCN Guidelines Version 2.2021

## Primary Cutaneous Lymphomas

lymphoma (CTCL). Blood 2007;109:31-39. Available at: <https://www.ncbi.nlm.nih.gov/pubmed/16960145>.

88. Olsen EA, Kim YH, Kuzel TM, et al. Phase IIb multicenter trial of vorinostat in patients with persistent, progressive, or treatment refractory cutaneous T-cell lymphoma. J Clin Oncol 2007;25:3109-3115. Available at: <https://www.ncbi.nlm.nih.gov/pubmed/17577020>.

89. Duvic M, Olsen EA, Breneman D, et al. Evaluation of the long-term tolerability and clinical benefit of vorinostat in patients with advanced cutaneous T-cell lymphoma. Clin Lymphoma Myeloma 2009;9:412-416. Available at: <https://www.ncbi.nlm.nih.gov/pubmed/19951879>.

90. Piekarz RL, Frye R, Turner M, et al. Phase II multi-institutional trial of the histone deacetylase inhibitor romidepsin as monotherapy for patients with cutaneous T-cell lymphoma. J Clin Oncol 2009;27:5410-5417. Available at: <http://www.ncbi.nlm.nih.gov/pubmed/19826128>.

91. Whittaker SJ, Demierre MF, Kim EJ, et al. Final results from a multicenter, international, pivotal study of romidepsin in refractory cutaneous T-cell lymphoma. J Clin Oncol 2010;28:4485-4491. Available at: <https://www.ncbi.nlm.nih.gov/pubmed/20697094>.

92. Kim EJ, Kim YH, Rook AH, et al. Clinically significant responses achieved with romidepsin across disease compartments in patients with cutaneous T-cell lymphoma. Leuk Lymphoma 2015;56:2847-2854. Available at: <https://www.ncbi.nlm.nih.gov/pubmed/25791237>.

93. Horwitz SM, Kim YH, Foss F, et al. Identification of an active, well-tolerated dose of pralatrexate in patients with relapsed or refractory cutaneous T-cell lymphoma. Blood 2012;119:4115-4122. Available at: <https://www.ncbi.nlm.nih.gov/pubmed/22394596>.

94. Foss F, Horwitz SM, Coiffier B, et al. Pralatrexate is an effective treatment for relapsed or refractory transformed mycosis fungoides: a subgroup efficacy analysis from the PROPEL study. Clin Lymphoma Myeloma Leuk 2012;12:238-243. Available at: <https://www.ncbi.nlm.nih.gov/pubmed/22542448>.

95. Talpur R, Thompson A, Gangar P, Duvic M. Pralatrexate alone or in combination with bexarotene: long-term tolerability in relapsed/refractory mycosis fungoides. Clin Lymphoma Myeloma Leuk 2014;14:297-304. Available at: <https://www.ncbi.nlm.nih.gov/pubmed/24589156>.

96. Kennedy GA, Seymour JF, Wolf M, et al. Treatment of patients with advanced mycosis fungoides and Sezary syndrome with alemtuzumab. Eur J Haematol 2003;71:250-256. Available at: <https://www.ncbi.nlm.nih.gov/pubmed/12950233>.

97. Lundin J, Hagberg H, Repp R, et al. Phase 2 study of alemtuzumab (anti-CD52 monoclonal antibody) in patients with advanced mycosis fungoides/Sezary syndrome. Blood 2003;101:4267-4272. Available at: <https://www.ncbi.nlm.nih.gov/pubmed/12543862>.

98. Bernengo MG, Quaglino P, Comessatti A, et al. Low-dose intermittent alemtuzumab in the treatment of Sezary syndrome: clinical and immunologic findings in 14 patients. Haematologica 2007;92:784-794. Available at: <https://www.ncbi.nlm.nih.gov/pubmed/17550851>.

99. Alinari L, Geskin L, Grady T, et al. Subcutaneous alemtuzumab for Sezary Syndrome in the very elderly. Leuk Res 2008;32:1299-1303. Available at: <http://www.ncbi.nlm.nih.gov/pubmed/18096224>.

100. Querfeld C, Mehta N, Rosen ST, et al. Alemtuzumab for relapsed and refractory erythrodermic cutaneous T-cell lymphoma: a single institution experience from the Robert H. Lurie Comprehensive Cancer Center. Leuk Lymphoma 2009;50:1969-1976. Available at: <https://www.ncbi.nlm.nih.gov/pubmed/19860617>.

101. de Masson A, Guitera P, Brice P, et al. Long-term efficacy and safety of alemtuzumab in advanced primary cutaneous T-cell lymphomas. Br J Dermatol 2014;170:720-724. Available at: <https://www.ncbi.nlm.nih.gov/pubmed/24438061>.

102. Khodadoust MS, Rook AH, Porcu P, et al. Pembrolizumab in Relapsed and Refractory Mycosis Fungoides and Sezary Syndrome: A Multicenter Phase II Study. J Clin Oncol 2020;38:20-28. Available at: <https://www.ncbi.nlm.nih.gov/pubmed/31532724>.



# NCCN Guidelines Version 2.2021

## Primary Cutaneous Lymphomas

103. Olsen EA. Interferon in the treatment of cutaneous T-cell lymphoma. *Dermatol Ther* 2003;16:311-321. Available at: <https://www.ncbi.nlm.nih.gov/pubmed/14686974>.

104. Kaplan EH, Rosen ST, Norris DB, et al. Phase II study of recombinant human interferon gamma for treatment of cutaneous T-cell lymphoma. *J Natl Cancer Inst* 1990;82:208-212. Available at: <https://www.ncbi.nlm.nih.gov/pubmed/2104937>.

105. Zackheim HS, Kashani-Sabet M, McMillan A. Low-dose methotrexate to treat mycosis fungoides: a retrospective study in 69 patients. *J Am Acad Dermatol* 2003;49:873-878. Available at: <https://www.ncbi.nlm.nih.gov/pubmed/14576667>.

106. McGirt LY, Thoburn C, Hess A, Vonderheid EC. Predictors of response to extracorporeal photopheresis in advanced mycosis fungoides and Sezary syndrome. *Photodermatol Photoimmunol Photomed* 2010;26:182-191. Available at: <https://www.ncbi.nlm.nih.gov/pubmed/20626820>.

107. Quaglino P, Knobler R, Fierro MT, et al. Extracorporeal photopheresis for the treatment of erythrodermic cutaneous T-cell lymphoma: a single center clinical experience with long-term follow-up data and a brief overview of the literature. *Int J Dermatol* 2013;52:1308-1318. Available at: <https://www.ncbi.nlm.nih.gov/pubmed/23786842>.

108. Knobler R, Arenberger P, Arun A, et al. European dermatology forum - updated guidelines on the use of extracorporeal photopheresis 2020 - part 1. *J Eur Acad Dermatol Venereol* 2020;34:2693-2716. Available at: <https://www.ncbi.nlm.nih.gov/pubmed/33025659>.

109. Zinzani PL, Baliva G, Magagnoli M, et al. Gemcitabine treatment in pretreated cutaneous T-cell lymphoma: experience in 44 patients. *J Clin Oncol* 2000;18:2603-2606. Available at: <https://www.ncbi.nlm.nih.gov/pubmed/10893292>.

110. Duvic M, Talpur R, Wen S, et al. Phase II evaluation of gemcitabine monotherapy for cutaneous T-cell lymphoma. *Clin Lymphoma Myeloma*

2006;7:51-58. Available at: <https://www.ncbi.nlm.nih.gov/pubmed/16879770>.

111. Jidar K, Ingen-Housz-Oro S, Beylot-Barry M, et al. Gemcitabine treatment in cutaneous T-cell lymphoma: a multicentre study of 23 cases. *Br J Dermatol* 2009;161:660-663. Available at: <https://www.ncbi.nlm.nih.gov/pubmed/19438862>.

112. Pellegrini C, Stefoni V, Casadei B, et al. Long-term outcome of patients with advanced-stage cutaneous T cell lymphoma treated with gemcitabine. *Ann Hematol* 2014;93:1853-1857. Available at: <https://www.ncbi.nlm.nih.gov/pubmed/24908331>.

113. Pulini S, Rupoli S, Goteri G, et al. Pegylated liposomal doxorubicin in the treatment of primary cutaneous T-cell lymphomas. *Haematologica* 2007;92:686-689. Available at: <https://www.ncbi.nlm.nih.gov/pubmed/17488695>.

114. Quereux G, Marques S, Nguyen JM, et al. Prospective multicenter study of pegylated liposomal doxorubicin treatment in patients with advanced or refractory mycosis fungoides or Sezary syndrome. *Arch Dermatol* 2008;144:727-733. Available at: <https://www.ncbi.nlm.nih.gov/pubmed/18559761>.

115. Dummer R, Quaglino P, Becker JC, et al. Prospective international multicenter phase II trial of intravenous pegylated liposomal doxorubicin monochemotherapy in patients with stage IIB, IVA, or IVB advanced mycosis fungoides: final results from EORTC 21012. *J Clin Oncol* 2012;30:4091-4097. Available at: <https://www.ncbi.nlm.nih.gov/pubmed/23045580>.

116. Hughes CF, Khot A, McCormack C, et al. Lack of durable disease control with chemotherapy for mycosis fungoides and Sezary syndrome: a comparative study of systemic therapy. *Blood* 2015;125:71-81. Available at: <https://www.ncbi.nlm.nih.gov/pubmed/25336628>.

117. Quaglino P, Maule M, Prince HM, et al. Global patterns of care in advanced stage mycosis fungoides/Sezary syndrome: a multicenter retrospective follow-up study from the Cutaneous Lymphoma International





# NCCN Guidelines Version 2.2021

## Primary Cutaneous Lymphomas

Consortium. Ann Oncol 2017;28:2517-2525. Available at:  
<https://www.ncbi.nlm.nih.gov/pubmed/28961843>.

118. Duvic M, Tetzlaff MT, Gangar P, et al. Results of a Phase II Trial of Brentuximab Vedotin for CD30+ Cutaneous T-Cell Lymphoma and Lymphomatoid Papulosis. J Clin Oncol 2015;33:3759-3765. Available at:  
<https://www.ncbi.nlm.nih.gov/pubmed/26261247>.

119. Kim YH, Tavallaee M, Sundram U, et al. Phase II Investigator-Initiated Study of Brentuximab Vedotin in Mycosis Fungoides and Sezary Syndrome With Variable CD30 Expression Level: A Multi-Institution Collaborative Project. J Clin Oncol 2015;33:3750-3758. Available at: <https://www.ncbi.nlm.nih.gov/pubmed/26195720>.

120. Dummer R, Prince HM, Whittaker S, et al. Patient-reported quality of life in patients with relapsed/refractory cutaneous T-cell lymphoma: Results from the randomised phase III ALCANZA study. Eur J Cancer 2020;133:120-130. Available at:  
<https://www.ncbi.nlm.nih.gov/pubmed/32502876>.

121. Querfeld C, Rosen ST, Guitart J, et al. Comparison of selective retinoic acid receptor- and retinoic X receptor-mediated efficacy, tolerance, and survival in cutaneous t-cell lymphoma. J Am Acad Dermatol 2004;51:25-32. Available at:  
<https://www.ncbi.nlm.nih.gov/pubmed/15243520>.

122. Cheeley J, Sahn RE, DeLong LK, Parker SR. Acitretin for the treatment of cutaneous T-cell lymphoma. J Am Acad Dermatol 2013;68:247-254. Available at:  
<https://www.ncbi.nlm.nih.gov/pubmed/22917895>.

123. Amitay-Laish I, Reiter O, Prag-Naveh H, et al. Retinoic acid receptor agonist as monotherapy for early-stage mycosis fungoides: does it work? J Dermatolog Treat 2019;30:258-263. Available at:  
<https://www.ncbi.nlm.nih.gov/pubmed/29889596>.

124. Nikolaou V, Patsatsi A, Sidiropoulou P, et al. Monotherapy and combination therapy with acitretin for mycosis fungoides: results of a retrospective, multicentre study. J Eur Acad Dermatol Venereol

2020;34:2534-2540. Available at:  
<https://www.ncbi.nlm.nih.gov/pubmed/32364303>.

125. Deschamps O, Ram-Wolff C, Beylot-Barry M, et al. Treatment of mycosis fungoides and Sezary syndrome with romidepsin: a series of 32 cases from the French Study Group for Cutaneous Lymphoma. Br J Dermatol 2019;180:423-424. Available at:  
<https://www.ncbi.nlm.nih.gov/pubmed/30298903>.

126. Porcu P, Hudgens S, Horwitz S, et al. Quality of Life Effect of the Anti-CCR4 Monoclonal Antibody Mogamulizumab Versus Vorinostat in Patients With Cutaneous T-cell Lymphoma. Clin Lymphoma Myeloma Leuk 2021;21:97-105. Available at:  
<https://www.ncbi.nlm.nih.gov/pubmed/33158772>.

127. Marchi E, Alinari L, Tani M, et al. Gemcitabine as frontline treatment for cutaneous T-cell lymphoma: phase II study of 32 patients. Cancer 2005;104:2437-2441. Available at:  
<https://www.ncbi.nlm.nih.gov/pubmed/16216001>.

128. Bisaccia E, Gonzalez J, Palangio M, et al. Extracorporeal photochemotherapy alone or with adjuvant therapy in the treatment of cutaneous T-cell lymphoma: a 9-year retrospective study at a single institution. J Am Acad Dermatol 2000;43:263-271. Available at:  
<https://www.ncbi.nlm.nih.gov/pubmed/10906649>.

129. Zic JA. The treatment of cutaneous T-cell lymphoma with photopheresis. Dermatol Ther 2003;16:337-346. Available at:  
<https://www.ncbi.nlm.nih.gov/pubmed/14686977>.

130. Arulogun S, Prince HM, Gambell P, et al. Extracorporeal photopheresis for the treatment of Sezary syndrome using a novel treatment protocol. J Am Acad Dermatol 2008;59:589-595. Available at:  
<https://www.ncbi.nlm.nih.gov/pubmed/18656282>.

131. Talpur R, Demierre MF, Geskin L, et al. Multicenter photopheresis intervention trial in early-stage mycosis fungoides. Clin Lymphoma Myeloma Leuk 2011;11:219-227. Available at:  
<https://www.ncbi.nlm.nih.gov/pubmed/21575927>.





# NCCN Guidelines Version 2.2021

## Primary Cutaneous Lymphomas

132. Knobler R, Duvic M, Querfeld C, et al. Long-term follow-up and survival of cutaneous T-cell lymphoma patients treated with extracorporeal photopheresis. *Photodermatol Photoimmunol Photomed* 2012;28:250-257. Available at: <https://www.ncbi.nlm.nih.gov/pubmed/22971190>.

133. Knobler R, Berlin G, Calzavara-Pinton P, et al. Guidelines on the use of extracorporeal photopheresis. *J Eur Acad Dermatol Venereol* 2014;28 Suppl 1:1-37. Available at: <https://www.ncbi.nlm.nih.gov/pubmed/24354653>.

134. Atilla E, Atilla PA, Bozdogan SC, et al. Extracorporeal photochemotherapy in mycosis fungoides. *Transfus Clin Biol* 2017;24:454-457. Available at: <https://www.ncbi.nlm.nih.gov/pubmed/28578935>.

135. Gao C, McCormack C, van der Weyden C, et al. Prolonged survival with the early use of a novel extracorporeal photopheresis regimen in patients with Sezary syndrome. *Blood* 2019;134:1346-1350. Available at: <https://www.ncbi.nlm.nih.gov/pubmed/31467061>.

136. Stevens SR, Baron ED, Masten S, Cooper KD. Circulating CD4+CD7- lymphocyte burden and rapidity of response: predictors of outcome in the treatment of Sezary syndrome and erythrodermic mycosis fungoides with extracorporeal photopheresis. *Arch Dermatol* 2002;138:1347-1350. Available at: <https://www.ncbi.nlm.nih.gov/pubmed/12374541>.

137. Stadler R, Otte HG, Luger T, et al. Prospective randomized multicenter clinical trial on the use of interferon -2a plus acitretin versus interferon -2a plus PUVA in patients with cutaneous T-cell lymphoma stages I and II. *Blood* 1998;92:3578-3581. Available at: <http://www.ncbi.nlm.nih.gov/pubmed/9808550>.

138. Chiarion-Sileni V, Bononi A, Fornasa CV, et al. Phase II trial of interferon-alpha-2a plus psoralen with ultraviolet light A in patients with cutaneous T-cell lymphoma. *Cancer* 2002;95:569-575. Available at: <https://www.ncbi.nlm.nih.gov/pubmed/12209749>.

139. Rupoli S, Goteri G, Pulini S, et al. Long-term experience with low-dose interferon-alpha and PUVA in the management of early mycosis fungoides. *Eur J Haematol* 2005;75:136-145. Available at: <https://www.ncbi.nlm.nih.gov/pubmed/16000130>.

140. Olisova OY, Megna M, Grekova EV, et al. PUVA and interferon alpha2b combined therapy for patients with mycosis fungoides at different stages of the disease: a seven-year retrospective study in Russia. *J Eur Acad Dermatol Venereol* 2019;33:e72-e74. Available at: <https://www.ncbi.nlm.nih.gov/pubmed/30102807>.

141. Whittaker S, Ortiz P, Dummer R, et al. Efficacy and safety of bexarotene combined with psoralen-ultraviolet A (PUVA) compared with PUVA treatment alone in stage IB-IIA mycosis fungoides: final results from the EORTC Cutaneous Lymphoma Task Force phase III randomized clinical trial (NCT00056056). *Br J Dermatol* 2012;167:678-687. Available at: <https://www.ncbi.nlm.nih.gov/pubmed/22924950>.

142. Rupoli S, Canafoglia L, Goteri G, et al. Results of a prospective phase II trial with oral low-dose bexarotene plus photochemotherapy (PUVA) in refractory and/or relapsed patients with mycosis fungoides. *Eur J Dermatol* 2016;26:13-20. Available at: <https://www.ncbi.nlm.nih.gov/pubmed/26678311>.

143. Fujimura T, Sato Y, Tanita K, et al. Case series of cutaneous T-cell lymphomas treated with bexarotene-based therapy. *J Dermatol* 2020;47:636-640. Available at: <https://www.ncbi.nlm.nih.gov/pubmed/32207181>.

144. Morita A, Tateishi C, Muramatsu S, et al. Efficacy and safety of bexarotene combined with photo(chemo)therapy for cutaneous T-cell lymphoma. *J Dermatol* 2020;47:443-451. Available at: <https://www.ncbi.nlm.nih.gov/pubmed/32189402>.

145. Wilson LD, Jones GW, Kim D, et al. Experience with total skin electron beam therapy in combination with extracorporeal photopheresis in the management of patients with erythrodermic (T4) mycosis fungoides. *J Am Acad Dermatol* 2000;43:54-60. Available at: <https://www.ncbi.nlm.nih.gov/pubmed/10863224>.



# NCCN Guidelines Version 2.2021

## Primary Cutaneous Lymphomas

146. Atzmony L, Amitay-Laish I, Gurion R, et al. Erythrodermic mycosis fungoides and Sezary syndrome treated with extracorporeal photopheresis as part of a multimodality regimen: A single-centre experience. *J Eur Acad Dermatol Venereol* 2015;29:2382-2389. Available at: <https://www.ncbi.nlm.nih.gov/pubmed/26299651>.

147. Wollina U, Looks A, Meyer J, et al. Treatment of stage II cutaneous T-cell lymphoma with interferon alfa-2a and extracorporeal photochemotherapy: a prospective controlled trial. *J Am Acad Dermatol* 2001;44:253-260. Available at: <https://www.ncbi.nlm.nih.gov/pubmed/11174383>.

148. Suchin KR, Cucchiara AJ, Gottlieb SL, et al. Treatment of cutaneous T-cell lymphoma with combined immunomodulatory therapy: a 14-year experience at a single institution. *Arch Dermatol* 2002;138:1054-1060. Available at: <https://www.ncbi.nlm.nih.gov/pubmed/12164743>.

149. Raphael BA, Shin DB, Suchin KR, et al. High clinical response rate of Sezary syndrome to immunomodulatory therapies: prognostic markers of response. *Arch Dermatol* 2011;147:1410-1415. Available at: <https://www.ncbi.nlm.nih.gov/pubmed/21844430>.

150. Siakantaris MP, Tsirigotis P, Stavroyianni N, et al. Management of cutaneous T-Cell lymphoma patients with extracorporeal photopheresis. The Hellenic experience. *Transfus Apher Sci* 2012;46:189-193. Available at: <https://www.ncbi.nlm.nih.gov/pubmed/22178592>.

151. Duvic M, Apisarnthanarax N, Cohen DS, et al. Analysis of long-term outcomes of combined modality therapy for cutaneous T-cell lymphoma. *J Am Acad Dermatol* 2003;49:35-49. Available at: <https://www.ncbi.nlm.nih.gov/pubmed/12833006>.

152. Straus DJ, Duvic M, Kuzel T, et al. Results of a phase II trial of oral bexarotene (Targretin) combined with interferon alfa-2b (Intron-A) for patients with cutaneous T-cell lymphoma. *Cancer* 2007;109:1799-1803. Available at: <https://www.ncbi.nlm.nih.gov/pubmed/17366595>.

153. Straus DJ, Duvic M, Horwitz SM, et al. Final results of phase II trial of doxorubicin HCl liposome injection followed by bexarotene in advanced

cutaneous T-cell lymphoma. *Ann Oncol* 2014;25:206-210. Available at: <https://www.ncbi.nlm.nih.gov/pubmed/24285015>.

154. Olsen EA, Whittaker S, Kim YH, et al. Clinical end points and response criteria in mycosis fungoides and Sezary syndrome: a consensus statement of the International Society for Cutaneous Lymphomas, the United States Cutaneous Lymphoma Consortium, and the Cutaneous Lymphoma Task Force of the European Organisation for Research and Treatment of Cancer. *J Clin Oncol* 2011;29:2598-2607. Available at: <https://www.ncbi.nlm.nih.gov/pubmed/21576639>.

155. van Doorn R, Scheffer E, Willemze R. Follicular mycosis fungoides, a distinct disease entity with or without associated follicular mucinosis: a clinicopathologic and follow-up study of 51 patients. *Arch Dermatol* 2002;138:191-198. Available at: <https://www.ncbi.nlm.nih.gov/pubmed/11843638>.

156. Gerami P, Rosen S, Kuzel T, et al. Folliculotropic mycosis fungoides: an aggressive variant of cutaneous T-cell lymphoma. *Arch Dermatol* 2008;144:738-746. Available at: <https://www.ncbi.nlm.nih.gov/pubmed/18559762>.

157. Lehman JS, Cook-Norris RH, Weed BR, et al. Folliculotropic mycosis fungoides: single-center study and systematic review. *Arch Dermatol* 2010;146:607-613. Available at: <https://www.ncbi.nlm.nih.gov/pubmed/20566923>.

158. Wieser I, Wang C, Alberti-Violetti S, et al. Clinical characteristics, risk factors and long-term outcome of 114 patients with folliculotropic mycosis fungoides. *Arch Dermatol Res* 2017;309:453-459. Available at: <https://www.ncbi.nlm.nih.gov/pubmed/28516243>.

159. Hodak E, Amitay-Laish I, Atzmony L, et al. New insights into folliculotropic mycosis fungoides (FMF): A single-center experience. *J Am Acad Dermatol* 2016;75:347-355. Available at: <https://www.ncbi.nlm.nih.gov/pubmed/27245278>.

160. van Santen S, Roach RE, van Doorn R, et al. Clinical Staging and Prognostic Factors in Folliculotropic Mycosis Fungoides. *JAMA Dermatol*



# NCCN Guidelines Version 2.2021

## Primary Cutaneous Lymphomas

2016;152:992-1000. Available at:

<https://www.ncbi.nlm.nih.gov/pubmed/27276223>.

161. Charli-Joseph Y, Kashani-Sabet M, McCalmont TH, et al. Association of a Proposed New Staging System for Folliculotropic Mycosis Fungoides With Prognostic Variables in a US Cohort. *JAMA Dermatol* 2021;157:157-165. Available at:

<https://www.ncbi.nlm.nih.gov/pubmed/33295938>.

162. van Santen S, van Doorn R, Neelis KJ, et al. Recommendations for treatment in folliculotropic mycosis fungoides: report of the Dutch Cutaneous Lymphoma Group. *Br J Dermatol* 2017;177:223-228. Available at: <https://www.ncbi.nlm.nih.gov/pubmed/28132406>.

163. Lansigan F, Horwitz SM, Pinter-Brown LC, et al. Outcomes of Patients with Transformed Mycosis Fungoides: Analysis from a Prospective Multicenter US Cohort Study. *Clin Lymphoma Myeloma Leuk* 2020;20:744-748. Available at:

<https://www.ncbi.nlm.nih.gov/pubmed/32532611>.

164. de Masson A, Beylot-Barry M, Bouaziz JD, et al. Allogeneic stem cell transplantation for advanced cutaneous T-cell lymphomas: a study from the French Society of Bone Marrow Transplantation and French Study Group on Cutaneous Lymphomas. *Haematologica* 2014;99:527-534. Available at: <https://www.ncbi.nlm.nih.gov/pubmed/24213148>.

165. Duarte RF, Boumendil A, Onida F, et al. Long-term outcome of allogeneic hematopoietic cell transplantation for patients with mycosis fungoides and Sezary syndrome: a European society for blood and marrow transplantation lymphoma working party extended analysis. *J Clin Oncol* 2014;32:3347-3348. Available at:

<https://www.ncbi.nlm.nih.gov/pubmed/25154828>.

166. Lechowicz MJ, Lazarus HM, Carreras J, et al. Allogeneic hematopoietic cell transplantation for mycosis fungoides and Sezary syndrome. *Bone Marrow Transplant* 2014;49:1360-1365. Available at:

<https://www.ncbi.nlm.nih.gov/pubmed/25068422>.

167. Hosing C, Bassett R, Dabaja B, et al. Allogeneic stem-cell transplantation in patients with cutaneous lymphoma: updated results from a single institution. *Ann Oncol* 2015;26:2490-2495. Available at:

<https://www.ncbi.nlm.nih.gov/pubmed/26416896>.

168. Shiratori S, Fujimoto K, Nishimura M, et al. Allogeneic hematopoietic stem cell transplantation following reduced-intensity conditioning for mycosis fungoides and Sezary syndrome. *Hematol Oncol* 2016;34:9-16. Available at: <https://www.ncbi.nlm.nih.gov/pubmed/25312300>.

169. Johnson WT, Mukherji R, Kartan S, et al. Allogeneic hematopoietic stem cell transplantation in advanced stage mycosis fungoides and Sezary syndrome: a concise review. *Chin Clin Oncol* 2019;8:12. Available at:

<https://www.ncbi.nlm.nih.gov/pubmed/30525754>.

170. Iqbal M, Reljic T, Ayala E, et al. Efficacy of Allogeneic Hematopoietic Cell Transplantation in Cutaneous T Cell Lymphoma: Results of a Systematic Review and Meta-Analysis. *Biol Blood Marrow Transplant* 2020;26:76-82. Available at:

<https://www.ncbi.nlm.nih.gov/pubmed/31494227>.

171. Duarte RF, Schmitz N, Servitje O, Sureda A. Haematopoietic stem cell transplantation for patients with primary cutaneous T-cell lymphoma. *Bone Marrow Transplant* 2008;41:597-604. Available at:

<https://www.ncbi.nlm.nih.gov/pubmed/18176611>.

172. Duvic M, Donato M, Dabaja B, et al. Total skin electron beam and non-meloablative allogeneic hematopoietic stem-cell transplantation in advanced mycosis fungoides and Sezary syndrome. *J Clin Oncol* 2010;28:2365-2372. Available at:

<https://www.ncbi.nlm.nih.gov/pubmed/20351328>.

173. Weng WK, Arai S, Rezvani A, et al. Nonmyeloablative allogeneic transplantation achieves clinical and molecular remission in cutaneous T-cell lymphoma. *Blood Adv* 2020;4:4474-4482. Available at:

<https://www.ncbi.nlm.nih.gov/pubmed/32941647>.

174. Isufi I, Seropian S, Gowda L, et al. Outcomes for allogeneic stem cell transplantation in refractory mycosis fungoides and primary cutaneous



# NCCN Guidelines Version 2.2021

## Primary Cutaneous Lymphomas

gamma Delta T cell lymphomas. *Leuk Lymphoma* 2020;61:2955-2961. Available at: <https://www.ncbi.nlm.nih.gov/pubmed/32643494>.

175. Thompson LL, Pan CX, Chang MS, et al. Alemtuzumab, total skin electron beam, and non-myeloablative allogeneic haematopoietic stem-cell transplantation in advanced Sezary syndrome: a retrospective cohort study. *J Eur Acad Dermatol Venereol* 2021. Available at: <https://www.ncbi.nlm.nih.gov/pubmed/33545747>.

176. Mori T, Shiratori S, Suzumiya J, et al. Outcome of allogeneic hematopoietic stem cell transplantation for mycosis fungoides and Sezary syndrome. *Hematol Oncol* 2020;38:266-271. Available at: <https://www.ncbi.nlm.nih.gov/pubmed/32011008>.

177. Demierre MF, Gan S, Jones J, Miller DR. Significant impact of cutaneous T-cell lymphoma on patients' quality of life: results of a 2005 National Cutaneous Lymphoma Foundation Survey. *Cancer* 2006;107:2504-2511. Available at: <https://www.ncbi.nlm.nih.gov/pubmed/17048251>.

178. Sampogna F, Frontani M, Baliva G, et al. Quality of life and psychological distress in patients with cutaneous lymphoma. *Br J Dermatol* 2009;160:815-822. Available at: <https://www.ncbi.nlm.nih.gov/pubmed/19120325>.

179. Meyer N, Paul C, Misery L. Pruritus in cutaneous T-cell lymphomas: frequent, often severe and difficult to treat. *Acta Derm Venereol* 2010;90:12-17. Available at: <https://www.ncbi.nlm.nih.gov/pubmed/20107719>.

180. Trautinger F, Knobler R, Willemze R, et al. EORTC consensus recommendations for the treatment of mycosis fungoides/Sezary syndrome. *Eur J Cancer* 2006;42:1014-1030. Available at: <https://www.ncbi.nlm.nih.gov/pubmed/16574401>.

181. Eschler DC, Klein PA. An evidence-based review of the efficacy of topical antihistamines in the relief of pruritus. *J Drugs Dermatol* 2010;9:992-997. Available at: <https://www.ncbi.nlm.nih.gov/pubmed/20684150>.

182. Matsuda KM, Sharma D, Schonfeld AR, Kwatra SG. Gabapentin and pregabalin for the treatment of chronic pruritus. *J Am Acad Dermatol* 2016;75:619-625 e616. Available at: <https://www.ncbi.nlm.nih.gov/pubmed/27206757>.

183. Duval A, Dubertret L. Aprepitant as an antipruritic agent? *N Engl J Med* 2009;361:1415-1416. Available at: <https://www.ncbi.nlm.nih.gov/pubmed/19797294>.

184. Booken N, Heck M, Nicolay JP, et al. Oral aprepitant in the therapy of refractory pruritus in erythrodermic cutaneous T-cell lymphoma. *Br J Dermatol* 2011;164:665-667. Available at: <https://www.ncbi.nlm.nih.gov/pubmed/21039410>.

185. Jimenez Gallo D, Albarran Planelles C, Linares Barrios M, et al. Treatment of pruritus in early-stage hypopigmented mycosis fungoides with aprepitant. *Dermatol Ther* 2014;27:178-182. Available at: <https://www.ncbi.nlm.nih.gov/pubmed/24517320>.

186. Demierre MF, Taverna J. Mirtazapine and gabapentin for reducing pruritus in cutaneous T-cell lymphoma. *J Am Acad Dermatol* 2006;55:543-544. Available at: <https://www.ncbi.nlm.nih.gov/pubmed/16908377>.

187. Stander S, Bockenholt B, Schurmeyer-Horst F, et al. Treatment of chronic pruritus with the selective serotonin re-uptake inhibitors paroxetine and fluvoxamine: results of an open-labelled, two-arm proof-of-concept study. *Acta Derm Venereol* 2009;89:45-51. Available at: <https://www.ncbi.nlm.nih.gov/pubmed/19197541>.

188. Bigliardi PL, Stammer H, Jost G, et al. Treatment of pruritus with topically applied opiate receptor antagonist. *J Am Acad Dermatol* 2007;56:979-988. Available at: <https://www.ncbi.nlm.nih.gov/pubmed/17320241>.

189. Axelrod PI, Lorber B, Vonderheid EC. Infections complicating mycosis fungoides and Sezary syndrome. *JAMA* 1992;267:1354-1358. Available at: <https://www.ncbi.nlm.nih.gov/pubmed/1740857>.





# NCCN Guidelines Version 2.2021

## Primary Cutaneous Lymphomas

### Primary Cutaneous CD30+ T-Cell Lymphoproliferative Disorders

Primary cutaneous CD30+ T-cell lymphoproliferative disorders (PCTLD) represent a spectrum that includes primary cutaneous anaplastic large-cell lymphoma (PC-ALCL), lymphomatoid papulosis (LyP), and “borderline” cases with overlapping clinical and histopathologic features.<sup>1,2</sup> Primary cutaneous disease, spontaneous regression, and absence of extracutaneous spread are associated with a better prognosis.<sup>3,4</sup>

PC-ALCL represents about 8% of all CTCL and is histologically characterized by diffuse, cohesive sheets of large CD30-positive (in >75%) cells with anaplastic, pleomorphic, or immunoblastic appearance.<sup>5</sup> Patches and plaques may also be present, and some degree of spontaneous remittance in lesions may also be seen. PC-ALCL typically follows an indolent course with an excellent prognosis, although cutaneous relapses are more common.<sup>6-8</sup> Clinical features typically include solitary or localized nodules or tumors (often ulcerated); multifocal lesions occur in about 20% of cases. Extracutaneous disease occurs in about 10% of cases, usually involving regional lymph nodes.<sup>7</sup> The presence of multiple cutaneous lesions at presentation, extensive skin lesions on the leg, disease progression to extracutaneous disease, early cutaneous relapse, and nodal progression are associated with poorer outcomes.<sup>9-11</sup>

LyP is histologically heterogenous with large atypical anaplastic, immunoblastic, or Hodgkin-like cells in a marked inflammatory background.<sup>2</sup> Several histologic subtypes have been defined based on the evolution of skin lesions. Clinical features include chronic, recurrent, spontaneously regressing papulonodular (grouped or generalized) skin lesions. LyP is not considered a malignant disorder and has an excellent prognosis with an OS rate of 92% at 5 and 10 years.<sup>8</sup> However, LyP has also been reported to be associated with an increased risk of secondary

lymphomas such as MF, PC-ALCL, systemic ALCL, or Hodgkin lymphoma.<sup>12-17</sup> Older age, positive *TCR* gene rearrangement, or diagnosis of mixed-type LyP have been reported as prognostic indicators of disease progression to lymphoma.<sup>13,15</sup>

### Literature Search Criteria and Guidelines Update Methodology

Prior to the update of this version of the NCCN Guidelines for Primary Cutaneous Lymphomas, an electronic search of the PubMed database was performed to obtain key literature in PCTLD published since the previous Guidelines update using the following search terms: primary cutaneous anaplastic large cell lymphoma and LyP. The PubMed database was chosen as it remains the most widely used resource for medical literature and indexes peer-reviewed biomedical literature.<sup>18</sup>

The search results were narrowed by selecting studies in humans published in English. Results were confined to the following article types: Clinical Trial, Phase II; Clinical Trial, Phase III; Clinical Trial, Phase IV; Guideline; Randomized Controlled Trial; Meta-Analysis; Systematic Reviews; and Validation Studies.

The data from key PubMed articles deemed as relevant to these guidelines have been included in this version of the Discussion section. Recommendations for which high-level evidence is lacking are based on the panel's review of lower-level evidence and expert opinion.

The complete details of the Development and Update of the NCCN Guidelines are available at [www.NCCN.org](http://www.NCCN.org).

### Diagnosis

As described earlier, PCTLD is a spectrum of clinical presentation including LyP (mostly papular and always regressing), PC-ALCL (mostly nodular and persistent), and also “borderline” presentations where lesions regress but take longer or are larger and not papular as in LyP.<sup>5</sup> Clinical





# NCCN Guidelines Version 2.2021

## Primary Cutaneous Lymphomas

and pathologic correlation is essential for distinguishing within the spectrum of PCTLD as well as distinguishing PCTLD from other cutaneous CD30+ disorders (ie, systemic ALCL, adult T-cell leukemia/lymphoma [ATLL], PTCL, mycosis fungoides (MF; especially transformed MF) and benign disorders such as lymphomatoid drug reactions, arthropod bites, viral infections, and others. MF and PCTLD can coexist in the same patient. Lymphomatoid drug reactions have been linked with certain drugs (eg, amlodipine, carbamazepine, cefuroxime) and may be associated with CD30+ atypical large cells in histology. Classical Hodgkin lymphoma (CHL) is less often associated with MF and PCTLD than previously thought; however, coexpression of CD30 and CD15 in these T-cell lymphomas may lead to a mistaken diagnosis of CHL.<sup>19</sup> It is therefore important not to diagnose CD30+ T-cell lymphomas in lymph nodes as Hodgkin lymphoma.

Complete skin examination (for evidence of MF), adequate biopsy (punch, incisional, or excisional) of suspicious skin lesions, and immunohistochemistry (IHC) of skin biopsy specimen are essential to confirm the diagnosis. Molecular analysis to detect clonal *TCR* gene rearrangements, excisional or incisional biopsy of suspicious lymph nodes, and assessment of HTLV-1 serology to identify CD30+ ATLL would be helpful in selected circumstances. However, *TCR* gene rearrangement may not be demonstrated in all cases of PCTLD and *TCR* rearrangements can also be seen in patients with non-malignant conditions. Demonstration of identical clones in skin, blood, and/or lymph nodes may be helpful in selected cases.<sup>20</sup> Identification of clonal *TCR* gene rearrangement has no definitive established prognostic value; however, it could be helpful to determine clinical staging or assess relapsed or residual disease.

PCTLD are characterized by the following immunophenotype: CD30+ (>75% cells), CD4+, variable loss of CD2/CD5/CD3, and CD8+ (<5%) cytotoxic granule-associated proteins positive. IHC panel should include

CD3, CD4, CD8, CD20, CD30, CD56, and anaplastic lymphoma kinase (ALK). ALK-positive PC-ALCL is extremely uncommon and t(2;5) translocation is typically absent in CD30+ PCTLD.<sup>21,22</sup> ALK positivity and differential expression of t(2;5) can help to distinguish between CD30+ PCTLD and ALCL of nodal origin.

Additional markers such as CD2, CD5, CD7, CD25, TIA1, granzyme B, perforin, GM1, Epstein-Barr encoding region in situ hybridization (EBER-ISH), IRF4/MUM1, and epithelial membrane antigen (EMA) may be useful in selected circumstances. Abnormal T-cell phenotype and perforin expression are significantly more frequent in PC-ALCL than in transformed MF and may be useful for the differential diagnosis between PC-ALCL and CD30-expressing transformed MF.<sup>23</sup>

MUM1 expression is valuable for the distinction between LyP and PC-ALCL, since the majority of cases of LyP (87%) are positive for MUM1 staining compared to only 20% of cases with PC-ALCL.<sup>24</sup> *DUSP22-IRF4* (6p25.3) gene rearrangement has been described in patients with PC-ALCL and LyP but is not associated with prognostic significance.<sup>25-27</sup> In a large multicenter study that investigated the clinical utility of detecting *IRF4* translocations in skin biopsies of T-cell lymphoproliferative disorders, fluorescence in situ hybridization (FISH) for *IRF4* had a specificity and positive predictive value of 99% and 90%, respectively, for cutaneous ALCL.<sup>25</sup> FISH to detect *ALK* and *DUSP22-IRF4* rearrangements would be useful in selected circumstances. HTLV 1 status, assessed either by HTLV 1 serology or other methods, may be useful in at risk populations to exclude the diagnosis of CD30-positive ATLL (which is usually HTLV-1 positive).

### Workup

The initial workup involves a history and complete physical exam including entire skin, palpation of peripheral lymph node regions, and liver or spleen.



# NCCN Guidelines Version 2.2021

## Primary Cutaneous Lymphomas

Laboratory studies should include CBC with differential, a comprehensive metabolic panel, and assessment of LDH levels. Many skin-directed and systemic therapies are contraindicated or are of unknown safety in pregnancy. Therefore, pregnancy testing is recommended for women of childbearing age.

Biopsy of enlarged lymph nodes or extracutaneous sites is recommended if biopsy of skin is non-diagnostic. FNA alone is not sufficient for the initial diagnosis. Excisional or incisional biopsy is preferred over core needle biopsy. In certain circumstances, when a lymph node is not easily accessible for excisional or incisional biopsy, a combination of core needle biopsy and FNA in conjunction with appropriate ancillary techniques may be sufficient for diagnosis. Bone marrow evaluation has limited value in the staging of patients with PC-ALCL and is not required for disease staging.<sup>28</sup> Bone marrow aspiration and biopsy may be considered only for solitary PC-ALCL or PC-ALCL without extracutaneous involvement on imaging.

Contrast-enhanced CT scan of the chest, abdomen, and pelvis or integrated whole body PET/CT is recommended for PC-ALCL. PET scan may be preferred for patients with extranodal disease, which is inadequately imaged by CT. In LyP, imaging studies and bone marrow evaluation are done only if there is suspicion of systemic involvement by an associated lymphoma.

### Primary Cutaneous ALCL

#### **Radiation Therapy**

Involved-site RT (ISRT) alone or surgical excision (with or without ISRT) are recommended for patients with solitary or grouped lesions.<sup>6-8,29-32</sup>

In a report from the Dutch Cutaneous Lymphoma Group that evaluated the long-term outcome of 219 patients with PCTLD (118 patients with LyP, 79 patients with PC-ALCL, and 11 patients with PC-ALCL with regional node

involvement), RT or surgical excision as initial therapy (given for 48% and 19% of patients, respectively) resulted in a CR rate of 100% in patients with PC-ALCL.<sup>7</sup> After a median follow-up of 61 months, subsequent skin-only relapse and extracutaneous disease were reported in 41% and 10% of patients, respectively.

A multicenter retrospective analysis restricted to patients with PC-ALCL (n = 56) eligible to receive RT (primary therapy or after surgical excision) reported a clinical complete response (cCR) rate of 95% and a local control rate of 98% after a median follow-up of 4 years.<sup>33</sup> Although the median RT dose was 35 Gy (range, 6–45 Gy), CRs were seen with doses as low as 6 Gy and the achievement of cCR was independent of the RT dose, suggesting that lower RT dose of <30 Gy may be appropriate for the management of localized lesions. The efficacy of low-dose RT (≤20 Gy) for the treatment of solitary or localized PC-ALCL was also confirmed in other recent reports.<sup>34-36</sup>

#### **Systemic Therapy**

Systemic therapy is indicated only for multifocal lesions (± skin-directed therapy) and for those with regional node involvement (± ISRT). Observation (if asymptomatic) is appropriate for patients with multifocal lesions, and ISRT alone is an appropriate option in selected patients with regional lymph node involvement ± primary skin lesions.

Brentuximab vedotin is the preferred systemic treatment option based on the results of the ALCANZA study.<sup>37</sup> In this study that included 31 patients with previously treated PC-ALCL, overall response rate (ORR) lasting for 4 months or more was significantly higher for brentuximab vedotin compared to the physician's choice of treatment with methotrexate or bexarotene (75% vs. 20%), and the proportion of patients achieving CR was also higher with brentuximab vedotin than with physician's choice (31% vs. 7%).<sup>37</sup>



# NCCN Guidelines Version 2.2021

## Primary Cutaneous Lymphomas

In a multicenter study that evaluated the efficacy of treatment options in patients with multifocal lesions included in the Dutch Registry for Cutaneous Lymphomas prior to the FDA approval of brentuximab vedotin (24 patients with initial presentation and 17 patients with relapsed disease), RT (n = 21), systemic chemotherapy (n = 9), and low-dose methotrexate (n = 7) were the most common treatment options resulting in ORRs of 100% (100% CR), 100% (78% CR), and 57% (43% CR), respectively.<sup>38</sup> The presence of greater than 5 skin lesions was associated with a higher risk of extracutaneous relapse (56% vs. 20% for the presence of 2–5 skin lesions). Low-dose methotrexate (50 mg weekly),<sup>39,40</sup> pralatrexate,<sup>41</sup> systemic retinoids (bexarotene for multifocal lesions),<sup>42-45</sup> and IFN (multifocal lesions)<sup>42,46-48</sup> are included as options for other recommended regimens based on the limited available data.

Multiagent chemotherapy (CHOP [cyclophosphamide, doxorubicin, vincristine and prednisone] or CHOEP [cyclophosphamide, doxorubicin, vincristine, etoposide and prednisone]) with or without ISRT has also been studied in patients with PC-ALCL and is included as an option for selected patients with regional lymph node involvement.<sup>7,49</sup> In the aforementioned report from the Dutch Cutaneous Lymphoma Group that evaluated the long-term outcome of 219 patients with PCTLD, 9 of 11 patients (82%) with PC-ALCL and regional node involvement received CHOP-like multiagent chemotherapy as initial therapy (82%), resulting in a CR in 8 patients (88%).<sup>7</sup> However, five out of these eight patients experienced skin relapses during follow-up. After a median follow-up of 58 months, disease-related 5-year survival rate was 91%.

In November 2018, the FDA approved brentuximab vedotin in combination with cyclophosphamide, doxorubicin, and prednisone (CHP) for the treatment of previously untreated systemic ALCL or other CD30-positive PTCL based on the results of the ECHELON-2 trial, which showed that brentuximab vedotin + CHP was superior to CHOP for patients with

CD30-positive PTCL as shown by a significant improvement in PFS and OS.<sup>50</sup> This trial, however, excluded patients with PC-ALCL. However, since CHOP is included as an option for primary treatment (other recommended regimens) for cutaneous ALCL with regional nodes, the panel acknowledged that brentuximab vedotin + CHP would also be an appropriate option for these patients. Brentuximab vedotin + CHP is included as an option under other recommended regimens for the primary treatment for patients with cutaneous ALCL with regional nodes.

### Lymphomatoid Papulosis

When managing patients with LyP, it is important to be reminded that this is not a malignant disorder but a recurrent, benign, self-regressing lymphoid proliferation.

Observation is preferred for patients with asymptomatic disease. Topical steroids and phototherapy are included as options for initial treatment of limited lesions as well as extensive lesions.<sup>7,43,51-53</sup> In the aforementioned report from the Dutch Cutaneous Lymphoma Group that included 118 patients with LyP, topical steroids and phototherapy were the most common skin-directed therapies used as initial treatment in 56% and 35% of patients, respectively.<sup>7</sup> Although CR or PR were common, none of these therapies resulted in sustained CR. In a retrospective multicenter study of 252 patients with LyP, topical steroids and phototherapy were the most common first-line treatments (prescribed in 35% and 14% of the patients, respectively) resulting in a CR rate of 48%.<sup>54</sup> The overall estimated median DFS was 11 months, but the DFS was longer for patients treated with phototherapy (23 months;  $P < .03$ ). The presence of type A LyP and the use of first-line treatment other than phototherapy were significantly associated with increased risk of early cutaneous relapse.

Systemic therapy is indicated only for patients with extensive lesions. Methotrexate is widely used for the treatment of LyP.<sup>39,54-61</sup> In a



# NCCN Guidelines Version 2.2021

## Primary Cutaneous Lymphomas

retrospective study of 45 patients with LyP and other CD30+ PCTLD, low-dose methotrexate ( $\leq 25$  mg) resulted in satisfactory disease control in 87% of patients, and the median total duration of treatment was greater than 39 months for all patients.<sup>57</sup> After discontinuation, 25% of patients remained free of disease relapse during the follow-up period of 24 to 227 months. Another study that evaluated the efficacy of low-dose methotrexate in a cohort of 28 patients with LyP reported that satisfactory disease control could be achieved at 7.5-mg to 10-mg weekly doses of methotrexate.<sup>39</sup> Systemic retinoids (bexarotene) are included as an option based on limited available data mainly from case reports.<sup>42-45</sup>

Although multiagent chemotherapy often leads to reduction or clearance of lesions, rapid recurrence shortly after or even during treatment is a consistent finding in patients with LyP.

### Follow-Up and Treatment for Relapsed/Refractory Disease

Patients with a clinical benefit and/or those with disease responding to initial treatment can be considered for maintenance or tapering of regimens to optimize response duration. Patients with disease that does not have adequate response to initial treatment are generally treated with an alternative regimen recommended for initial treatment before moving on to treatment for refractory disease. Disease relapse often responds well to the same treatment. In patients with PC-ALCL, refractory disease to multiple prior therapies should be managed with systemic therapy options recommended for LCT of MF.

Brentuximab vedotin is included as an option for LyP that is refractory to multiple primary treatment options.<sup>62,63</sup> In a phase II study of 12 patients with refractory LyP, brentuximab vedotin resulted in an ORR of 100% and a CR rate of 58%.<sup>63</sup> The median duration of response was 20 weeks. Grade 1 or 2 peripheral neuropathy was the most common adverse event

reported in 10 patients (83%). Further studies are needed to optimize the dosing to minimize the incidences of peripheral neuropathy.

Regular follow-up (including complete skin exam) is essential during observation since these patients can develop associated hematologic malignancies (particularly MF or ALCL) over time.<sup>54,64</sup> Life-long follow-up (including thorough skin exam) is warranted for patients with LyP (even for patients responding to initial treatment) due to high risks for second lymphoid malignancies.





# NCCN Guidelines Version 2.2021

## Primary Cutaneous Lymphomas

### References

1. Kim YH, Willemze R, Pimpinelli N, et al. TNM classification system for primary cutaneous lymphomas other than mycosis fungoides and Sezary syndrome: a proposal of the International Society for Cutaneous Lymphomas (ISCL) and the Cutaneous Lymphoma Task Force of the European Organization of Research and Treatment of Cancer (EORTC). *Blood* 2007;110:479-484. Available at: <https://www.ncbi.nlm.nih.gov/pubmed/17339420>.
2. Kempf W, Pfaltz K, Vermeer MH, et al. EORTC, ISCL, and USCLC consensus recommendations for the treatment of primary cutaneous CD30-positive lymphoproliferative disorders: lymphomatoid papulosis and primary cutaneous anaplastic large-cell lymphoma. *Blood* 2011;118:4024-4035. Available at: <https://www.ncbi.nlm.nih.gov/pubmed/21841159>.
3. Paulli M, Berti E, Rosso R, et al. CD30/Ki-1-positive lymphoproliferative disorders of the skin--clinicopathologic correlation and statistical analysis of 86 cases: a multicentric study from the European Organization for Research and Treatment of Cancer Cutaneous Lymphoma Project Group. *J Clin Oncol* 1995;13:1343-1354. Available at: <https://www.ncbi.nlm.nih.gov/pubmed/7751878>.
4. Vergier B, Beylot-Barry M, Pulford K, et al. Statistical evaluation of diagnostic and prognostic features of CD30+ cutaneous lymphoproliferative disorders: a clinicopathologic study of 65 cases. *Am J Surg Pathol* 1998;22:1192-1202. Available at: <https://www.ncbi.nlm.nih.gov/pubmed/9777981>.
5. Willemze R, Cerroni L, Kempf W, et al. The 2018 update of the WHO-EORTC classification for primary cutaneous lymphomas. *Blood* 2019;133:1703-1714. Available at: <https://www.ncbi.nlm.nih.gov/pubmed/30635287>.
6. Beljaards RC, Kaudewitz P, Berti E, et al. Primary cutaneous CD30-positive large cell lymphoma: definition of a new type of cutaneous lymphoma with a favorable prognosis. A European Multicenter Study of 47 patients. *Cancer* 1993;71:2097-2104. Available at: <https://www.ncbi.nlm.nih.gov/pubmed/8382999>.
7. Bekkenk MW, Geelen FA, van Voorst Vader PC, et al. Primary and secondary cutaneous CD30(+) lymphoproliferative disorders: a report from the Dutch Cutaneous Lymphoma Group on the long-term follow-up data of 219 patients and guidelines for diagnosis and treatment. *Blood* 2000;95:3653-3661. Available at: <https://www.ncbi.nlm.nih.gov/pubmed/10845893>.
8. Liu HL, Hoppe RT, Kohler S, et al. CD30+ cutaneous lymphoproliferative disorders: the Stanford experience in lymphomatoid papulosis and primary cutaneous anaplastic large cell lymphoma. *J Am Acad Dermatol* 2003;49:1049-1058. Available at: <https://www.ncbi.nlm.nih.gov/pubmed/14639383>.
9. Woo DK, Jones CR, Vanoli-Storz MN, et al. Prognostic factors in primary cutaneous anaplastic large cell lymphoma: characterization of clinical subset with worse outcome. *Arch Dermatol* 2009;145:667-674. Available at: <https://www.ncbi.nlm.nih.gov/pubmed/19528422>.
10. Benner MF, Willemze R. Applicability and prognostic value of the new TNM classification system in 135 patients with primary cutaneous anaplastic large cell lymphoma. *Arch Dermatol* 2009;145:1399-1404. Available at: <https://www.ncbi.nlm.nih.gov/pubmed/20026848>.
11. Fernandez-de-Misa R, Hernandez-Machin B, Combalia A, et al. Prognostic factors in patients with primary cutaneous anaplastic large cell lymphoma: a multicentric, retrospective analysis of the Spanish Group of Cutaneous Lymphoma. *J Eur Acad Dermatol Venereol* 2020;34:762-768. Available at: <https://www.ncbi.nlm.nih.gov/pubmed/31591786>.
12. Wang HH, Myers T, Lach LJ, et al. Increased risk of lymphoid and nonlymphoid malignancies in patients with lymphomatoid papulosis. *Cancer* 1999;86:1240-1245. Available at: <https://www.ncbi.nlm.nih.gov/pubmed/10506709>.
13. de Souza A, el-Azhary RA, Camilleri MJ, et al. In search of prognostic indicators for lymphomatoid papulosis: a retrospective study of 123





# NCCN Guidelines Version 2.2021

## Primary Cutaneous Lymphomas

patients. J Am Acad Dermatol 2012;66:928-937. Available at: <https://www.ncbi.nlm.nih.gov/pubmed/21982062>.

14. Nikolaou V, Papadavid E, Ekonomidi A, et al. Association of clinicopathological characteristics with secondary neoplastic lymphoproliferative disorders in patients with lymphomatoid papulosis. Leuk Lymphoma 2015;56:1303-1307. Available at: <https://www.ncbi.nlm.nih.gov/pubmed/25242096>.

15. Cordel N, Tressieres B, D'Incan M, et al. Frequency and Risk Factors for Associated Lymphomas in Patients With Lymphomatoid Papulosis. Oncologist 2016;21:76-83. Available at: <https://www.ncbi.nlm.nih.gov/pubmed/26668250>.

16. Wieser I, Oh CW, Talpur R, Duvic M. Lymphomatoid papulosis: Treatment response and associated lymphomas in a study of 180 patients. J Am Acad Dermatol 2016;74:59-67. Available at: <https://www.ncbi.nlm.nih.gov/pubmed/26518172>.

17. AbuHilal M, Walsh S, Shear N. Associated Hematolymphoid Malignancies in Patients With Lymphomatoid Papulosis: A Canadian Retrospective Study. J Cutan Med Surg 2017;21:507-512. Available at: <https://www.ncbi.nlm.nih.gov/pubmed/28614957>.

18. U.S. National Library of Medicine Key MEDLINE® Indicators Available at: [http://www.nlm.nih.gov/bsd/bsd\\_key.html](http://www.nlm.nih.gov/bsd/bsd_key.html).

19. Eberle FC, Song JY, Xi L, et al. Nodal involvement by cutaneous CD30-positive T-cell lymphoma mimicking classical Hodgkin lymphoma. Am J Surg Pathol 2012;36:716-725. Available at: <https://www.ncbi.nlm.nih.gov/pubmed/22367293>.

20. Thurber SE, Zhang B, Kim YH, et al. T-cell clonality analysis in biopsy specimens from two different skin sites shows high specificity in the diagnosis of patients with suggested mycosis fungoides. J Am Acad Dermatol 2007;57:782-790. Available at: <https://www.ncbi.nlm.nih.gov/pubmed/17646032>.

21. DeCoteau JF, Butmarc JR, Kinney MC, Kadin ME. The t(2;5) chromosomal translocation is not a common feature of primary cutaneous CD30+ lymphoproliferative disorders: comparison with anaplastic large-cell lymphoma of nodal origin. Blood 1996;87:3437-3441. Available at: <https://www.ncbi.nlm.nih.gov/pubmed/8605362>.

22. Melchers RC, Willemze R, van de Loo M, et al. Clinical, Histologic, and Molecular Characteristics of Anaplastic Lymphoma Kinase-positive Primary Cutaneous Anaplastic Large Cell Lymphoma. Am J Surg Pathol 2020;44:776-781. Available at: <https://www.ncbi.nlm.nih.gov/pubmed/32412717>.

23. Fauconneau A, Pham-Ledard A, Cappellen D, et al. Assessment of diagnostic criteria between primary cutaneous anaplastic large-cell lymphoma and CD30-rich transformed mycosis fungoides; a study of 66 cases. Br J Dermatol 2015;172:1547-1554. Available at: <https://www.ncbi.nlm.nih.gov/pubmed/25645336>.

24. Kempf W, Kutzner H, Cozzio A, et al. MUM1 expression in cutaneous CD30+ lymphoproliferative disorders: a valuable tool for the distinction between lymphomatoid papulosis and primary cutaneous anaplastic large-cell lymphoma. Br J Dermatol 2008;158:1280-1287. Available at: <https://www.ncbi.nlm.nih.gov/pubmed/18410414>.

25. Wada DA, Law ME, Hsi ED, et al. Specificity of IRF4 translocations for primary cutaneous anaplastic large cell lymphoma: a multicenter study of 204 skin biopsies. Mod Pathol 2011;24:596-605. Available at: <https://www.ncbi.nlm.nih.gov/pubmed/21169992>.

26. Karai LJ, Kadin ME, Hsi ED, et al. Chromosomal rearrangements of 6p25.3 define a new subtype of lymphomatoid papulosis. Am J Surg Pathol 2013;37:1173-1181. Available at: <https://www.ncbi.nlm.nih.gov/pubmed/23648461>.

27. Onaindia A, Montes-Moreno S, Rodriguez-Pinilla SM, et al. Primary cutaneous anaplastic large cell lymphomas with 6p25.3 rearrangement exhibit particular histological features. Histopathology 2015;66:846-855. Available at: <https://www.ncbi.nlm.nih.gov/pubmed/25131361>.



# NCCN Guidelines Version 2.2021

## Primary Cutaneous Lymphomas

28. Benner MF, Willemze R. Bone marrow examination has limited value in the staging of patients with an anaplastic large cell lymphoma first presenting in the skin. Retrospective analysis of 107 patients. *Br J Dermatol* 2008;159:1148-1151. Available at: <https://www.ncbi.nlm.nih.gov/pubmed/18782320>.

29. Yu JB, McNiff JM, Lund MW, Wilson LD. Treatment of primary cutaneous CD30+ anaplastic large-cell lymphoma with radiation therapy. *Int J Radiat Oncol Biol Phys* 2008;70:1542-1545. Available at: <https://www.ncbi.nlm.nih.gov/pubmed/18037577>.

30. Booken N, Goerdts S, Klemke CD. Clinical spectrum of primary cutaneous CD30-positive anaplastic large cell lymphoma: an analysis of the Mannheim Cutaneous Lymphoma Registry. *J Dtsch Dermatol Ges* 2012;10:331-339. Available at: <https://www.ncbi.nlm.nih.gov/pubmed/22525148>.

31. Huang BS, Chen WY, Wang CW, et al. Relapse Pattern and Treatment Outcome of Curative Radiotherapy for Primary Cutaneous CD30+ Anaplastic Large-cell Lymphoma: A Retrospective Cohort Study. *Acta Derm Venereol* 2016;96:394-395. Available at: <https://www.ncbi.nlm.nih.gov/pubmed/26463467>.

32. Hapgood G, Pickles T, Sehn LH, et al. Outcome of primary cutaneous anaplastic large cell lymphoma: a 20-year British Columbia Cancer Agency experience. *Br J Haematol* 2017;176:234-240. Available at: <https://www.ncbi.nlm.nih.gov/pubmed/27766622>.

33. Million L, Yi EJ, Wu F, et al. Radiation Therapy for Primary Cutaneous Anaplastic Large Cell Lymphoma: An International Lymphoma Radiation Oncology Group Multi-institutional Experience. *Int J Radiat Oncol Biol Phys* 2016;95:1454-1459. Available at: <https://www.ncbi.nlm.nih.gov/pubmed/27315663>.

34. Melchers RC, Willemze R, Daniels LA, et al. Recommendations for the Optimal Radiation Dose in Patients With Primary Cutaneous Anaplastic Large Cell Lymphoma: A Report of the Dutch Cutaneous Lymphoma Group. *Int J Radiat Oncol Biol Phys* 2017;99:1279-1285. Available at: <https://www.ncbi.nlm.nih.gov/pubmed/28958772>.

35. Smith GL, Duvic M, Yehia ZA, et al. Effectiveness of low-dose radiation for primary cutaneous anaplastic large cell lymphoma. *Adv Radiat Oncol* 2017;2:363-369. Available at: <https://www.ncbi.nlm.nih.gov/pubmed/29114604>.

36. Piccinno R, Damiani G, Rossi LC, Berti E. Radiotherapy of primary cutaneous anaplastic large cell lymphoma: our experience in 30 cases. *Int J Dermatol* 2020;59:469-473. Available at: <https://www.ncbi.nlm.nih.gov/pubmed/31916593>.

37. Prince HM, Kim YH, Horwitz SM, et al. Brentuximab vedotin or physician's choice in CD30-positive cutaneous T-cell lymphoma (ALCANZA): an international, open-label, randomised, phase 3, multicentre trial. *Lancet* 2017;390:555-566. Available at: <https://www.ncbi.nlm.nih.gov/pubmed/28600132>.

38. Melchers RC, Willemze R, Bekkenk MW, et al. Evaluation of treatment results in multifocal primary cutaneous anaplastic large cell lymphoma: report of the Dutch Cutaneous Lymphoma Group. *Br J Dermatol* 2018;179:724-731. Available at: <https://www.ncbi.nlm.nih.gov/pubmed/29494757>.

39. Bruijn MS, Horvath B, van Voorst Vader PC, et al. Recommendations for treatment of lymphomatoid papulosis with methotrexate: a report from the Dutch Cutaneous Lymphoma Group. *Br J Dermatol* 2015;173:1319-1322. Available at: <https://www.ncbi.nlm.nih.gov/pubmed/25998985>.

40. Park JB, Yang MH, Kwon DI, et al. Low-dose Methotrexate Treatment for Solitary or Localized Primary Cutaneous Anaplastic Large Cell Lymphoma: A Long-term Follow-up Study. *Acta Derm Venereol* 2020;100:adv00069. Available at: <https://www.ncbi.nlm.nih.gov/pubmed/31996929>.

41. Horwitz SM, Kim YH, Foss F, et al. Identification of an active, well-tolerated dose of pralatrexate in patients with relapsed or refractory cutaneous T-cell lymphoma. *Blood* 2012;119:4115-4122. Available at: <https://www.ncbi.nlm.nih.gov/pubmed/22394596>.



# NCCN Guidelines Version 2.2021

## Primary Cutaneous Lymphomas

42. Wyss M, Dummer R, Dommann SN, et al. Lymphomatoid papulosis--treatment with recombinant interferon alfa-2a and etretinate. *Dermatology* 1995;190:288-291. Available at: <https://www.ncbi.nlm.nih.gov/pubmed/7655107>.

43. Krathen RA, Ward S, Duvic M. Bexarotene is a new treatment option for lymphomatoid papulosis. *Dermatology* 2003;206:142-147. Available at: <https://www.ncbi.nlm.nih.gov/pubmed/12592082>.

44. Sheehy O, Catherwood M, Pettengell R, Morris TC. Sustained response of primary cutaneous CD30 positive anaplastic large cell lymphoma to bexarotene and photopheresis. *Leuk Lymphoma* 2009;50:1389-1391. Available at: <https://www.ncbi.nlm.nih.gov/pubmed/19544141>.

45. Fujimura T, Furudate S, Tanita K, et al. Successful control of phototherapy-resistant lymphomatoid papulosis with oral bexarotene. *J Dermatol* 2018;45:e37-e38. Available at: <https://www.ncbi.nlm.nih.gov/pubmed/28971510>.

46. Proctor SJ, Jackson GH, Lennard AL, Marks J. Lymphomatoid papulosis: response to treatment with recombinant interferon alfa-2b. *J Clin Oncol* 1992;10:170. Available at: <https://www.ncbi.nlm.nih.gov/pubmed/1727920>.

47. Yagi H, Tokura Y, Furukawa F, Takigawa M. Th2 cytokine mRNA expression in primary cutaneous CD30-positive lymphoproliferative disorders: successful treatment with recombinant interferon-gamma. *J Invest Dermatol* 1996;107:827-832. Available at: <https://www.ncbi.nlm.nih.gov/pubmed/8941669>.

48. Schmuth M, Topar G, Illersperger B, et al. Therapeutic use of interferon-alpha for lymphomatoid papulosis. *Cancer* 2000;89:1603-1610. Available at: <https://www.ncbi.nlm.nih.gov/pubmed/11013377>.

49. Brice P, Cazals D, Mounier N, et al. Primary cutaneous large-cell lymphoma: analysis of 49 patients included in the LNH87 prospective trial of polychemotherapy for high-grade lymphomas. *Groupe d'Etude des*

*Lymphomes de l'Adulte*. *Leukemia* 1998;12:213-219. Available at: <https://www.ncbi.nlm.nih.gov/pubmed/9519784>.

50. Horwitz S, O'Connor OA, Pro B, et al. Brentuximab vedotin with chemotherapy for CD30-positive peripheral T-cell lymphoma (ECHELON-2): a global, double-blind, randomised, phase 3 trial. *Lancet* 2019;393:229-240. Available at: <https://www.ncbi.nlm.nih.gov/pubmed/30522922>.

51. Zackheim HS, Epstein EH, Jr., Crain WR. Topical carmustine therapy for lymphomatoid papulosis. *Arch Dermatol* 1985;121:1410-1414. Available at: <https://www.ncbi.nlm.nih.gov/pubmed/4051529>.

52. Thomsen K, Wantzin GL. Lymphomatoid papulosis. A follow-up study of 30 patients. *J Am Acad Dermatol* 1987;17:632-636. Available at: <https://www.ncbi.nlm.nih.gov/pubmed/2889756>.

53. Calzavara-Pinton P, Venturini M, Sala R. Medium-dose UVA1 therapy of lymphomatoid papulosis. *J Am Acad Dermatol* 2005;52:530-532. Available at: <https://www.ncbi.nlm.nih.gov/pubmed/15761440>.

54. Fernandez-de-Misa R, Hernandez-Machin B, Servitje O, et al. First-line treatment in lymphomatoid papulosis: a retrospective multicentre study. *Clin Exp Dermatol* 2018;43:137-143. Available at: <https://www.ncbi.nlm.nih.gov/pubmed/28994134>.

55. Everett MA. Treatment of lymphomatoid papulosis with methotrexate. *Br J Dermatol* 1984;111:631. Available at: <https://www.ncbi.nlm.nih.gov/pubmed/6498098>.

56. Christensen HK, Thomsen K, Vejlsgaard GL. Lymphomatoid papulosis: a follow-up study of 41 patients. *Semin Dermatol* 1994;13:197-201. Available at: <https://www.ncbi.nlm.nih.gov/pubmed/7986688>.

57. Vonderheid EC, Sajjadian A, Kadin ME. Methotrexate is effective therapy for lymphomatoid papulosis and other primary cutaneous CD30-positive lymphoproliferative disorders. *J Am Acad Dermatol*



## NCCN Guidelines Version 2.2021 Primary Cutaneous Lymphomas

---

1996;34:470-481. Available at:

<https://www.ncbi.nlm.nih.gov/pubmed/8609262>.

58. Yazawa N, Kondo S, Kagaya M, et al. Successful treatment of a patient with lymphomatoid papulosis by methotrexate. J Dermatol 2001;28:373-378. Available at:

<https://www.ncbi.nlm.nih.gov/pubmed/11510505>.

59. Fujita H, Nagatani T, Miyazawa M, et al. Primary cutaneous anaplastic large cell lymphoma successfully treated with low-dose oral methotrexate. Eur J Dermatol 2008;18:360-361. Available at:

<https://www.ncbi.nlm.nih.gov/pubmed/18474486>.

60. Cornejo CM, Novoa RA, Krisch RE, Kim EJ. Low-dose radiotherapy for primary cutaneous anaplastic large-cell lymphoma while on low-dose methotrexate. Cutis 2016;98:253-256. Available at:

<https://www.ncbi.nlm.nih.gov/pubmed/27874877>.

61. Newland KM, McCormack CJ, Twigger R, et al. The efficacy of methotrexate for lymphomatoid papulosis. J Am Acad Dermatol 2015;72:1088-1090. Available at:

<https://www.ncbi.nlm.nih.gov/pubmed/25981010>.

62. Duvic M, Tetzlaff MT, Gangar P, et al. Results of a Phase II Trial of Brentuximab Vedotin for CD30+ Cutaneous T-Cell Lymphoma and Lymphomatoid Papulosis. J Clin Oncol 2015;33:3759-3765. Available at:

<https://www.ncbi.nlm.nih.gov/pubmed/26261247>.

63. Lewis DJ, Talpur R, Huen AO, et al. Brentuximab Vedotin for Patients With Refractory Lymphomatoid Papulosis: An Analysis of Phase 2 Results. JAMA Dermatol 2017;153:1302-1306. Available at:

<https://www.ncbi.nlm.nih.gov/pubmed/28980004>.

64. Melchers RC, Willemze R, Bekkenk MW, et al. Frequency and prognosis of associated malignancies in 504 patients with lymphomatoid papulosis. J Eur Acad Dermatol Venereol 2020;34:260-266. Available at:

<https://www.ncbi.nlm.nih.gov/pubmed/31715046>.